

Clear Corneal Incisions

Proper wound construction and architecture result in advantageous and safe clear corneal incisions for cataract surgery.

BY I. HOWARD FINE, MD; RICHARD S. HOFFMAN, MD;
AND MARK PACKER, MD

Debate continues over whether the incidence of endophthalmitis is on the rise and possibly associated with surgeons' increasing use of clear corneal incisions. We find that these incisions are safe when they are properly constructed and accepted prophylactic measures are used.

ENDOPHTHALMITIS

Debate

A considerable number of researchers have reported a rising incidence of infectious endophthalmitis and a relationship between this increase and temporal clear corneal cataract surgery. Supporters of this argument most frequently cite a retrospective study by Cooper et al¹ and a prospective study by Nagaki et al.²

Many other investigators, however, assert that clear corneal incisions do not elevate the risk of endophthalmitis. For example, Mollan et al³ found that clear corneal incisions were not a risk factor for endophthalmitis in 102,000 patients at 13 different surgery centers in the United Kingdom. The number of subjects in this study far exceeds that of the European Society of Cataract & Refractive Surgery study.⁴ Nor were clear corneal incisions a risk factor for endophthalmitis in all of Western Australia between 1980 and 2000, the period when the number of surgeons transitioning to clear corneal incisions was the highest.⁵ In their study of 20,000 patients (all with clear corneal incisions) at nine surgery centers in the United States, Moshirfar et al⁶ reported a 0.07% rate of endophthalmitis, which represents no increase over that quoted for periods before the introduction of clear corneal incisions.^{7,8}

Finally, in a Swedish study designed specifically to

“A variety of measures help to avert endophthalmitis after cataract surgery.”

determine whether or not clear corneal incisions are a risk factor for endophthalmitis, investigators found no statistically significant difference between clear corneal incisions and scleral tunnel or limbal incisions.⁹ Of note, the use of prophylactic intracameral cefuroxime has resulted in the lowest incidence of endophthalmitis, coincident with Swedish surgeons' increasing use of clear corneal incisions.^{10,11}

Prophylaxis

Gram-positive organisms are the major source of endophthalmitis after cataract surgery.¹² Third-generation fluoroquinolones effectively eliminated *Staphylococcus aureus*—the most common *Staphylococcus* organism in postcataract endophthalmitis—between 1998 and 1999. By the year 2001, however, 100% of *S aureus* organisms were resistant to the same antibiotics.¹³

Various measures help to avert endophthalmitis after cataract surgery. They include

- A proper preoperative antibiotic regimen
- The appropriate preparation of the surgical field, including the use of povidone-iodine
- The proper construction of the incision
- A minimally invasive surgical technique with the use of phaco power modulations



Figure 1. A clear corneal temporal incision.




Figure 2. A grooved incision.

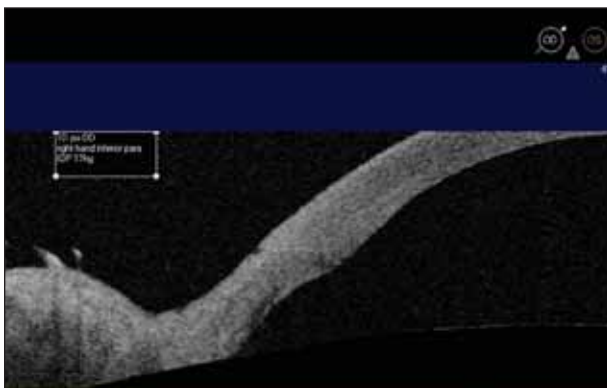


Figure 3. Routinely constructed sideport incisions.




Figure 4. An irrigating chopper paracentesis.

- The creation of incisions that are large enough to allow the introduction of instrumentation and an IOL
- A careful avoidance of grasping the roof of the incision with a toothed forceps. Such manipulation of the tissue can result in corneal epithelial erosion and a rupture of the fluid barrier that an intact epithelium allows
- A sealed incision, verified through testing with fluorescein
- The placement of a suture for a leaking incision
- The use of postoperative antibiotics

THE INCISION'S CONSTRUCTION

We have constructed our cataract incisions in the same manner since 1992. We applanate the cornea with a diamond blade where we want the external incision to be located. After advancing the blade in the plane of the cornea for 2 mm, we raise the handle so as to tip the point downward and nick Descemet's membrane. We then re-establish the original plane and drive the knife forward. This approach produces an incision that is 3 mm wide and 2 mm long. Recently, we began creating incisions that are 2.2 to 2.5 mm wide and 2 mm long. We use trapezoidal blades that allow us to manipulate instruments and phaco handpieces within the eye without stressing the incision. We also routinely per-

form stromal hydration of the main incision and all sideport incisions prior to and after testing them with fluorescein to ensure their watertight seal.

Historically, artists have depicted clear corneal incisions as flat and planar, with the roof and floor of the tunnel able to slide over each other in a relatively unstable configuration. In our studies, however, our incisions did not have this architecture. One day after surgery, optical coherence tomography (OCT) demonstrated an arcuate rather than flat incision with a much greater arc than cord length. OCT imaging also showed that stromal hydration causes the stroma surrounding the incision to swell and forces the roof of the incision down onto its floor—apposition that enhances endothelial pumping, allows for a vacuum seal, and lasts for longer than 24 hours.¹⁴ The arcuate incision's profile leads to stability not unlike tongue-and-groove paneling (Figure 1).

In contrast, when we looked at grooved incisions, we found them unsatisfactory because they gaped in the first few days postoperatively and were associated with considerable foreign body sensation. The OCT image of shallow-grooved clear corneal incisions showed that the gaping of the external lips of the incision was accompanied by a corresponding offset of its internal lips¹⁴ (Figure 2).

Surgeons usually make sideport incisions rapidly and consider them to be safe regardless of their construction. In our early analysis, however, we found that our sideport incisions were almost flat and did not have the ideal architecture¹⁵ (Figure 3). As a result, we now create these incisions with the same care and precision as our main incision (Figure 4).

CONCLUSION

The recent literature is contradictory and inconclusive regarding an increasing incidence of endophthalmitis after cataract surgery and its association with clear corneal incisions. Furthermore, we believe that the literature is incomplete, because none of the studies has described the incision's construction or architecture. Ophthalmologists cannot compare these studies and make generalizations, because not all clear corneal incisions are the same.

“In our early analysis, ... we found that our sideport incisions were almost flat and did not have the ideal architecture.”

It is important to note that the adoption of clear corneal incisions involves a transition to temporal surgery. For right-handed coaxial surgeons operating on a left eye, the sideport incision is in the inferior conjunctival cul-de-sac. We have previously reported on the role of inferior sideport incisions and their relationship to endophthalmitis.¹⁴ A recent study indicated that the incidence of postoperative endophthalmitis in left eyes following clear corneal phacoemulsification is twice the rate in right eyes.¹⁶

A 2007 white paper from the ASCRS concluded that the risks for endophthalmitis after cataract surgery should be acceptably low with the appropriate use of aseptic methods, including careful draping, hemoprophyllaxis, and particularly proper design, construction, and sealing of the clear corneal incision.¹⁷ After almost 16 years and 15,000 cataract surgery cases, we have not had a single case of endophthalmitis. We attribute this to our use of the prophylactic measures described earlier in this article and, more importantly, to the care and precision with which we construct our incisions.

Properly constructed, self-sealing, temporal clear corneal cataract incisions are safe and advantageous. That is why they are preferred by the overwhelming majority of phaco surgeons worldwide. ■

I. Howard Fine, MD, is a clinical professor of ophthalmology at Oregon Health & Science University, and he is in private practice with Drs. Fine, Hoffman & Packer, LLC, in Eugene, Oregon. Dr. Fine may be reached at (541) 687-2110; hfine@finemd.com.



Richard S. Hoffman, MD, is a clinical associate professor of ophthalmology at the Casey Eye Institute, Oregon Health & Science University, and he is in private practice at Drs. Fine, Hoffman & Packer in Eugene, Oregon. Dr. Hoffman may be reached at (541) 687-2110; rshoffman@finemd.com.



Mark Packer, MD, is a clinical associate professor at the Casey Eye Institute, Department of Ophthalmology, Oregon Health and Science University, and he is in private practice with Drs. Fine, Hoffman & Packer, LLC, in Eugene, Oregon. Dr. Packer may be reached at (541) 687-2110; mpacker@finemd.com.



1. Cooper BA, Holekamp NM, Bohigian G, Thompson PA. Case-control study of endophthalmitis after cataract surgery comparing scleral tunnel and clear corneal wounds. *Am J Ophthalmol.* 2003;136:300-305.
2. Nagaki Y, Hayasaka S, Kadoi C, et al. Bacterial endophthalmitis after small-incision cataract surgery; effect of incision placement and intraocular lens type. *J Cataract Refract Surg.* 2003;29:20-26.
3. Mollan SP, Gao A, Lockwood A, et al. Postcataract endophthalmitis: incidence and microbial isolates in a United Kingdom region from 1996 through 2004. *J Cataract Refract Surg.* 2007;33(2):265-268.
4. ESCRS Endophthalmitis Study Group. Prophylaxis of postoperative endophthalmitis following cataract surgery: results of the ESCRS multicenter study and identification of risk factors. *J Cataract Refract Surg.* 2007;33(6):978-988.
5. Ng JQ, Moriet N, Bulsara MK, Semmens JB. Reducing the risk for endophthalmitis after cataract surgery: population-based nested case-control study: endophthalmitis population study of Western Australia sixth report. *J Cataract Refract Surg.* 2007;33(2):269-280.
6. Moshirfar M, Feiz V, Vitale AT, et al. Endophthalmitis after uncomplicated cataract surgery with the use of a fourth-generation fluoroquinolones: a retrospective observational case series. *Ophthalmology.* 2007;114(4):686-691.
7. Cooper BA, Holekamp, NM, Bohigian G, Thompson PA. Case-control study of endophthalmitis after cataract surgery comparing scleral tunnel and clear corneal wounds. *Am J Ophthalmol.* 2003;136:300-305.
8. Nagaki Y, Hayasaka S, Kadoi C, et al. Bacterial endophthalmitis after small-incision cataract surgery: effect of incision placement and intraocular lens type. *J Cataract Refract Surg.* 2003;29:20-26.
9. Lundstrom M, Wejde G, Stenevi U, Thorburn W, Montan P. Endophthalmitis after cataract surgery: a nationwide prospective study evaluating incidence in relation to incision type and location. *Ophthalmology.* 2007;114(5):866-870.
10. Montan PG, Wejde G, Setterquist H, et al. Prophylactic intracameral cefuroxime. Evaluation of safety and kinetics in cataract surgery. *J Cataract Refract Surg.* 2002;28:982-987.
11. Montan PG, Wejde G, Koranyi G, Rylander M. Prophylactic intracameral cefuroxime. Efficacy in preventing endophthalmitis after cataract surgery. *J Cataract Refract Surg.* 2002;28(6):977-981.
12. Han DP, Wisniewski SR, Wilson LA, et al. Spectrum and susceptibilities of microbiologic isolates in the Endophthalmitis Vitrectomy Study. *Am J Ophthalmol.* 1996;122(1):1-17.
13. Kowalski RP, Karenchak LM, Romanowski EG. Infectious disease: changing antibiotic susceptibility. *Ophthalmol Clin North Am.* 2003;16(1):1-9.
14. Fine IH, Hoffman RS, Packer M. Profile of clear corneal cataract incisions demonstrated by ocular (optical) coherence tomography. *J Cataract Refract Surg.* 2007;33:94-97.
15. Fine IH, Hoffman RS, Packer M. Profiles of clear corneal incisions visualized by optical coherence tomography. Paper presented at: ASCRS Symposium on Cataract, IOL and Refractive Surgery; April 30, 2007; San Diego, CA.
16. Tam CS. *Ophthalmology Times.* August 15, 2008;33(16).
17. Special Report: Association Between CCI and Endophthalmitis. *Cataract Clinical Committee. American Society of Cataract and Refractive Surgery White Paper.* 2007.