

The Architecture of Clear Corneal Incisions

Studying anatomy with optical coherence tomography.

BY I. HOWARD FINE, MD; RICHARD S. HOFFMAN, MD; AND MARK PACKER, MD

The role of unsutured clear corneal incisions for cataract surgery in the apparently increased incidence of postoperative endophthalmitis is under intense scrutiny, and the literature on this subject is not conclusive.¹⁻¹⁰ Making a definitive determination requires, in part, understanding these incisions' architecture better. We therefore studied their anatomy with optical coherence tomography (OCT).

BACKGROUND

Clear corneal incisions, which involve an incision in the plane of the cornea with a length equal to 2.0 mm, were first described in 1992,¹¹ and we continue to con-

“[We] obtain[ed] the first view of the clear corneal incision in a living eye during the early postoperative period.”

struct them in essentially the same manner in our practice. In 1992, our incisions were as wide as 4.0 mm, but, more recently, the maximum width has ranged from 3.5 to 3.8 mm, if not sutured.

In an artist's view of the profile of clear corneal incisions, Figure 1A shows the single-plane incision and its apparently inherent lack of stability, as one surface can easily slide over another. Charles Williamson, MD, of Baton Rouge, Louisiana, innovated an alteration of that incision that involves a shallow, perpendicular groove prior to the incision of the cornea into the anterior chamber (Figure 1B). David Langerman, MD, of Orangeburg, New York, deepened the perpendicular groove in the belief that doing so led to greater stability (Figure 1C).

We have abandoned these grooved incisions in favor of a paracentesis-style incision due to gaping of the groove and the difficulties associated with persistent foreign body sensation and the pooling of mucus and

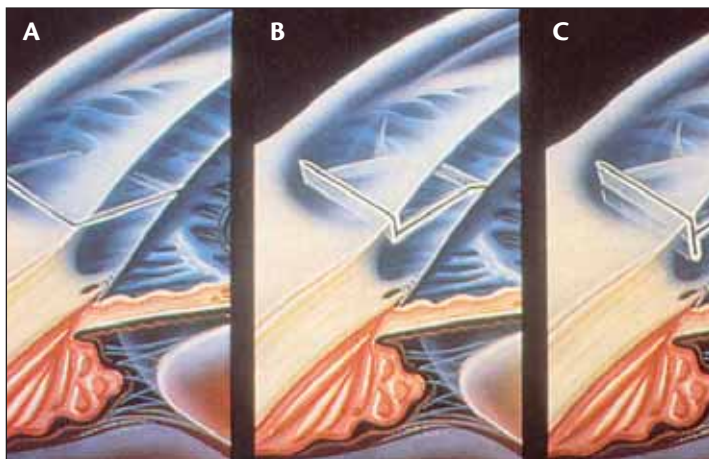


Figure 1. This drawing shows a cross-section of clear corneal incisions circa 1992 (A to C).

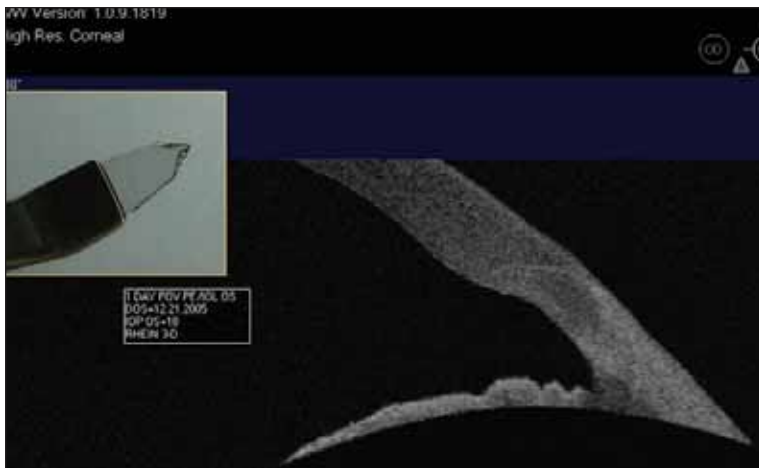

Figure 2. Seen with OCT, this 2.5-mm wide, clear corneal incision was made with the 3D Trapezoidal 2.5- to 3.5-mm Blade. An image of the blade is inset.

debris in the groove. More importantly, the grooved incisions represent a disruption in the fluid barrier created by an intact epithelium that allows for a vacuum seal as a result of endothelial pumping.

The construction of the cataract incision begins with the blade flattened against the surface of the globe with the point of the knife at the edge of the clear cornea; the blade advances for 2 mm into the cornea in the plane of the cornea before incising Descemet's membrane. Early on, incisions were made with knives that had straight sides. These blades were subsequently replaced by trapezoidal knives that allowed surgeons to enlarge the incision without violating its architecture by cutting sideways. Since 1992, we have recommended stromal hydration, which thickens the cornea, forces the incision's roof onto its floor, and facilitates endothelial pumping to the upper reaches of the cornea. We also have strongly recommended testing the seal of the incision with a Seidel test using fluorescein.¹² These practices have not changed since 1992, except for eliminating the depression of the posterior lip of the incision.

OUR STUDY: CLEAR CORNEAL INCISIONS

Methodology

The Visante OCT anterior segment imaging system (Carl Zeiss Meditec, Inc., Dublin, CA) allowed us to obtain the first view of the clear corneal incision in a living eye during the early postoperative period. The details of the corneal periphery and the anterior chamber angle, including the regularity with which the

corneal epithelium blends into the conjunctiva and the clear corneal stroma blends into the sclera, are clearly visible.

For the study, Dr. Fine created all of the clear corneal incisions. The OCT images of each operative eye were taken on the first postoperative day, within 24 to 30 hours of cataract surgery, and they are representative of multiple images from several patients. The incision's width is defined as the measurement parallel to the limbus. Its length is the distance, in a straight line, between the external incision and the entrance through Descemet's membrane. Dr. Fine used several types of knives to create the clear corneal incisions: the 3D Trapezoidal Blade (Rhein Medical Inc., Tampa, FL); the Simplicity and Black Metal

Blades (Accutome, Inc., Malvern, PA); the Clear Cornea Fixed Angle Blade (ASICO, Westmont, IL); the Superstealth Blade (Mastel Precision, Inc., Rapid City, SD); the Kojo Slit and Atomic Edge Metal Blades (BD Ophthalmic Systems, Franklin Lakes, NJ); and the 2.2-mm Metal Blade (Alcon Laboratories, Inc., Fort Worth, TX).

Actual Shape of the Incision

Figure 2, which was taken on the first postoperative day, shows that clear corneal incisions constructed in the way we described are curvilinear, not a straight line as shown in Figure 1. The arcuate incisions have an arc that is considerably longer than the chord length originally estimated for the length of the incision. It is important to note that the architecture of the incision allows for a fit not unlike tongue-and-groove paneling,




Figure 3. Viewed with OCT, this clear corneal incision has a 300-µm groove at its external edge. Gaping of both the external and internal lips of the incision is evident. An image of the 3D blade (Rhein Medical Inc.) is inset.

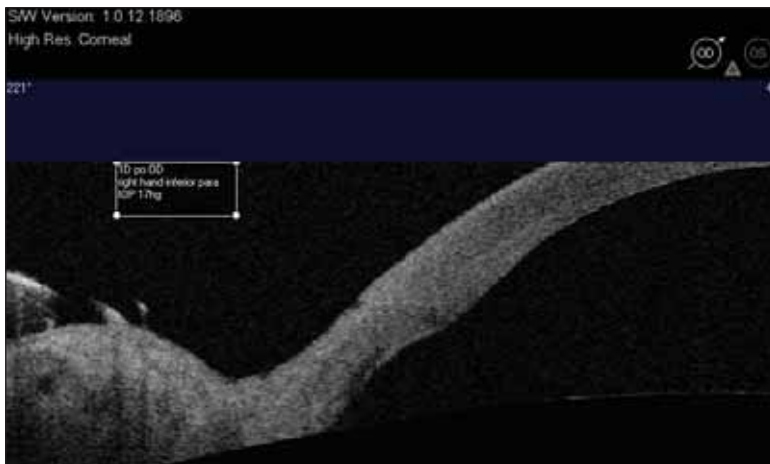


Figure 4. A routinely constructed sideport incision is viewed with the Visante OCT.

which adds a measure of stability and makes the sliding of one surface over the other considerably less likely.

The construction of the incision shown in Figure 3 was preceded by the creation of a 300- μ m groove at the incision's external edge. The incision itself has a curved or arcuate configuration, but the gaping of the external groove—visible on the first postoperative day—is accompanied by a similar offset of the internal lips of the incision, which appears to be somewhat less stable than a paracentesis-style incision.

Conclusions Drawn

All of the OCT images demonstrate the persistence on the first postoperative day (meaning at least 24 hours after surgery) of stromal swelling from stromal hydration, which many critics of clear corneal incisions believed disappeared within 1 to 2 hours. To confirm that the swelling was due to stromal hydration rather than surgical trauma, we took OCT images of cases in which there was no stromal hydration of the incision. In these incisions, there is less thickening around the incision and some gaping of its internal lip.

Some of the eyes were hypotonous, but the incisions were still perfectly well sealed, a finding that contradicts current thinking regarding hypotony and self-sealability.¹³ In addition, proper construction surprisingly resulted in a longer incision in the arc length rather than the measured chord length and in greater stability (like tongue-in-groove paneling).

Our findings demonstrate some of the

characteristics that we believe have contributed to the safety of clear corneal incisions and that, in conjunction with other prophylactic measures, can result in the absence of endophthalmitis. We have not had a single case of infectious endophthalmitis in more than 10 years and 10,000 cases. Endophthalmitis prophylaxis involves many factors, including a proper preoperative antibiotic regimen; the preparation of the surgical field, including Betadine (The Purdue Frederick Company, Stamford, CT) and draping over the lashes and meibomian orifices; the incision's construction; surgical technique, including atraumatic surgery; phaco power modulations to avoid heating the incision; not grasping the roof of the incision with a

toothed forceps, which would abrade the epithelium and disrupt the fluid barrier for endothelial pumping; the incision's closure utilizing stromal hydration; testing for leakage; and the use of postoperative antibiotics.

Although an attention to all of the details for endophthalmitis prophylaxis is essential, the construction of the incision leading to proper architecture is of primary importance in preventing endophthalmitis, as concluded in a recent white paper from the ASCRS.¹⁴ All clear corneal incisions are not the same. An incision in the plane of the cornea with a chord length of at least 2 mm appears to produce uniquely advantageous architecture for adequate self-sealability.

OUR STUDY: SIDEPORT INCISIONS

We have performed bimanual microincisional phacoemulsification for more than 6 years. In our experi-

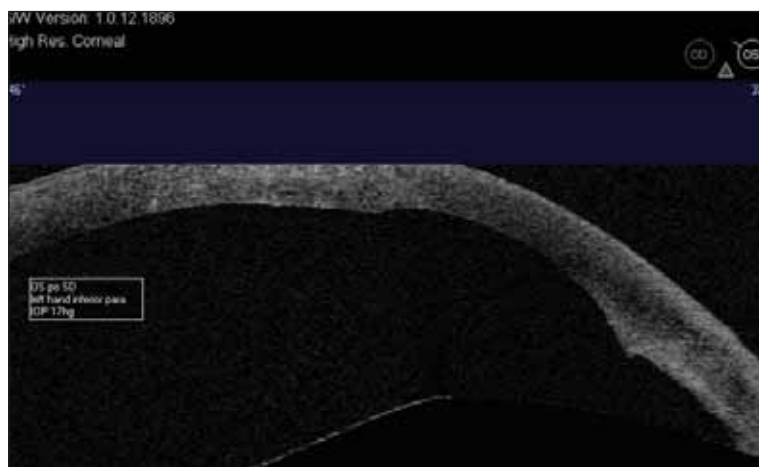


Figure 5. An appropriately constructed sideport incision is viewed with the Visante OCT.

ence, sideport incisions, through which we use irrigating choppers in one hand and an unsleeved phaco needle in the other, are a little more difficult to seal than our coaxial sideport incisions were. Researchers' attention has recently focused on possible damage to sideport incisions from an unsleeved phaco tip.¹⁵⁻¹⁸ It is important to note that, by their own admission, these investigators have not completed a learning curve in bimanual microincisional phacoemulsification, so some of what they demonstrated may be the result of their novice status with respect to this technique. Nonetheless, we decided to look at our sideport incisions with OCT (Figure 4), and we were surprised to find that many of them more closely resembled the clear corneal incisions seen in Figure 1 than they did our preferred architecture.

We therefore began to use the same amount of time and care in constructing sideport incisions as we do with our larger incisions. We were thus able to achieve exactly the same architecture (Figure 5).

“[Sideport incisions require] the same, appropriate construction as for temporal clear corneal incisions.”

Examining our sideport incisions with OCT forced us to recognize that their proper architecture requires the same appropriate construction as for temporal clear corneal incisions. The blade must be advanced in the plane of the cornea for an adequate length (approximately 1.5 mm) before it incises Descemet's membrane.

CONCLUSION

Proper architecture can be achieved, independent of the knife used, through the incision's appropriate construction. An unflinching attention to detail for both temporal clear corneal and sideport incisions is required. ■

This article is an extension of Fine IH, Hoffman RS, Packer M. Profile of clear corneal cataract incisions demonstrated by ocular coherence tomography. J Cataract Refract Surg. 2007;33:94-97.

I. Howard Fine, MD, is Clinical Professor of Ophthalmology at the Casey Eye Institute, Oregon Health & Science University, and he is in private practice at Drs. Fine, Hoffman, &



Packer in Eugene, Oregon. He is a consultant for Carl Zeiss Meditec, Inc. Dr. Fine may be reached at (541) 687-2110; hfine@finemd.com.

Richard S. Hoffman, MD, is Clinical Associate Professor of Ophthalmology at the Casey Eye Institute, Oregon Health & Science University, and he is in private practice at Drs. Fine, Hoffman, & Packer in Eugene, Oregon. He acknowledged no financial interest in the products or companies mentioned herein. Dr. Hoffman may be reached at (541) 687-2110; rshoffman@finemd.com.



Mark Packer, MD, is Clinical Associate Professor of Ophthalmology at the Casey Eye Institute, Oregon Health & Science University, and he is in private practice at Drs. Fine, Hoffman, & Packer in Eugene, Oregon. He is a consultant for Carl Zeiss Meditec, Inc. Dr. Packer may be reached at (541) 687-2110; mpacker@finemd.com.



- Cooper BA, Holekamp NM, Bohigian G, Thompson PA. Case-control study of endophthalmitis after cataract surgery comparing scleral tunnel and clear corneal wounds. *Am J Ophthalmol.* 2003;136:300-305.
- Nakagi Y, Hayasaka S, Kadoi C, et al. Bacterial endophthalmitis after small-incision cataract surgery: effect of incision placement and intraocular lens type. *J Cataract Refract Surg.* 2003;29:20-26.
- Eifrig CW, Flynn HW, Scott IU, Newton J. Acute-onset postoperative endophthalmitis: review of incidence and visual outcomes (1995-2001). *Ophthalmic Surg Lasers.* 2002;33:373-378.
- Miller JJ, Scott IU, Flynn HW Jr, et al. Acute-onset endophthalmitis after cataract surgery (2000-2004): incidence, clinical settings and visual acuity outcomes after treatment. *Am J Ophthalmol.* 2005;139:983-987.
- Monica ML, Long DA. Nine-year safety with self-sealing corneal tunnel incision in clear cornea cataract surgery. *Ophthalmology.* 2005;112:985-986.
- Masket S. Is there a relationship between clear corneal cataract incisions and endophthalmitis? *J Cataract Refract Surg.* 2005;31:735-741.
- Mollan SP, Gao A, Lockwood A, et al. Postcataract endophthalmitis: incidence and microbial isolates in a United Kingdom region from 1996 through 2004. *J Cataract Refract Surg.* 2007;33:265-268.
- Ng JQ, Morlet N, Bulsara MK, Semmens JB. Reducing the risk for endophthalmitis after cataract surgery: population-based nested case-control study. Endophthalmitis population study of western Australia sixth report. *J Cataract Refract Surg.* 2007;33:269-280.
- Moshirfar M, Feiz V, Vitale AT, et al. Endophthalmitis after uncomplicated cataract surgery with the use of fourth-generation fluoroquinolones: a retrospective observational case series. *Ophthalmology.* 2007;114:686-691.
- Lundstrom M, Wejde G, Stenevi U, et al. Endophthalmitis after cataract surgery: a nationwide prospective study evaluating incidence in relation to incision type and location. *Ophthalmology.* 2007;114:866-870.
- Fine IH. Self-sealing corneal tunnel incision for small-incision cataract surgery. *Ocular Surgery News.* May 1992;10:9:38-39.
- Fine IH. Clear corneal incisions. *Int Ophthalmol Clin.* 1994;34:59-72.
- Realini T. Wound construction key to avoiding endophthalmitis. *EyeWorld.* February 2007;12:2:64-66.
- ASCRS Cataract Clinical Committee. Special report: association between CCI and endophthalmitis [white paper]. *EyeWorld.* January 2007 (suppl). Available at: <http://www.eyeworld.org/ewweeksupplementarticle.php?id=187&strict=&morphologic=&query=association%20between%20CCI%20and%20endophthalmitis>. Accessed May 16, 2007.
- Vasavada AR. Phaco tips and corneal tissue. *Cataract & Refractive Surgery Today.* June 2005;5(suppl):6:9-10.
- Weikert M, Koch D. Phaco wounds study. *Cataract & Refractive Surgery Today.* June 2005;5(suppl):6:11-13.
- Berdahl JP, DeStafano JJ, Kim T. Corneal wound architecture and integrity after phacoemulsification: evaluation of coaxial, microincision coaxial, and microincision bimanual techniques. *J Cataract Refract Surg.* 2007;33:510-515.
- Osher RH, Injev VP. Microcoaxial phacoemulsification: part 1: laboratory studies. *J Cataract Refract Surg.* 2007;33:401-407.