Clear Cornea Versus Scleral Pocket

Research at the Wilmer Eye Institute.

BY ASHLEY BEHRENS, MD

During the past few years, the popularity of clear corneal incisions for cataract surgery has increased dramatically. The most recent surveys estimate that more than 72% of ophthalmic surgeons in the US favor this approach and more than 90% of them prefer unsutured cataract incisions,[1] originally introduced by I. Howard Fine, MD, in 1992.[2] Clear corneal incisions are widely accepted for their obvious benefits over other approaches. Some recent reports, however, have shown an increase in the rate of endophthalmitis,[3] and this rise has been temporally related to the introduction of the clear corneal approach. Case series comparing the incidence of endophthalmitis with clear corneal versus scleral tunnel incisions have favored the latter, which are associated with significantly lower rates of infection.[4]

> "We have developed several experimental designs to evaluate the watertightness of sutureless clear corneal incisions ... ex vivo and in vivo.

In an effort to explain this discrepancy, since 2002, Peter McDonnell, MD, has been leading a group effort of which I am a part at the Wilmer Eye Institute in Baltimore. We have developed several experimental designs to evaluate the watertightness of sutureless clear corneal incisions in ex vivo and in vivo models.

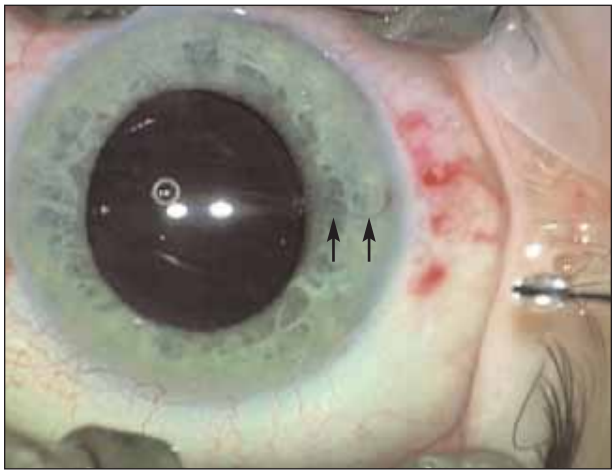

Figure 1. Blood-tinged fluid (arrows) flows into the anterior chamber after the investigators release slight pressure in the vicinity of the wound.

This article summarizes the results of our research to date and shares potential methods for optimizing the cataract incision.

OUR RESEARCH

Using conventional clear corneal incisions in human donor globes, we observed the ingress of extraocular fluid using a dye (India ink) placed on the surface of the globe by means of an ink-soaked sponge in the vicinity of the wound. The most interesting finding was that the ink tended to flow into the eye through clear corneal wounds only during hypotony. Shingleton et al have

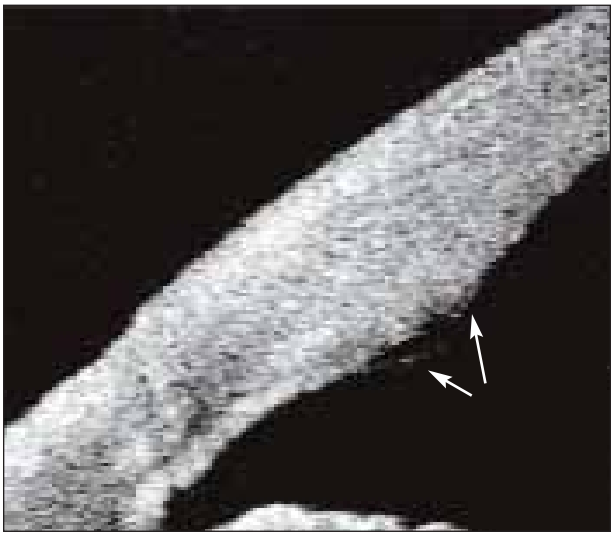

Figure 2. A localized, subclinical Descemet's membrane detachment (arrows) in the area of the incision may contribute to gaping of the wound.

shown that more than 20% of patients develop IOPs of 5 mm Hg or below during the first 30 minutes after cataract surgery using clear corneal incisions.[5] Cataract surgeons usually check the wound's integrity by increasing the IOP to detect outflow (Seidel method) but rarely check for extraocular fluid inflow, which could be more dangerous.

The donor globe model has been criticized, because it disregards the function of the endothelial cell pump, which ultimately may enhance the adherence of the wound's edges. We therefore attempted to reproduce the effects of ocular rubbing or blinking in patients during cataract surgery by applying slight pressure in the vicinity of the wound after mild limbal bleeding. Doing so allowed the validation of the endothelial cell pump's effects in the closure of the wound during the early postoperative period. We observed in these cases that the blood-tinged fluid reached the anterior chamber, signaling the wound's permeability to extraocular fluid (Figure 1), even after the hydrosealing of the wound.[6]

More recently, we analyzed the corneal wound's architecture in postoperative patients using anterior segment optical coherence tomography (Visante; Carl Zeiss Meditec, Inc., Dublin, CA).[7] This technology allows the evaluation of clear corneal wounds in the early postoperative period while preserving their actual shape, due to the noncontact nature of the procedure. In a short series, we detected evident gaping of the incisions in some patients at the 24-hour postoperative visit; these eyes thus may be at increased risk of bacterial invasion into the anterior chamber. Another interesting finding of this study was that most clear corneal incisions were associated with a localized Descemet's membrane detachment in the area of the incision (Figure 2). The complication may be associated with stretching of the wound during phacoemulsification or the insertion of the IOL.

All of these findings may contribute to the possible inflow of extraocular fluid into the anterior chamber through clear corneal incisions and would increase the risk of bacterial contamination.

POSSIBLE SOLUTIONS DERIVED FROM CORNEAL BIOMECHANICS

The clear corneal approach is currently the most common type of incision used for cataract surgery. It facilitates the procedure itself and contributes to the rapid postoperative recovery of the patient. Although we have not identified an indisputable cause-effect relationship between the use of sutureless clear corneal incisions and the development of postoperative endophthalmitis after cataract surgery, we believe that there is a strong association that deserves closer attention. Any method that promotes a complete sealing of these wounds is advantageous, because it will prevent the leakage of aqueous and the inflow of extraocular fluid and bacteria into the eye.

> "The use of sutures has repeatedly proven to prevent the inflow of India ink in our experimental models."

One common method for inducing the apposition of the wound's edges is hydrosealing. The surgeon injects the wound's edges with balanced salt solution in order to produce a localized corneal edema on both lips of the incision. In one of our published case series, the routine hydrosealing of the wound's edges did not appear to be as effective at preventing the inflow of extraocular fluid as it was at averting leakage.[6] Perhaps a new design in incisional architecture or other forms of hydrosealing the wound would more securely seal these wounds.

The use of sutures has repeatedly proven to prevent the inflow of India ink in our experimental models. One or two sutures placed on the incision may secure those wounds during the critical period of healing. The use of reabsorbable sutures instead of nylon has also been proposed. Many surgeons at the Wilmer Eye Institute are

adopting this practice, especially for cases in which the clear corneal wounds do not appear to be watertight. Unfortunately, we do not have evidence that this strategy prevents the development of endophthalmitis, but it may—at least hypothetically—avoid postoperative inflow.

In the near future, another approach could be the use of novel methods for closing the wound such as corneal adhesives. At least one group of investigators has published the use of a commercially available cyanoacrylate derivative to seal cataract wounds in patients.[8] At our laboratory, we are testing three different, reabsorbable components of sealants for closing the cataract incision.[9,10] It seems that the sealing capacity of these adhesives is superior to standard nylon 10–0 sutures in ex vivo models, and they may add stability to the eye immediately after surgery. More studies are necessary, however, to evaluate the adhesives' biocompatibility in animal models before their clinical use.

CONCLUSION

Clear corneal incisions have been instrumental to the advancement of cataract surgery, but some adjustments to this approach may be required. The quest for a perfectly configured wound and/or improved materials for closing the corneal wound are still an important area of clinical research. ■

Ashley Behrens, MD, is Assistant Professor of Ophthalmology at the Wilmer Eye Institute, the Johns Hopkins University School of Medicine, Baltimore. He is a consultant for Conversion Energy Enterprises and Dupont Health Care. Dr. Behrens may be reached at (410) 502-0461; abehren2@jhmi.edu.

1. Leaming DV. Practice styles and preferences of ASCRS members—2003 survey. *J Cataract Refract Surg*. 2004;30:892-900.
2. Fine IH. Clear corneal incisions. *Int Ophthalmol Clin*. 1994;34:59-72.
3. West ES, Behrens A, McDonnell PJ, et al. The incidence of endophthalmitis after cataract surgery among the U.S. Medicare population increased between 1994 and 2000. *Ophthalmology*. 2005;112:1388-1394.
4. Cooper BA, Holekamp NM, Bohigian G, Thompson PA. Case-control study of endophthalmitis after cataract surgery comparing scleral tunnel and clear corneal wounds. *Am J Ophthalmol*. 2003;136:300-305.
5. Shingleton BJ, Wadhwani RA, O'Donoghue MW, et al. Evaluation of intraocular pressure in the immediate period after phacoemulsification. *J Cataract Refract Surg*. 2001;27:524-527.
6. Herretes S, Stark WJ, Pirouzmanesh A, et al. Inflow of ocular surface fluid into the anterior chamber after phacoemulsification through sutureless corneal cataract wounds. *Am J Ophthalmol*. 2005;140:737-740.
7. Behrens A, Stark WJ, Pratzer KA, McDonnell PJ. Dynamics of small incision clear cornea wounds after phacoemulsification surgery in the early postoperative period using optical coherence tomography. *J Refract Surg*. In press.
8. Meskin SW, Ritterband DC, Shapiro DE, et al. Liquid bandage (2-octyl cyanoacrylate) as a temporary wound barrier in clear corneal cataract surgery. *Ophthalmology*. 2005;112:2015-2021.
9. Reyes JM, Herretes S, Pirouzmanesh A, et al. A modified chondroitin sulfate aldehyde adhesive for sealing corneal incisions. *Invest Ophthalmol Vis Sci*. 2005;46:1247-1250.
10. Noguera G, Lee WS, Castro-Combs J, et al. Novel laser-activated solder for sealing corneal wounds. *Invest Ophthalmol Vis Sci*. 2007;48:1038-1042.

Cataract & Refractive Surgery TODAY e-News

Subscribe to *Cataract & Refractive Surgery Today*'s e-News

A biweekly newsletter delivered directly to your e-mailbox contains news briefs and breaking news releases to keep you up-to-date between our print issues. Subscribing is easy and free. Simply e-mail us at eNews@bmctoday.com, type "Subscribe e-News" in the subject line, and include your name. You can unsubscribe at any time by clicking on the "unsubscribe" link in the e-Newsletter.

We look forward to hearing from you!