

Absent Iris Tissue

BY **FREDERICO F. MARQUES, MD; DANIELA M. V. MARQUES, MD;**

THOMAS A. OETTING, MS, MD; JAMES FREEMAN, MD; AND KEVIN M. MILLER, MD

CASE PRESENTATION

A patient taking Flomax (Boehringer Ingelheim Pharmaceuticals, Inc., Ridgefield, CT) underwent cataract extraction. During the procedure, the surgeon faced challenges now widely ascribed to intraoperative floppy iris syndrome (IFIS): repeated iris prolapse at the temporal wound resulting in a functional loss of iris tissue in the inferotemporal sector (Figure 1). No other intraoperative complications occurred, and the surgeon successfully placed and centered the IOL in the capsular bag. Although the patient regained excellent visual acuity, he unfortunately suffers from disabling glare postoperatively. How would you proceed?

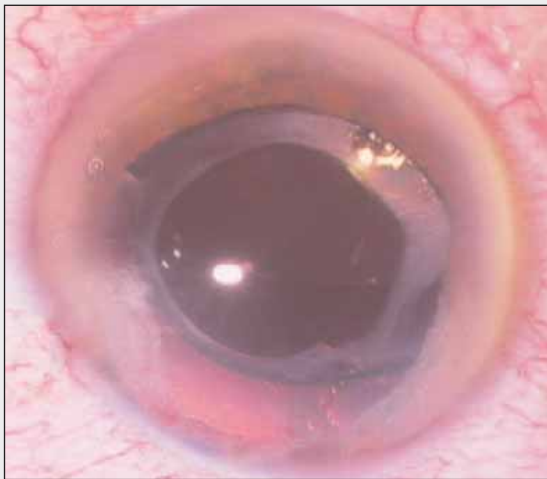


Figure 1. At the operative microscope, the absence of iris tissue for 2.5 clock hours is visible in this pharmacologically dilated eye. The iris tissue at either margin appears friable.

FREDERICO F. MARQUES, MD, AND DANIELA M. V. MARQUES, MD

Several techniques can repair missing iris tissue resulting in glare as well as the cause of its absence (eg, trauma, congenital condition). These approaches may be categorized as either iris repair with suturing or iris prosthesis. The first is commonly indicated when the

iris' margins are rigid and healthy with just a few hours of extension. In this case, both margins are friable, which makes passing needles difficult, could increase the lesion, and might cause bleeding. Fortunately, because the capsular bag is intact and centered, the implantation of an iris prosthesis would be possible. Among the options available, we would recommend a partial aniridia implant 96F (not approved by the FDA; Morcher GmbH, Stuttgart, Germany)—an endocapsular tension ring with a black segment on its inner aspect.

After entering the anterior chamber and filling it with a dispersive viscoelastic, we would use an iris spatula to break the adhesions between the anterior capsular margin and the anterior face of the IOL. If that approach failed, we would attempt dissection with a disposable 26-gauge needle to create an interface between the capsule and IOL.

Next, we would distend the capsular bag by injecting a dispersive viscoelastic and rotate the lens to liberate all of the possible adhesions to allow the implantation of the iris prosthesis. It is important to insert the device slowly into the capsular bag, over the IOL, and to avoid excessive manipulation and extension of the capsular bag. We would facilitate the implant's insertion with a second instrument (eg, an iris manipulator) from the sideport to direct the segment into the bag and avoid undesired traction at the anterior capsular margin and consequent rupture. Once inside the capsular bag, the ring would be rotated to match the iris segment with the area of absent iris.

Using I/A, we would remove the viscoelastic from the capsular bag via the rock 'n' roll technique while taking care not to damage the floppy iris. After instilling an intracameral miotic, we would check to see if the incision had sealed itself. If not, we would place a single 10–0 nylon suture and bury the knot.

THOMAS A. OETTING, MS, MD

This case demonstrates just how important it is to prevent iris prolapse during cataract surgery. Thanks to the clever detective work of Campbell and Chang,¹ cataract surgeons are now able to identify patients on Flomax as being at increased risk for iris prolapse. There

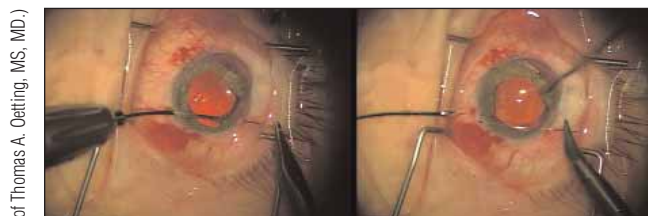

Figure 2. The surgeon can use the MST Duet Forceps to hold the residual iris while placing a 10-0 Prolene suture with a CTC-6 long, curved needle.

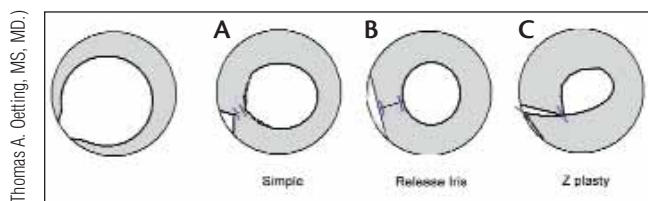


Figure 3. The three techniques for suture pupilloplasty shown are a simple closure at the pupil, release of the iris to reduce a peripheral iridotomy (PI)-like defect, and a Z-plasty technique.

are two ways to proceed in this case. One is to try suture pupilloplasty. The iris defect in Figure 1 looks large, however, which might stretch the limits of a suturing technique.

Suture pupilloplasty would allow for the smallest wound and least amount of paperwork to the institutional review board, but it would only work in this case if the residual iris were not too frayed or fibrotic. To begin, I would place paracenteses at approximately 7:00 and 10:00 o'clock. After administering nonpreserved 1% lidocaine and acetylcholine, I would use a microforceps (eg, the MST Duet [MicroSurgical Technology, Redmond, WA]) to investigate how flexible and sturdy the residual iris was. If it were flexible and the margins seemed capable of holding a suture, one of the following options might work.

“A device is indicated if the residual iris is quite frayed or the gap is large.”
—Thomas A. Oetting, MS, MD

The first alternative would be simply to suture the pupillary margin on one side to the margin on the other side. Doing so would reduce the pupil's size and glare, but it would leave a PI-like defect, which is less problematic with superior defects but might be an issue in this case. Placing the sutures can be tricky but is greatly

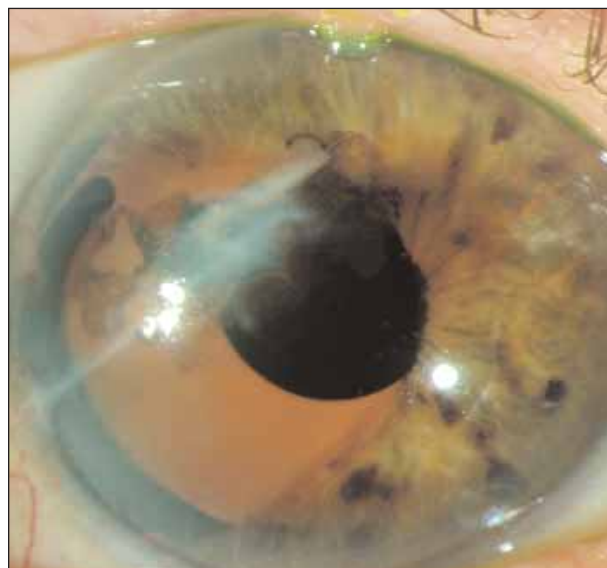
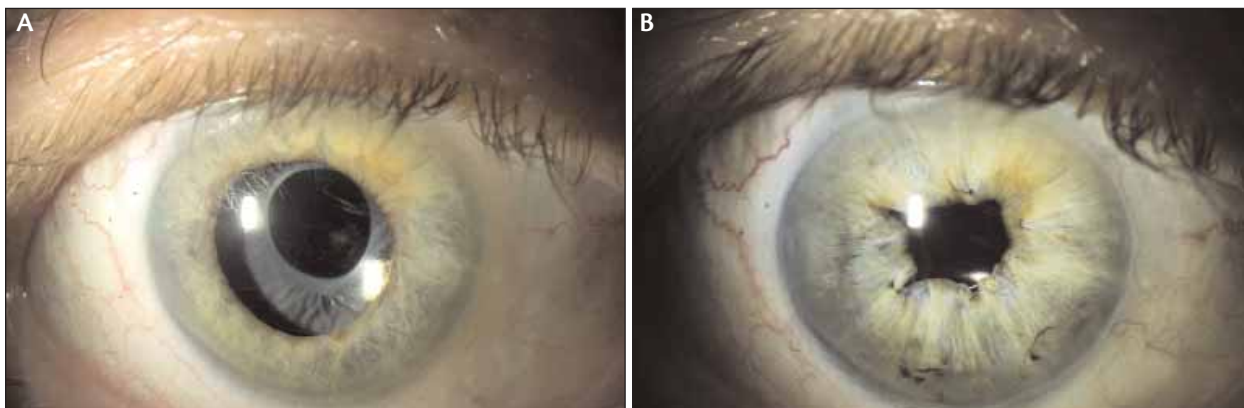

Figure 4. The surgeon uses an Ophtec model 311 to repair a traumatic iris defect similar to that of this case.

aided by the use of a microforceps and microscissors. I would hold the iris with the microforceps while placing the 10-0 Prolene suture with a CTC-6 long curved needle (both from Ethicon Inc., Somerville, NJ) through the cornea and iris (Figure 2). I would then release the microforceps and pass the needle through the superior pupillary margin and out. I would retrieve the suture—as described by Jameson^{2,3} and McCannel⁴—through one of the paracenteses and use a Siesper sliding knot^{5,6} to partially close the defect. One could probably place two sutures to leave a slightly smaller PI-like defect (Figure 3A). The more one closed the defect, however, the more oval the pupil would become. Releasing the iris near its root could allow additional closure of the PI-like defect but would run the risk of hyphema (Figure 3B).

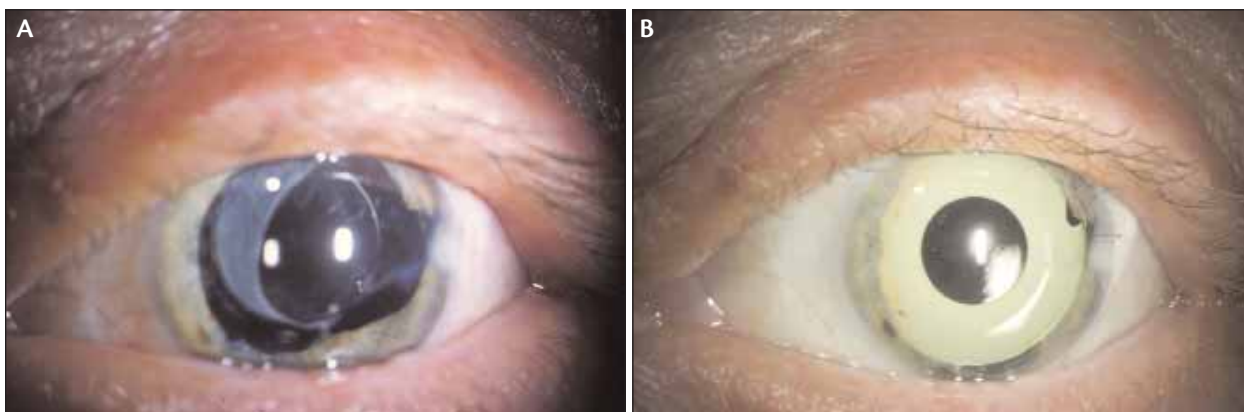
Another option to reduce the PI-like defect would be a Z-plasty approach. The surgeon would suture the pupillary margin from the inferior side of the defect to the sclera near the root of the residual superior iris. This portion of the procedure would be similar to an iridodialysis repair. Then, the surgeon would suture the pupillary margin of the superior remnant to the pupillary margin to form the smaller pupil (Figure 3C).

The second way in which to proceed in this case is device-based pupilloplasty. A device is indicated if the residual iris is quite frayed or the gap is large. Some administrative work would be required, because none of the devices for reconstructing the iris is approved by the FDA. I have the most experience with the iris reconstruction lens (model 311; Ophtec BV, Groningen, the Netherlands), because I am one of the surgeons partici-



(Courtesy of Kevin M. Miller, MD)

Figure 5. An IOP spike caused this mydriatic pupil. There was no tissue lost (A). The diameter of the pupil was reduced by a purse string pupilloplasty (B).



(Courtesy of Kevin M. Miller, MD)

Figure 6. This hyperopic eye had a mydriatic pupil with a considerable loss of iris tissue following cataract surgery (A). An Ophtec model 311 iris reconstruction lens was implanted in the ciliary sulcus over the current IOL (B).

pating in its FDA phase 3 trials. In this case, only the iris portion of the lens would be needed. I would recommend leaving the existing, nicely centered IOL in position and using a brown model 311 without the optic. I would make a superior 9-mm limbal or short scleral tunnel incision and place the device in the ciliary sulcus over the existing IOL (Figure 4).

The primary downside to using the model 311 is that it requires a large incision. The device does an excellent job of blocking light, however, and the delayed rehabilitation from the incision might be worth the wait. An alternative would be one of the modified capsular tension rings from Morcher GmbH, which would require an exemption for compassionate use from the surgeon's institutional review board.

JAMES FREEMAN, MD

The problem in this case is unfortunately becoming more common with the widespread use of Flomax and the nearly universal adoption of a temporal approach for routine cataract surgery. The first step in manage-

ment would be careful counseling of the patient as to the options available, realistic expectations for the risks involved, and the degree to which symptoms can be relieved.

I would initially offer a nonsurgical approach with a customized contact lens. Younger but not older patients often do quite well with these lenses. If this approach did not work, I would consider surgical intervention. In Figure 1, there appears to be too much tissue lost for adequate closure with a McCannel/Siepser suturing technique. I would, however, attempt some gentle exploration with an intraocular forceps through a paracentesis to see how mobile the remaining iris was before abandoning this option.

In eyes with a thin, traumatized iris and pigmentary loss, the symptoms of glare may persist in spite of a successful cosmetic closure of the iris. The best option in this patient is likely an iris prosthetic device. Although it would require obtaining an exemption for compassionate use, I would favor the 96G coloboma diaphragm (Morcher GmbH). This implant can be placed through a

relatively small incision in a manner familiar to any surgeon who routinely uses capsular tension rings. If a single 96G were not large enough to cover the defect, two could be placed in the capsular bag and “clocked” in slightly different positions.

I would approach any intraocular manipulation cautiously in this eye and would first attempt to sequester the remaining iris in the periphery with Healon 5 (Advanced Medical Optics, Inc., Santa Ana, CA). Gentle viscodissection of the capsular bag should allow the straightforward placement of the ring over this one-piece acrylic implant.

KEVIN M. MILLER, MD

It is unfortunate that repeated iris prolapse led to a loss of iris stromal tissue in this patient. I usually see a loss of iris pigment epithelium and iris transillumination defects in such eyes but not frank tissue loss.

As this case demonstrates, Flomax can be a real problem during cataract surgery. The changes it produces vary from nothing out of the ordinary to extreme floppiness of the iris. Flomax should cause us to rethink our history taking. No longer is it sufficient to record only the systemic medications a patient is currently using.

“I would advise implanting a sulcus-based, piggyback ... iris reconstruction lens.”

—Kevin M. Miller, MD

The least invasive approach to treating this patient’s symptoms of glare, but one I think seldom produces a satisfactory result, is to prescribe a tinted contact lens. The lens can be uniformly tinted, or it can have a hand-painted artificial iris. The former does not effectively block peripheral rays of light, which glare off the edge of the IOL and capsule; the latter is thick and uncomfortable to wear.

A purse string pupilloplasty approach works well when the pupil is chronically dilated but there is no loss of tissue. The eye shown in Figure 5A experienced a postoperative IOP spike that caused a mydriatic pupil. Because no iris tissue was lost, it was possible to reduce the diameter of the pupil by weaving a Prolene suture through its perimeter as shown in Figure 5B.

In my opinion, sulcus-based implants from Morcher GmbH such as the 96C do not work very well. The effective pupillary diameter is too large, and the implants are difficult to turn inside the eye. Capsular-bag implants such as the 96F (Morcher GmbH) need to

be implanted at the time of cataract surgery.

In this case, I would advise implanting a sulcus-based, piggyback model 311 (Ophtec BV) or model 67B (Morcher GmbH) iris reconstruction lens. Residual refractive errors, if any, could be corrected at the same time. The patient in Figure 6 had a small, hyperopic eye with a shallow anterior chamber. The surgeon significantly damaged the iris during phacoemulsification. Figure 6A shows the eye after cataract surgery, and Figure 6B shows the eye after the implantation of a green model 311 iris reconstruction IOL. ■

Section Editors Robert J. Cionni, MD; Michael E. Snyder, MD; and Robert H. Osher, MD, are cataract specialists at the Cincinnati Eye Institute in Ohio. They may be reached at (513) 984-5133; msnyder@cincinnatieye.com.

James Freeman, MD, is Clinical Assistant Professor of Ophthalmology at the University of Tennessee in Memphis. He acknowledged no financial interest in the products or companies mentioned herein. Dr. Freeman may be reached at (901) 767-3937; flyeyes@mac.com.

Frederico F. Marques, MD, and Daniela M. V. Marques, MD, are fellows of the cataract sector at the Federal University of São Paulo/EPM and Clinical Directors of the Marques Eye Institute in São Paulo, Brazil. They acknowledged no financial interest in the products or companies mentioned herein. Drs. Marques may be reached at +55 11 56773513; fredani2010@hotmail.com.

Kevin M. Miller, MD, is Kolokotronis Professor of Clinical Ophthalmology at the Jules Stein Eye Institute in Los Angeles. He is an unpaid investigator for the study of the Ophtec 311 iris reconstruction lens and an unpaid principle investigator for a study of a Morcher implant in which he holds his own investigational device exemption. Dr. Miller may be reached at (310) 206-9951; miller@jsei.ucla.edu.

Thomas A. Oetting, MS, MD, is Professor at the University of Iowa in Iowa City. He acknowledged no financial interest in the products or companies mentioned herein. Dr. Oetting may be reached at (319) 384-9958; thomas-oetting@uiowa.edu.



1. Chang DF, Campbell JR. Intraoperative floppy iris syndrome associated with tamulosin. *J Cataract Refract Surg.* 2005;31:664-673.
2. Hammill MB, Quayle WH. Iris repair after a catastrophic laser in situ keratomileusis complication. *J Cataract Refract Surg.* 2005;31:2216-2220.
3. Jameson PC. Re-attachment in iridodialysis: a method which does not incarcerate the iris. *Arch Ophthalmol.* 1909;38:391-396.
4. McCannel MA. A retrievable suture for anterior uveal problems. *Ophthalmic Surg.* 1976;7:98-103.
5. Siepser SB. The closed chamber slipping knot technique for iris repair. *Ann Ophthalmol.* 1994;26:71-72.
6. Osher RH, Snyder ME, Cionni RJ. Modification of the Siepser slip knot technique. *J Cataract Refract Surg.* 2005;31:1098-1100.