Favorite Phaco Technique

BY RICHARD B. PACKARD, FRCS, FRCOPHTH; ROXANA URSEA, MD; ROBERT E. KELLAN, MD; AND DAVID ALLEN, BSC, FRCS, FRCOPHTH

I asked several outstanding surgeons and exceptional teachers a straightforward question: "What is your preferred method of performing phacoemulsification?" The diverse and fascinating answers will be shared in two installments of this column. Enjoy! **—William J. Fishkind, MD, FACS**

RICHARD B. PACKARD, FRCS, FRCOPHTH

We are in an era when phaco power is being reduced by modulations and machines have fluidics that maintain stable chambers at high vacuum and flow rates. Our nuclear removal techniques need to reflect the current situation. Mechanical disassembly in various forms for different types of cataracts also helps and usually speeds up the procedure.

For soft and moderately soft nuclei, I use an Akahoshi Combo Prechopper (ASICO, Westmont, IL) to break the nucleus into four pieces that are then removed almost entirely with high flow rates and vacuum. In order to simplify prechopping, I first make sure the nucleus is spinning freely in the bag. Then, I refill the anterior chamber with viscoelastic to provide a counterforce for the prechopper to enter the nucleus.

With medium and moderately hard cataracts, I use a vertical chopping technique. The phaco power is modulated by various forms of interrupted delivery. On the Sovereign cataract extraction system (Advanced Medical Optics, Inc., Santa Ana, CA), I use four long pulses per second of C:F (6 milliseconds on, 12 milliseconds off) Whitestar Technology (Advanced Medical Optics, Inc.), with the power set at 25% and a Whitestar ICE boost of 12%. On the Infiniti Vision System (Alcon Laboratories, Inc., Fort Worth, TX), I use Ozil torsional phacoemulsification (Alcon Laboratories, Inc.) set at 70% with linear microburst and bursts of 120 milliseconds, up to four per second, at full power. I employ high vacuum and flow to hold the pieces of nucleus being chopped and use minimal power to massage the pieces through the 30° Kelman phaco tip I favor for all cases.

For very hard cataracts, I sculpt a short trench of about 50% depth using 40% C:F on the Sovereign and 100% continuous Ozil ultrasound on the Infiniti. The superior cutting ability of the Kelman tip helps. Sculpting creates a wall into which to bury the phaco tip, a maneuver that improves occlusion and holding for chopping dense nuclei. If the first chop does not pass all the way through the nucleus, I move the tip farther down and separate the nuclear material repeatedly until the base plate splits. I use the same chopping settings as for medium cataracts, flow rates of between 30 and 40mL/min, and vacuum settings of 400 to 500mmHg depending on the tip's size.

ROXANA URSEA, MD

During cataract surgery, my goals are to achieve the best postoperative result and to have a happy patient (and surgeon) on the day after surgery. I therefore follow two rules. First, *festina lente* (do not rush). Second, I try to pay attention to details during each stage of the procedure. The final surgical outcome depends on the quality of each step, starting with the incision's architecture and finishing with the wound's sealing.

An often overlooked step is hydrodissection. When inadequate, it leaves an epinucleus adherent to the capsule that is difficult to aspirate and mobilize. For effective hydrodissection, I use a brief, forceful, radially oriented fluid jet, which produces a slowly propagating wave that separates the epinucleus from the capsule. I make sure I can gently rotate the nucleus before starting to chop.

My preferred technique of cataract extraction is the vertical quick chop, especially for moderately dense nuclei. I like that the central placement of the phaco chopper within the pupillary aperture allows easier visualization and control of the instrument. The phaco tip should be embedded deep into the nucleus for nuclear stability. I prefer using a bevel-down tip because it efficiently grasps the nuclear mass. This

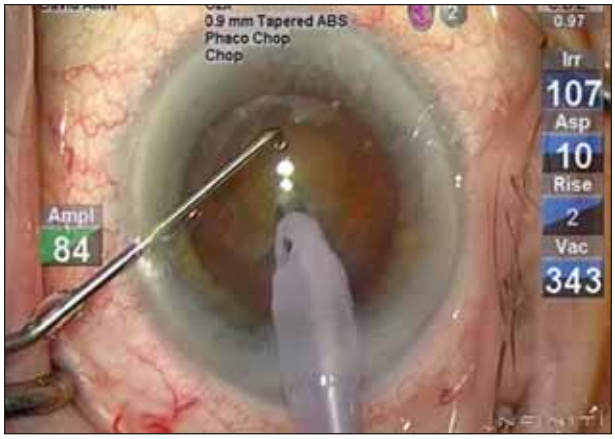

(Courtesy of David Allen, BSc, FRCS, FRCOphth.)

Figure 1. Removing the cortex from the superficial nucleus permits more accurate positioning of the phaco tip and chopper.

configuration also directs all the ultrasound energy toward the nucleus without affecting the endothelium and the trabecular meshwork. With this technique, there is no need to pass the chopper under the anterior capsule and out to the equator, a maneuver that is sometimes done "blindly."

ROBERT E. KELLAN, MD

I prefer the supracapsular technique for removing cataracts. When I was a resident at the New York Eye and Ear Infirmary ages ago, I had the privilege of assisting the late Charles Kelman, MD, when he was pioneering phacoemulsification. At that time, he was emulsifying the lens in the anterior chamber but had a significant number of compromised corneas. Sometime later, as a member of the New York Intraocular Implant Society, I dined and conversed with Charlie on several occasions, and I reminded him of the anterior chamber approach to cataract removal. He told me that, with today's viscoelastics, the anterior chamber was still the safest place to remove the cataract, and I have found it to be so.

To perform this technique successfully, surgeons must use a noncohesive viscoelastic and should construct a 5- to 7-mm capsulorhexis. They should perform hydrocortical cleavage until the nucleus tilts out of the capsular bag and then instill some viscoelastic under the nucleus into the bag. Next, they should use two instruments to rotate the cataract out of the bag and instill more noncohesive viscoelastic over the lens. The surgeons should then prechop the nucleus using a stabilizing instrument through the paracentesis and the minimized chopper through the phaco incision. During phacoemulsification of the compromised cataract, little of the phaco tip should be exposed, and surgeons can keep the activity on the iris plane with the paracentesis instrument. Finally, they should carefully remove the viscoelastic after cortical cleanup and the IOL's implantation.

DAVID ALLEN, BSc, FRCS, FRCOphth

My standard lens removal technique is horizontal chopping as originally described by Nagahara.[1] When studying different power modulations 2 years ago, I used a stop-and-chop technique to divide the nucleus into two pieces and consumed each half with different modulations. I was astonished to find that two-thirds to three-quarters of the total phaco energy I used was for sculpting the single trench.

First, I sculpt away the cortex within the capsulorhexis' opening. This step is quick and easy, and it uses virtually no phaco energy. If left in place, the cortex limits how deeply I can bury the needle when chopping. This step is also useful for trainees, who often feel uncomfortable passing the chop-

per out toward the equator. With this technique, one can pass the chopper between the edge of the sculpted cortex and nucleus and know that it is inside rather than on top of the capsule (Figure 1).

I ensure that the sleeve is retracted sufficiently (1.5 to 2.0mm) to allow the tip to penetrate the nucleus and hold it steady while I draw the chopper toward the needle's tip. Only when the chopper has reached the tip of the needle do I part the instruments horizontally.

During the past 9 months, I have had the opportunity to use the new Ozil torsional phaco handpiece. It works well with the technique I have described, and there is no repulsion of the nuclear fragments while they are consumed. ■

Section editor William J. Fishkind, MD, FACS, is Co-Director of the Fishkind and Bakewell Eye Care and Surgery Center in Tucson, Arizona, and Clinical Professor of Ophthalmology at the University of Utah in Salt Lake City. Dr. Fishkind may be reached at (520) 293-6740; wfishkind@earthlink.net.

David Allen, BSc, FRCS, FRCOphth, is a consultant ophthalmologist specializing in cataract surgery in Sunderland, England. He has received reimbursement for travel and lodging expenses from Alcon Laboratories, Inc. Mr. Allen may be reached at +44 191 5699071; david@allen50.fsnet.co.uk.

Robert E. Kellan, MD, is Director of the Kellan Eye Center in Boston and Assistant Professor of Ophthalmology at Boston University. He acknowledged no financial interest in the products or companies mentioned herein. Dr. Kellan may be reached at (978) 682-8661; rekellan@aol.com.

Richard B. Packard, FRCS, FRCOphth, is Clinical Director of the Prince Charles Eye Unit at King Edward VII Hospital in Windsor, United Kingdom. He is a consultant for Alcon Laboratories, Inc., and Advanced Medical Optics, Inc. Mr. Packard may be reached at +44 20 7580 1074; eyequack@vossnet.co.uk.

Roxana Ursea, MD, is Assistant Professor of Ophthalmology and Director of Cornea and Refractive Surgery for the Department of Ophthalmology at the University of Arizona in Tucson. She acknowledged no financial interest in the products or companies mentioned herein. Dr. Ursea may be reached at (520) 322-3800 ext. 204; rursea@eyes.arizona.edu.

1. Nagahara K. Phaco chop. Video presented at: The ASCRS/ASOA Symposium on Cataract, Refractive and IOL Surgery; May 8-12, 1993; Seattle, WA.