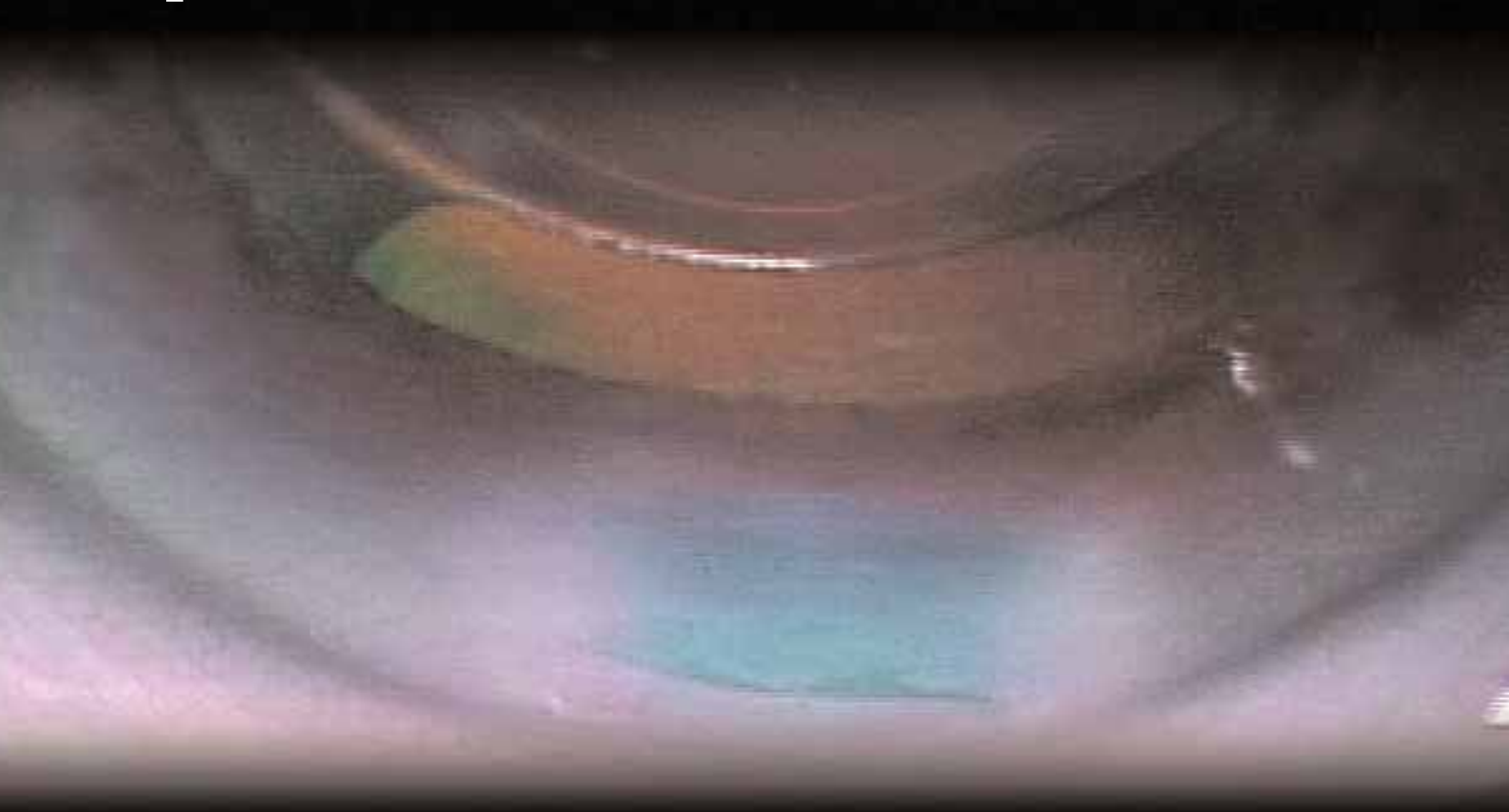


Cataract & Refractive Surgery TODAY

June 2005

Micro-Incision Phacoemulsification:

Exploring Options to Optimize Patient Outcomes



MICROINCISIONAL COAXIAL PHACOEMULSIFICATION BY RICHARD MACKOOL, MD

FAREWELL TO BIMANUAL BY TAKAYUKI AKAHOSHI, MD

PHACO TIPS AND CORNEAL TISSUE BY ABHAY R. VASAVADA, MBBS, MS, FRCS

PHACO WOUNDS STUDY BY MITCHELL P. WEIKERT, MD, AND DOUGLAS D. KOCH, MD

MICROCOAXIAL PHACOEMULSIFICATION BY KHIUN TJIA, MD

Micro-Incision Phacoemulsification:

Exploring Options to Optimize Patient Outcomes



Dr. Richard Mackool



Dr. Takayuki Akahoshi



Dr. Abhay R. Vasavada



Dr. Mitchell P. Weikert



Dr. Douglas D. Koch



Dr. Khiun Tjia

3 MICROINCISIONAL COAXIAL PHACOEMULSIFICATION

A new device enables a 2.1-mm phaco technique.

BY RICHARD MACKOOL, MD

5 FAREWELL TO BIMANUAL

Developing a sub-2-mm coaxial phaco and IOL insertion technique.

BY TAKAYUKI AKAHOSHI, MD

9 PHACO TIPS AND CORNEAL TISSUE

Histomorphology and immunohistochemistry reveal the effects of sleeveless and sleeved tips.

BY ABHAY R. VASAVADA, MBBS, MS, FRCS

11 PHACO WOUNDS STUDY

Alterations in corneal wound architecture with bimanual microincisional phacoemulsification.

BY MITCHELL P. WEIKERT, MD, AND DOUGLAS D. KOCH, MD

14 MICROCOAXIAL PHACOEMULSIFICATION

Phacoemulsification and IOL implantation through a 2-mm incision.

BY KHIUN TJIA, MD

Microincisional Coaxial Phacoemulsification

A new device enables a 2.1-mm phaco technique.

BY RICHARD MACKOOL, MD

The interest in using smaller incisions in cataract surgery has generated many proposed surgical methods. Most recently, the bimanual microincisional cataract surgery procedure has received a good deal of press. This approach basically divides the 2.8-mm incision that many surgeons currently use for coaxial phacoemulsification into two incisions that are approximately half that size. In the interest of making bimanual microincisional cataract surgery as efficient as possible, I have designed some instruments with Alcon Laboratories, Inc. (Forth Worth, TX), that can be used through these microincisions but do not require incisional leakage (this leakage was one of my concerns about the bimanual microincisional cataract surgery procedure). These new instruments, featuring a rigid sleeve around a flared ultrasonic needle, eliminate incisional leakage and

thereby minimize the amount of fluid passing through the eye.

DEVELOPING THE TECHNIQUE

The question still remains whether two small incisions are better than one. In that regard, Alcon designers and I began to consider smaller coaxial incisions that use a reduced-diameter infusion sleeve on the phaco tip. With the Infiniti Vision System (Alcon Laboratories, Inc.), we designed an Ultra sleeve that fits on a standard flare tip, passes through a 2.1-mm incision, and permits the removal of the cataract with great efficiency (Figure 1). The Ultra sleeve is scheduled for release later this year. I refer to the phaco procedure performed with this equipment as *microincisional coaxial phacoemulsification*, or *MICP*.

With MICP, flow and vacuum levels can be reasonably

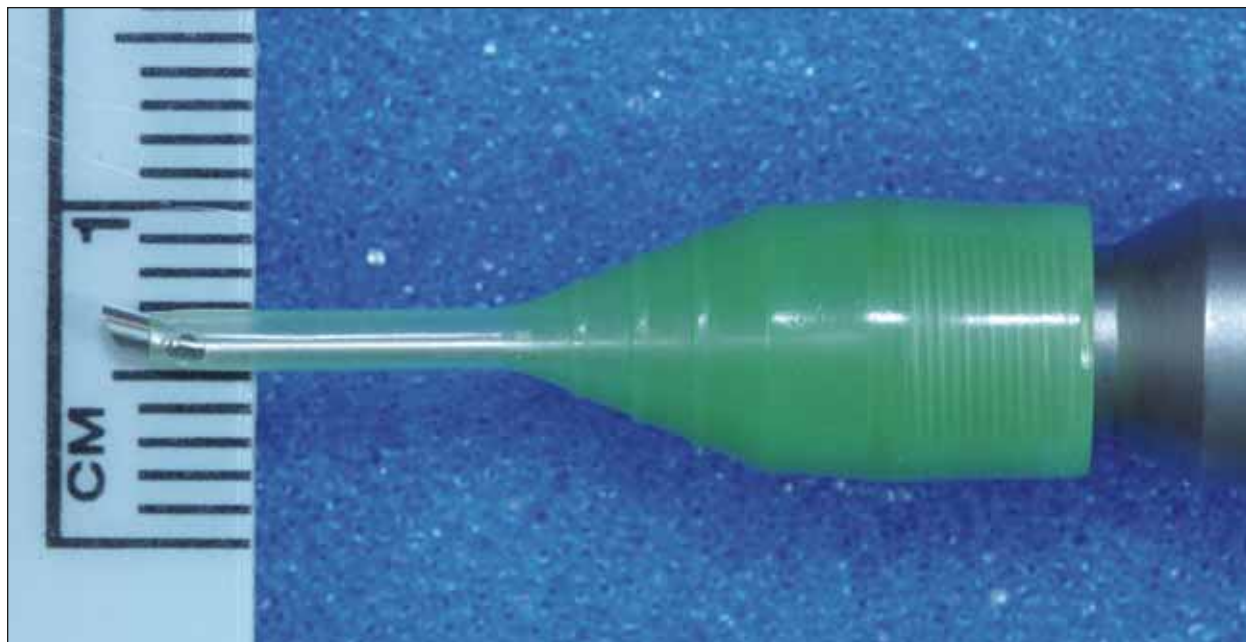


Figure 1. The Ultra sleeve fits on a standard flared phaco tip.

high (although they must be less than those that are attainable with the use of the flare tip and high infusion sleeve). With an infusion bottle height of 135cm, the surgeon can use an aspiration flow rate of 40 to 50mL/min and a maximum vacuum level of 400mmHg. These parameters suit most surgeons and permit a phaco procedure that is comparable in efficiency to those performed through larger incisions.

One major benefit of the 2.1-mm incision is that it will accommodate IOL insertion without requiring significant enlargement. Using the Monarch C cartridge delivery system (Alcon Laboratories, Inc.), a single-piece acrylic IOL can be injected with the cartridge-in-tunnel technique, after which the 2.1-mm incision will have enlarged slightly to between 2.3 and 2.5mm. This incision is now the smallest that has yet been achieved with current IOL technology approved in the US.

EXPERIENCE

I have performed approximately 20 procedures with the Ultra sleeve and small-incision coaxial technique. All of the procedures have been routine, with unremarkable postoperative courses and immediately clear corneas. I have been able to remove the nucleus in less than 2 minutes in all eyes.

SURGICAL OPTIONS

I would expect most surgeons to opt for a single, 2.1-mm incision rather than the bimanual microincisional cataract surgery technique that uses two smaller incisions of approximately 1.5mm each and may be less efficient. Although some surgeons feel that they can perform the

bimanual technique as rapidly as the coaxial method, the experience of many others, including myself, is quite different. I believe that the bimanual technique is definitely slower for very efficient surgeons who prefer to operate at high flow and vacuum levels. However, deliberate surgeons who use a coaxial technique and a flow rate of 25 to 30mL/min to remove nuclear segments may not lose efficiency with the bimanual microincisional cataract surgery technique. The Infiniti Vision System permits the use of higher flow and vacuum parameters with the bimanual microincisional cataract surgery technique than do other systems. Nonetheless, MICP offers the best of both worlds (ie, a smaller incision, efficiency that is comparable if not identical to phacoemulsification performed through larger incisions, and no learning curve).

It is obvious that surgeons will prefer those techniques that permit them to remove the cataract and insert the IOL through the smallest possible incision, provided that doing so does not reduce surgical efficiency or compromise the quality of the IOL that can be inserted. With the MICP procedure, these requirements have clearly been satisfied. ■

Richard Mackool, MD, is Director of The Mackool Eye Institute and Laser Center in Astoria, New York, and Senior Attending Surgeon at The New York Eye and Ear Infirmary. He is a consultant for Alcon Laboratories, Inc., but states that he holds no financial interest in any Alcon products, including the technologies discussed in this article. Dr. Mackool may be reached at (718) 728-3400; mackool@eye@aol.com.

Farewell to Bimanual

Developing a sub-2-mm coaxial phaco and IOL insertion technique.

BY TAKAYUKI AKAHOSHI, MD

I have never liked bimanual phaco procedures. Their limited irrigation and inherent wound leakage does not allow me to use high phaco parameters, they often leave the anterior chamber unstable, they take a longer time to perform, and in my hands, the incidence of complication with a bimanual technique is much higher than with my normal phaco surgery. Although each bimanual incision is small, the total incision length is larger than my conventional 2.5-mm coaxial phaco surgery.

Because I wanted to perform my coaxial phaco technique through a small incision, I designed a new phaco tip sleeve called the *Nano sleeve* (Alcon Laboratories, Inc., Fort Worth, TX). It has a smaller diameter and a thinner wall than a conventional micro sleeve. The Nano sleeve fits onto the Akahoshi phaco tip (Alcon Laboratories, Inc.) beautifully and delivers perfect fluidic performance (Figure 1).

INCREASED IRRIGATION

My typical amount of irrigation with a conventional micro sleeve is 100mL/min, but with the new Nano sleeve, it averages 88mL/min. I use an extension pole to raise the bottle height. Making a third port with a micro trephine on the inferior side of the sleeve increases the amount of irrigation. As the irrigation through the third port flows downward, it can push the posterior capsule away from the ultrasound



Figure 1. The Akahoshi Nano sleeve features three irrigation ports and fits onto the Akahoshi phaco tip.

tip and thus reduce the incidence of rupturing the posterior capsule. Other small manipulations helped me to finally achieve 120mL/min of irrigation. This level of irrigation, combined with the excellent fluid management of the Infiniti Vision System (Alcon Laboratories, Inc.), allows me to realize rapid and safe phacoemulsification in a stable anterior chamber. I am able to safely and comfortably perform sub-2-mm surgery at 500mmHg vacuum and a flow rate of 40mL/min at a dynamic rise of +2.

MY SUB-2-MM COAXIAL PHACO TECHNIQUE

In sub-2-mm coaxial phaco surgery, it is especially important to protect the incision, because it is the same one used to implant the IOL. With the Infiniti Vision System, I can reduce the total amount of U/S energy in order to protect the incision. My secrets for successful ultra-low-energy surgery include performing mechanical nucleofracture via the phaco prechop technique, using linear burst mode with NeoSoniX (Alcon Laboratories, Inc.), and employing the Akahoshi phaco tip. The Infiniti Vision System's excellent power modulation protects the incision, and its superb fluidics facilitate cataract removal.

For a routine phaco procedure, I make a temporal, 1.8-mm incision (Figure 2) with a newly designed trapezoidal diamond keratome (Figure 3). For a dense or mature

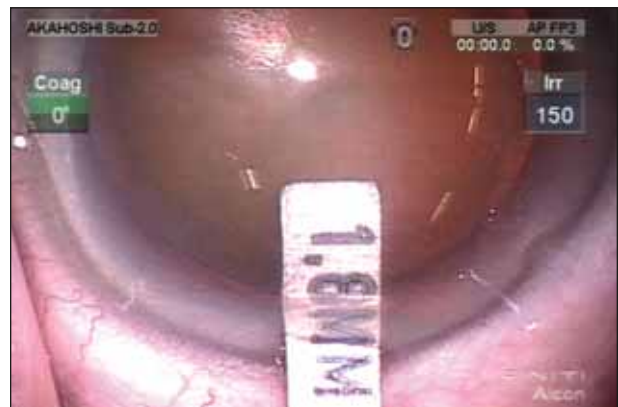

Figure 2. An incision gauge confirms the 1.8-mm size of the author's temporal incision.



Figure 3. The new Akahoshi sub-2-mm, 100- μ m diamond keratome (American Surgical Instruments Corporation).

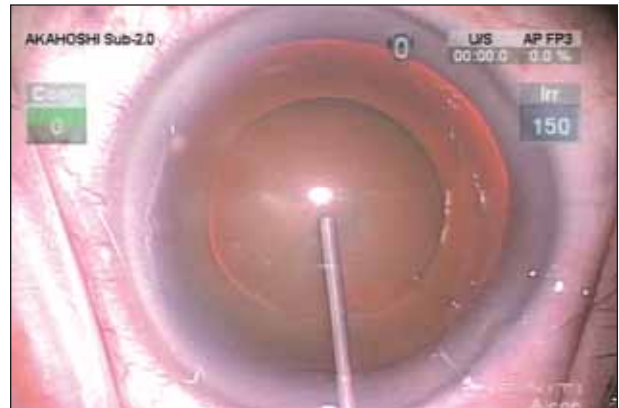


Figure 4. The author instills Provisc viscosurgical device to spread Viscoat over the corneal surface.

white cataract, I stain the capsule with indocyanine green (ICG). To protect the corneal endothelium from the dye, I use the soft shell stain technique, which is a modified version of the soft shell technique devised by Steve Arshinoff, MD, FRCSC, in Toronto.

Next, I fill the anterior chamber with Viscoat followed by Provisc ophthalmic viscosurgical devices (both by Alcon Laboratories, Inc.). I use the Provisc to spread the Viscoat uniformly over the corneal surface (Figure 4). After removing the Provisc with I/A (Figure 5), I effectively apply visco-ICG solution to the capsule with a special visco-ICG cannula (AE-7272; American Surgical Instruments Corporation, Westmont, IL) (Figure 6). Compared with dissolving the ICG solution in BSS, the visco-ICG, which is dissolved in Provisc, can attain much deeper and uniform staining.

The merit of sub-2-mm coaxial phacoemulsification is the ability to use conventional instruments and techniques with it. I use traditional Utrata capsulorhexis forceps (Katena Products, Inc., Denville, NJ) to make the cap-

sulorhexis and phaco prechoppers (American Surgical Instruments Corporation) to divide the nucleus. It is not necessary to use expensive sideport capsulorhexis forceps or unfamiliar irrigating choppers with this technique. The size of the capsulorhexis should be slightly smaller than the IOL's optic so that the anterior capsule may cover the optical edge. This coverage is an important surgical step for preventing the formation of a posterior capsular opacification.

After performing sufficient hydrodissection with the Akahoshi Hydrodissection G27 cannula (American Surgical Instruments Corporation [reusable], or Alcon Laboratories, Inc. [disposable]), I prechop the nucleus using a universal prechopper (Figure 7). To prechop a dense cataract, I always support the nucleus using a second instrument called a *nucleus sustainer*, which reduces the stress on the zonules and capsular bag. The phaco prechop technique eliminates the process of sculpting and grooving the nucleus, which consumes much U/S energy. On the Infiniti Vision System, I use a linear burst mode, with which I can control the inter-

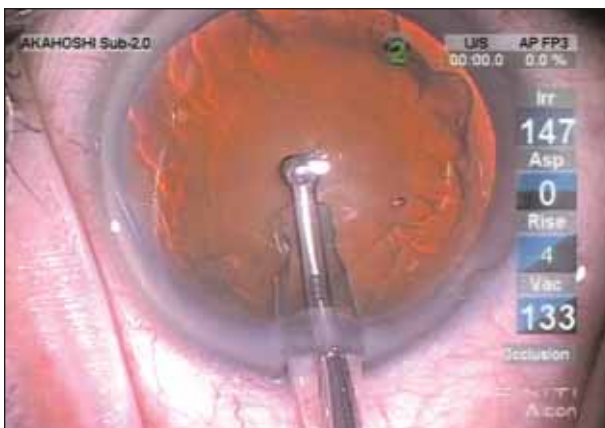


Figure 5. The author extracts the Provisc with I/A using the Knuckle Tip (American Surgical Instruments Corporation).

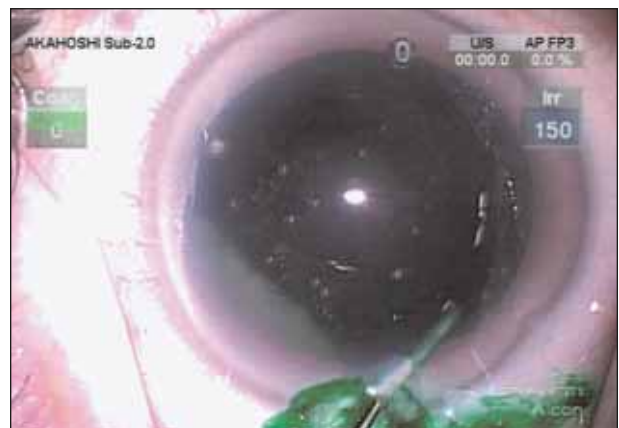

Figure 6. The author uses a visco-ICG cannula to apply visco-ICG solution to the capsule.

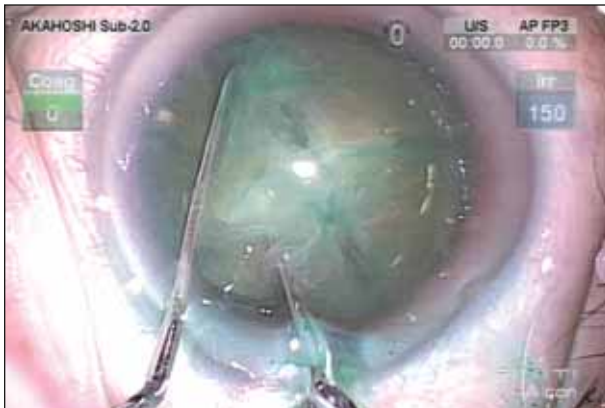

Figure 7. The author uses a universal prechopper to prechop the nucleus into fragments.

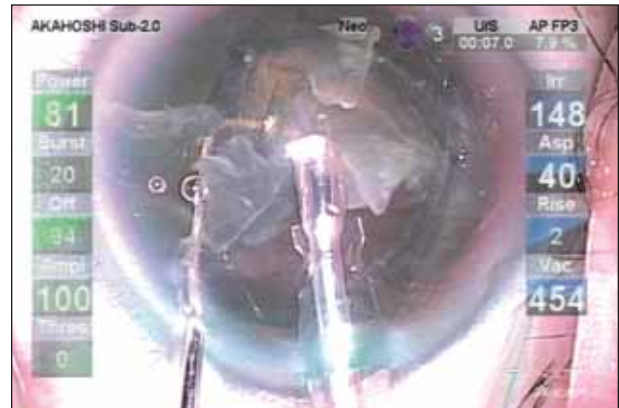

Figure 8. A nuclear sustainer (instrument at left) helps to control the nuclear fragments during aspiration.

val of the phaco energy as well as the U/S power. According to the nuclear density, I preset the burst width at between 10 and 30ms. To control the nuclear fragment during phacoemulsification, I also use the nucleus sustainer (Figure 8).

Next, without using any special instruments, I implant a single-piece 6-mm AcrySof lens through the sub-2-mm incision. I use the Royale Unihand Injector with the spring option (American Surgical Instruments Corporation) with the Monarch C cartridge (Alcon Laboratories, Inc.). My technique is to use the nucleus sustainer through the side-port incision to hold the eye and provide a counterforce to the pressure of the injector (Figure 9). This is called the *countertraction implantation technique*. This implantation technique is only possible with a unihand injector handpiece such as the Royale.

When implanting the 6-mm AcrySof single-piece IOL, the important point to remember is that both haptics should be folded and placed over the optic so that the optic may be set in the cartridge curling downward (Figure 10). As the plunger stays in contact with the cartridge floor, this setting

is mandatory in order for the plunger to push the lens optic properly. I cannot insert the C cartridge nozzle into the anterior chamber, but simply pushing the cartridge port toward the incision enables me to implant the lens through the incision. Due to the unique design of the single-piece AcrySof, the elbow of the lens haptic works to pilot the lens optic into the incision. It is important not to interrupt the implantation once the lens is introduced in the incision. Also, I fill the anterior chamber with Provisc to maintain a firm eye before IOL implantation.

At the conclusion of the surgery, the incision size is 1.9mm (Figure 11). The wound will self-seal via IOP (Figure 12). I usually do not hydrate the corneal stroma because there is no damage to the incision.

SURGICAL PRINCIPLES

I perform my surgery based on three principles. First, I use U/S energy only when the tip is completely occluded in the nucleus. I use the Akahoshi phaco tip, which easily achieves complete occlusion with the nucleus.

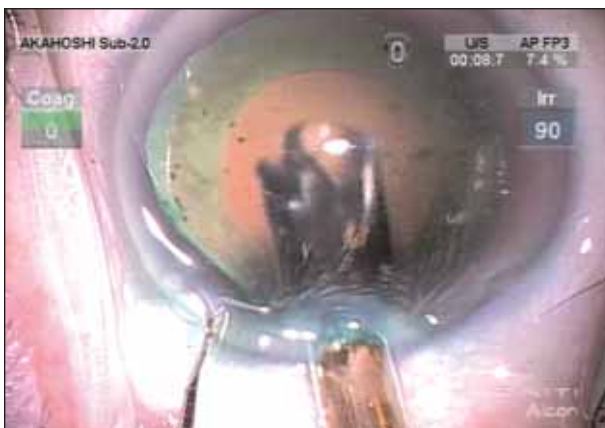

Figure 9. The author demonstrates the countertraction implantation technique.




Figure 10. The author shows how best to load the AcrySof implant in the Monarch injector.

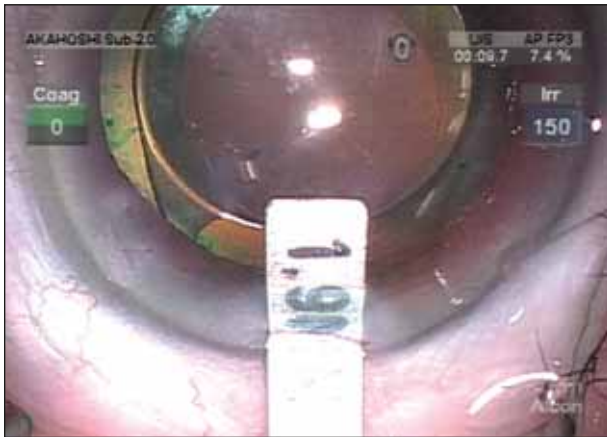


Figure 11. The incision is 1.9mm at the conclusion of the sub-2-mm coaxial phaco surgery.

Second, I use a minimum amount of ultrasonic energy. I employ the NeoSoniX handpiece and linear burst mode for power modulation.

Third, it is important to protect the ocular tissues, including the corneal endothelium and the incisions. For this purpose, I use Viscoat for every case, and I manipulate the nuclear fragments with a second instrument. For a soft nucleus of grade 1 or 2 and in cases with intact ciliary zonules, I perform the vertical karate prechop technique with a Combo Prechopper (American Surgical Instruments Corporation). I insert the sharp side of the prechopper blade into the center of the nucleus and press it downward. It is important to continue to push the nucleus when the prechopper blades are opened. For nuclei harder than grade 3 or in cases of weak ciliary zonules, I support the nucleus with the nucleus sustainer to reduce the stress on the zonules and capsular bag. I carefully introduce the sustainer under the capsulorhexis' edge and support the nucleus at the deep equator. I use a universal prechopper with a sharp tip that I insert into the dense nucleus. The tip of the sustainer, the hard core of the nucleus, and the tip of the prechopper should be aligned on the same axis. I perform all dividing procedures under the viscoelastic material, which allows me to take my time and be certain that the nucleus has been completely divided.

RECENT CATARACT INNOVATIONS

Phaco Handpieces and Tips

The new NeoSoniX handpiece has a tip that oscillates $\pm 2^\circ$ 100 times per second. This oscillation is driven by the motor, so there is no heat production. I find the bent tip of the NeoSoniX handpiece particularly effective, because it moves the lens material on the tip, constantly repositioning the material for efficient removal.

Of the bent tips, the Kelman tip is the most famous and

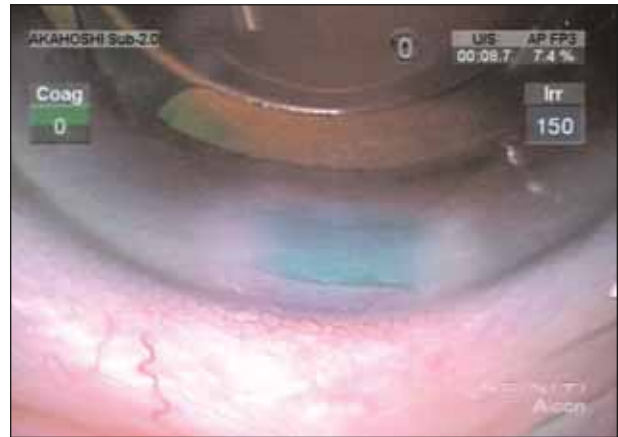


Figure 12. The wound in the sub-2-mm coaxial phaco technique will self-seal due to IOP.

popular, but trying to completely occlude that tip with its bevel aimed down toward the nucleus puts too much stress on the incision and damages it. I designed my Akahoshi phaco tip, a 1.1-mm standard flared tip, to bend 20° toward its bevel in order to easily obtain complete occlusion with the nucleus. Also, the tip lies parallel to the incision and thus stresses it less. It oscillates effectively on the NeoSoniX handpiece. This tip reduces the amount of U/S energy remarkably, in my opinion.

IOLs

We now have the ReStor IOL (Alcon Laboratories, Inc.), which features accurate biometry as well as astigmatic control, which is very important. My sub-2-mm coaxial phaco surgery should be an ideal procedure for this IOL.

I believe the AcrySof Natural (Alcon Laboratories, Inc.) protects the retina, and I now consider it my standard IOL. I can implant this 6-mm lens through a sub-2-mm incision without any difficulty.

IN CONCLUSION

With the new Nano sleeve and some modifications to the irrigation system, along with new techniques and IOL technology, I now perform coaxial phaco surgery through a sub-2-mm incision with a final incision size of 2mm or less. I believe this technique is the new standard of phaco surgery for the next generation of surgeons, and that there is no more need for the complicated microincisional bimanual phaco surgery. Sayonara bimanual! ■

Takayuki Akahoshi, MD, is Director of Ophthalmology at the Mitsui Memorial Hospital in Tokyo. He is an unpaid consultant for Alcon Laboratories, Inc., and states that he holds no financial interest in any of the products or companies mentioned herein. Dr. Akahoshi may be reached at +81 3 3862 9111; eye@phaco.jp.

Phaco Tips and Corneal Tissue

Histomorphology and immunohistochemistry reveal the effects of sleeveless and sleeved tips.

BY ABHAY R. VASAVADA, MBBS, MS, FRCS

There is a growing interest in small-incisional phacoemulsification, also known as *bimanual microincisional phacoemulsification*. When my colleagues, Bharti Nihalani, MBBS, MS; Kaid Johar, PhD; and I began studying this approach, we noticed that it did not stabilize the anterior chamber very well, and we could not use vacuum power of more than 250mmHg or an aspiration flow rate of more than 25mL/min. What most struck us about bimanual microincisional phacoemulsification, however, was the incision architecture. Although critical in this procedure, it was not always pristine at the end of the surgery. Many times, intraoperative corneal hydration and edema interfere with the surgeon's view of the surgical field, and the technique distorts the internal and external incisions. Subsequently, we decided to study bimanual microincisional phacoemulsification's effect on the incision histomorphology and the surrounding collagen, which is the extracellular matrix support for the cornea.

Bimanual microincisional phacoemulsification requires a bare (sleeveless) phaco tip to pass through a microincision. We studied whether the bare tip negatively affects the incision and surrounding corneal tissue. We designed our study to compare the effect of the sleeveless tip with a sleeved one (a phaco tip with a conventional irrigation sleeve). We conducted the study using 20 eyes of

10 rabbits. We performed a bimanual procedure in which we randomized one eye to the bare ultrasound tip and one eye to the sleeved tip. We used the Sovereign cataract extraction system with Whitestar Technology (Advanced Medical Optics, Inc., Santa Ana, CA) using interrupted energy in pulse mode. We used exactly the same parameters in both sets of eyes. We made the incisions for the sleeveless phaco tip 1.2mm and the incision size for the infusion sleeve 2.4mm. We also used five rabbit eyes as a control. In these, we made an incision of 1.2 and 2.4mm but did not perform any surgery, so those incisions acted as a control for comparing our histomorphology and the immunohistochemistry observations.

Immediately after the surgery in both groups, my colleagues and I collected samples and subjected them to histo-

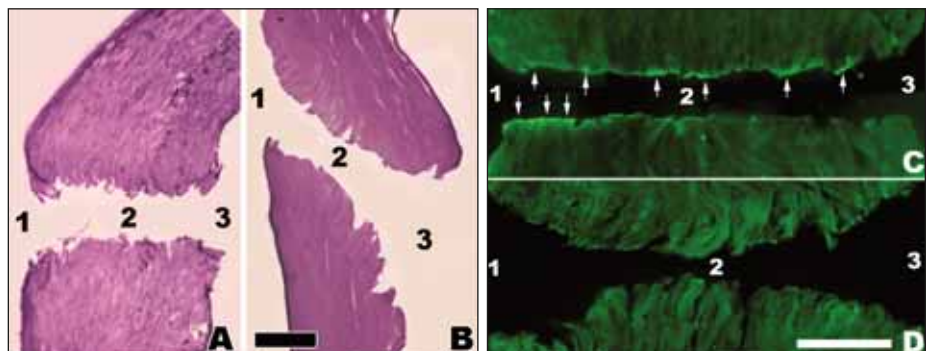


Figure 1. In comparing the histomorphology and immunohistochemistry of the sleeveless versus the sleeved phaco tips (Bar = 100mm), the sleeveless tip (A) caused (1) extensive epithelial damage to the external entry, (2) a disorganized arrangement of the collagen fibers, fluid-filled spaces, and black focal areas of heat-induced coagulated necrosis on the lining of the stromal tunnel, and (3) a marked loss of endothelial cells in the internal entry site. The sleeved tip (B) left (1) minimal epithelial damage to the external entry, (2) a normal arrangement of collagen fibers, minimal fluid-filled spaces, and no focal areas of heat-induced coagulated necrosis on the lining of the tunnel, and (3) minimal damage to endothelial cells at the internal entry point. Furthermore, the sleeveless tip showed intense areas of heat-induced coagulation necrosis of collagen (C), whereas the sleeved tip showed none (D).

morphology and immunohistochemistry. We performed the histomorphology using periodic acid-schiff and hematoxylin-eosin stains. We conducted the immunohistochemistry in order to visualize the collagen. For this, we used mouse antibody against collagen as the first antibody. This complex was detected using another, antimouse antibody tagged with fluorescein dye AF488, which is a well-established immunohistochemical technique to evaluate the damage inflicted on collagen.

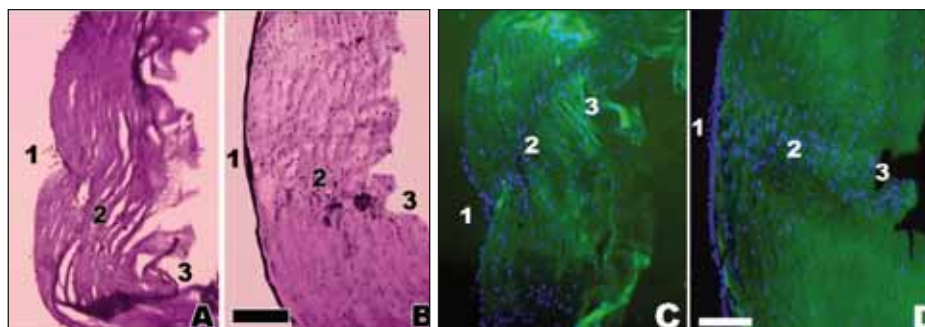


Figure 2. In comparing wound healing with the sleeveless and sleeved phaco tips (Bar = 100mm), histomorphology and immunohistochemistry showed seriously disorganized collagen fibers, tissue buckling and contraction around the tunnel and at internal entry with the sleeveless tip (A, B) but a regular arrangement of collagen fibers and no buckling or contracture around the incision with the sleeved tip (C, D).

OBSERVATIONS

Sleeveless Tip

With these two techniques, we examined three areas of the incision: the external entry, the tunnel in the corneal stroma, and the internal entry. In the eyes operated on with the sleeveless phaco tip, the histomorphology revealed marked epithelial damage at the external entry. In the corneal stroma, we found severe damage to the tissue lining the tunnel. Furthermore, the normal arrangement of the collagen fibers was grossly disorganized, and there were many areas filled with fluid. Most importantly, however, we found black focal areas of heat-induced coagulated necrosis on the lining of the tunnel. Finally, the internal entry of the incisions showed a marked loss of endothelial cells (Figure 1A).

Sleeved Tip

Compared with the sleeveless phaco tip, eyes treated with the infusion sleeve showed minimal damage to the external entry. The tunnel and corneal tissue maintained a normal arrangement of collagen fibers and minimal areas of fluid-filled spaces. Importantly, heat-induced necrosis of collagen was absent. On the internal entry, the endothelium revealed minimal damage (Figure 1B).

Likewise, immunohistochemistry examination showed intense areas of heat-induced coagulation necrosis of collagen with the sleeveless tip (Figure 1C) but none with the infusion sleeve (Figure 1D).

Comparison With the Control

The histomorphology and immunohistochemistry of incisions with the sleeved tip were comparable with the control. I believe these significant findings suggest that the

infusion sleeve of a phaco tip protects the collagen fibers.

STUDYING WOUND HEALING

We subsequently wondered what the effects of these changes would be on the healing process of the incisions, which determines the incisional strength and the amount of induced astigmatism and endothelial damage. With that in mind, we conducted another set of experiments in 10 rabbit eyes, five using the sleeveless tip and five with the infusion sleeve. We examined the incisions after euthanizing the rabbits 1 month later. The incisions that accommodated the sleeveless tip again showed seriously disorganized collagen fibers, with tissue buckling and contraction around the tunnel and also at the internal entry point on the endothelium site (Figure 2A and B). In contrast, the incisions that received the sleeved phaco tip maintained the regular arrangement of collagen fibers and showed no contracture or buckling of the tissues around the incision (Figure 2C and D).

CONCLUSIONS

These findings have an important implication in the long term. My colleagues and I are interested in studying these effects further and evaluating them over a longer time period. We also wish to conduct similar studies with newer designs of phaco sleeves, which show great promise in reducing the size of coaxial incisions even further to approximately 2mm. ■

Abhay R. Vasavada, MBBS, MS, FRCS, is Director of the Iladevi Cataract & IOL Research Centre, Raghudeep Eye Clinic, Memnagar, Ahmedabad, India. He states that he holds no financial interest in any product or company mentioned herein. Dr. Vasavada may be reached at +91 79 27492303; shailad1@sancharnet.in.

Phaco Wounds Study

Alterations in corneal wound architecture with bimanual microincisional phacoemulsification.

BY MITCHELL P. WEIKERT, MD, AND DOUGLAS D. KOCH, MD

Bimanual microincisional cataract surgery, or bimanual phacoemulsification, is a technique for cataract extraction that has been steadily increasing in popularity. It is developing in concert with or in advance of IOL technology that can capitalize on the small incisions that the technique uses. Many investigators tout the benefits of bimanual microincisional cataract surgery, such as increased anterior chamber stability or decreased ultrasound energy. However, little information has been published on the effect it has on corneal wounds. Wound trauma has been demonstrated with scanning electron microscopy following the insertion of IOLs with forceps and injectors in standard, coaxial phacoemulsification.¹ Our clinical experience has suggested that higher levels of wound edema may be seen after bimanual microincisional phacoemulsification as compared with the standard coaxial technique. These observations provided the motivation for this study, which sought to investigate the changes in wound architecture found with bimanual microincisional phacoemulsification and to characterize their dependence on the diameter and design of phaco tips.

PARAMETERS AND METHODS

In this experimental study, a single surgeon performed bimanual microincisional phacoemulsification on 10 cadaver eyes using the Infiniti Vision System (Alcon Laboratories, Inc., Fort Worth, TX). He used multiple bare phacoemulsification needles in combination with an irrigating chopper (Microsurgical Technologies, Redmond, WA) through corneal wounds that varied in size between 1.2 and 1.5 mm. He kept the phaco energy and times constant from case to case.

The first two cases served as controls. One eye received only corneal incisions without the introduction of phaco instruments. The other received standard, large-incisional phacoemulsification with coaxial infusion

using the 0.9-mm ABS tip (Alcon Laboratories, Inc.). We tested three different bare phaco tips in the remaining bimanual cases: the straight 0.9-mm microtip, the flared microphaco tapered (both by Alcon Laboratories, Inc.), and the microphaco Mackool tip with a nonirrigating polyimide sleeve (Richard J. Mackool, MD).

We measured the size of the phaco tips with a micrometer, and we measured corneal wound size pre- and postoperatively using incision gauges. We then harvested the corneas and fixed them in glutaraldehyde immediately following the surgeries. We subsequently examined the changes in wound architecture using scanning electron microscopy. We quantified endothelial cell loss and tearing in Descemet's membrane using the scale provided with each scanning electron micrograph.

RESULTS

The phaco needles were all similar in size, varying from 0.98 to 1.01 mm in diameter. The coaxial tip with




Figure 1. The inner surface of the cornea after the surgeon made a 1.5-mm single, unused paracentesis incision (without using a phaco tip or irrigating chopper) served as the control.




Figure 2. After the surgeon made a 2.9-mm coaxial phaco incision, the inner surface of the cornea showed surrounding endothelial cell loss and minimal tearing of Descemet's membrane.




Figure 3. The inner surface of the cornea after the surgeon made a 1.2-mm bimanual phaco incision after cataract removal with the microtip turbosonics tip shows endothelial cell loss and tearing of Descemet's membrane.

sleeved infusion measured 1.93mm in diameter. The corneal wound measurements all increased in size by 0.1 to 0.2mm after cataract surgery. We examined both the external and internal surfaces of the corneal wounds using scanning electron microscopy. There were no significant differences in the external wound architecture between the different phaco tip designs, but the internal wound structure showed significant differences in endothelial cell loss and Descemet's membrane trauma for the various phaco needle styles.

Endothelial Cell Loss

The endothelium was preserved around each corneal wound in the control eye that received incisions only (Figure 1). All eyes that underwent phaco-emulsification showed a loss of endothelial cells surrounding each incision. The area of endothelial cell loss was greatest in the coaxial case, which had the largest incision (Figure 2). The 0.9-mm microtip had the smallest area of loss, followed by the microphaco tapered tip. Although the microphaco Mackool tip had the largest area of cell loss, the cell loss of all of the bare tips was fairly comparable (Figure 3).

When the area of endothelial cell loss was normalized to the phaco tip diameter, the ratio was lowest for the standard coaxial wound and greatest for the bimanual cases (Figure 4). The 0.9-mm microtip had the lowest ratio, followed by the microphaco

tapered tip, and then by the microphaco Mackool tip. In essence, for a given tip diameter, the bare tips caused greater endothelial cell loss for a given wound size.

Descemet's Membrane Trauma

We measured the incision lengths on the scanning electron micrographs using the linear scale included on each photograph. We noted tearing of Descemet's membrane with every incision. Three varieties of tearing were found: lateral extension at the ends of the incision, rupture of the anterior or posterior wound lip, and a continuous tear resulting in the loss of a flap of Descemet's membrane. We measured the linear extent of tearing and compared it to the size of the incision

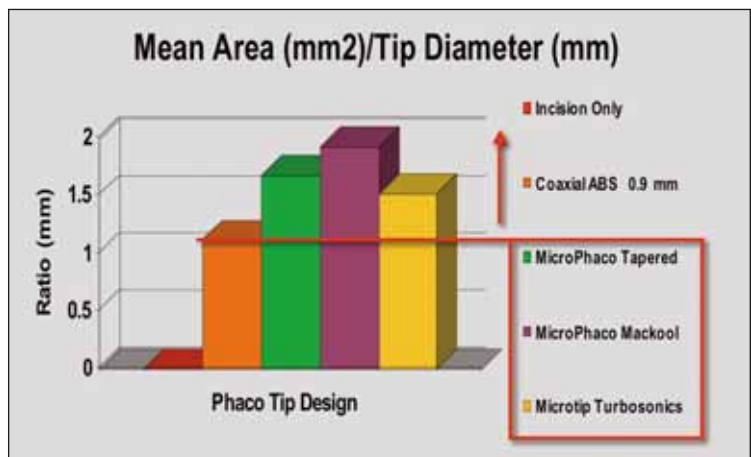


Figure 4. The authors normalized the mean area of endothelial cell loss surrounding the corneal incisions to the diameter of the phaco tip.

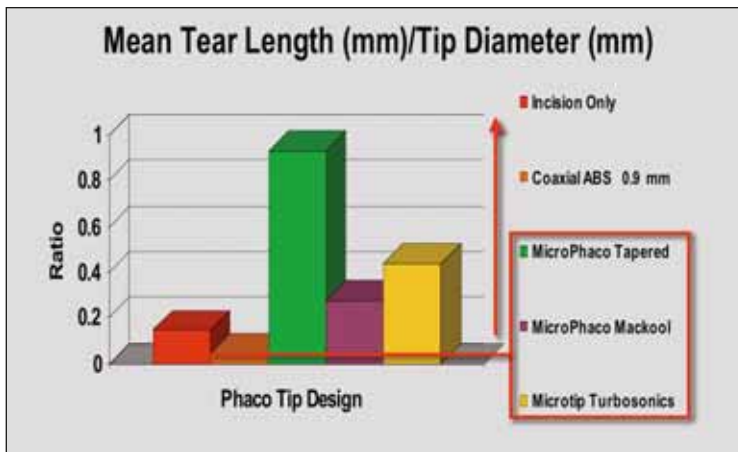


Figure 5. The authors normalized the mean length of Descemet's membrane tearing to the incision size.

(Figure 5). The resulting ratio was lowest for the eye that received standard coaxial phacoemulsification. The bare phaco tips displayed greater tearing ratios, and the microphaco tapered tip had the greatest level of Descemet's membrane trauma. The straight 0.9-mm microtip had less tearing, while the microphaco Mackool tip had the lowest ratio for the bimanual cases.

CONCLUSIONS

Corneal wound architecture as seen with scanning electron microscopy was altered in all eyes that underwent cataract extraction via phacoemulsification. We saw endothelial cell loss surrounding all the corneal incisions, with the bare bimanual phaco tips demonstrating greater loss than the standard coaxial technique when we normalized the results to the diameter of the phaco tips. The bimanual tips also showed greater trauma to Descemet's membrane, as evidenced by the level of tearing revealed by scanning electron microscopy. The microphaco Mackool tip with a polyimide sleeve showed the least amount of tearing. Standard, large-incisional phacoemulsification with coaxial infusion employs a small phaco tip, 1mm or less in diameter, surrounded by a larger, flexible sleeve. This setup allows the

phaco tip to move freely within the incision while minimizing leakage through the large wound. In contrast, the incision for the bimanual phaco port is sized much closer to the diameter of the phaco needle to minimize fluid loss and preserve anterior chamber stability. This tighter wound geometry likely increases stress on the wound, which may explain the architectural changes found in this study.

This was a small, experimental study, thus it could not demonstrate statistical significance. However, it did show a trend toward greater wound trauma in bimanual microincisional phacoemulsification. Clinical implications may include difficulty with intraoperative wound sealing, an increased use of sutures, greater postoperative wound edema, and/or prolonged wound healing. These issues are worthy of further investigation.

Although microincisional cataract surgery may have significant potential, the small incision size combined with the bare-tip design may create corneal wound geometry that is predisposed to operative trauma. ■

Mitchell P. Weikert, MD, is in private practice in the Department of Ophthalmology, Baylor College of Medicine, Houston. He is a consultant for Alcon Surgical, Inc., but states that he holds no financial interest in any product or company mentioned herein. Dr. Weikert may be reached at (713) 798-4766; mweikert@bcm.tmc.edu.

Douglas D. Koch, MD, is Professor and the Allen, Mosbacher, and Law Chair in Ophthalmology at the Cullen Eye Institute, Baylor College of Medicine, Houston. He states that he holds no financial interest in the products or companies mentioned herein. Dr. Koch may be reached at (713) 798-6443; dkoch@bcm.tmc.edu.

1. Kohnen T, Koch DD. Experimental and clinical evaluation of incision size and shape following forceps and injector implantation of a three-piece high-refractive-index silicone intraocular lens. *Graefes Arch Clin Exp Ophthalmol.* 1998;236:12:922-928.

Microcoaxial Phacoemulsification

Phacoemulsification and IOL implantation through a 2-mm incision.

BY KHIUN TJIA, MD

We are seeing an inevitable trend toward small-incision phacoemulsification in cataract surgery. Approximately 5 years ago, I started to employ the wound-assisted Acrysof single-piece (Alcon Laboratories, Inc., Fort Worth, TX) Monarch II injection technique with the Monarch II B cartridge (Alcon Laboratories, Inc.) through a 2.75-mm incision. Later, I converted to using the C cartridge with 2.6-mm incisions and the easy injection of the Acrysof single-piece IOLs. I had already noticed that the 2.4-mm incisions were large enough for the same injection technique, but the phaco sleeves were the bottleneck for smaller incisions. This problem led me to work with Alcon Laboratories, Inc., to develop smaller phaco sleeves for microincisional coaxial phacoemulsification.

THE BENEFITS OF MICROINCISIONAL COAXIAL PHACOEMULSIFICATION

Currently, bimanual microincisional phacoemulsification uses two rigid instruments through tight incisions. The greatest drawback of this technique is, in my opinion, the way these instruments severely stretch and distort the incisions. The tight fit and necessary manipulation of the hard metal cannula and phaco tip through the microincisions during cataract surgery cause direct stress to the lamellar structure of the corneal incisions' tissue. This trauma inevitably weakens the wounds and leads to possible late leakage with an unquestionably higher risk for endophthalmitis. Bimanual microincisional phacoemulsification also involves a learning curve. Microincisional coaxial phacoemulsification, however, is basically identical to the surgeon's own technique but uses a smaller incision. The soft, malleable infusion sleeve adapts to the wound and does not affect its integrity during manipulation. The idea of inserting a 6-mm Acrysof single-piece IOL through a 2.0- to 2.2-mm incision with the Monarch II injection system without inducing significant wound stretch is, of course, a marvel to phaco surgeons and patients. The IOL has a long track record of high-quality patient outcomes and very low posterior capsular opacification rates.

TECHNIQUE

My technique for microincisional coaxial phacoemulsification is exactly the same as my traditional phaco technique. I use a metal blade made by Alcon Laboratories, Inc., to make the main incisions, either 2mm (for IOLs in the low-to-mid diopter range) or 2.2mm (for IOLs in the mid-to-high diopter range). I then create two small (<1-mm), sideport incisions and perform a capsulorhexis under Viscoat ophthalmic viscosurgical device (Alcon Laboratories, Inc.) with a standard (Inamura-style) capsulorhexis forceps.

After hydrodissecting the nucleus, I use my routine fast-crack phaco technique, which is a faster, modified divide-and-conquer technique with very efficient ultrasound delivery. I use an Ultra sleeve (Alcon Laboratories, Inc.) and a 0.9-mm, flared, Kelman-style phaco tip (Alcon Laboratories, Inc.). My vacuum settings with the microincisional coaxial technique are only 50mmHg lower than usual (with a flared tip, I use 500 instead of 550mmHg,

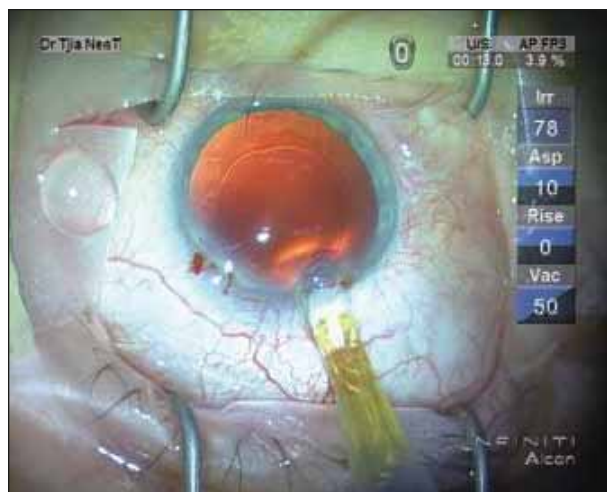


Figure 1. The author holds the tip of the C cartridge firmly against the incision's opening. The tunnel serves as an extension of the cartridge. In this way, the cartridge's plastic walls do not take up space within the incision, and smaller incisions are possible.

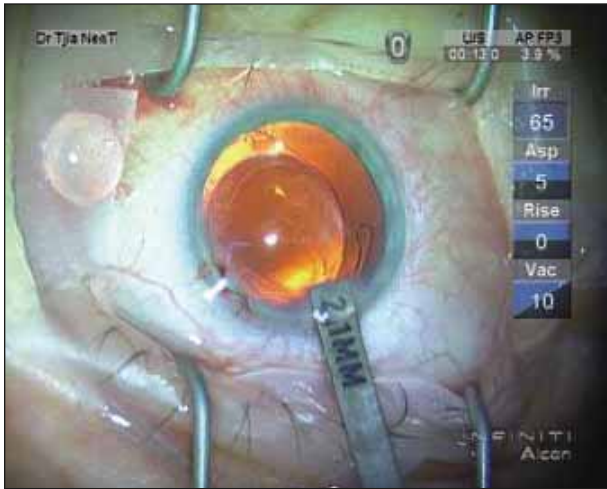


Figure 2. At the conclusion of surgery, a 2.1-mm caliper could just pass through the incision. The next size caliper, 2.2mm, could not. The author implanted a 20.50D AcrySof SN60 IOL with a 6-mm optic.

with a tapered tip, I use 400 instead of 450mmHg). My aspiration flow rate is 30 instead of 45mL/min with a flared phaco tip and 25 instead of 45mL/min with a tapered tip. Next, I perform bimanual I/A with thin-walled cannulas (Duckworth & Kent, Ltd., Hertfordshire, England).

I implant the IOL under Provisc ophthalmic viscosurgical device (Alcon Laboratories, Inc.) and use the Grieshaber loading forceps (Alcon Laboratories, Inc.) for the Monarch II C cartridge. I hold the Monarch II injector, with its well-positioned cartridge tip, in alignment with and parallel to the incision plane and tightly against the wound (Figure 1). At the end of the case, the incision was 2.1mm (Figure 2) and watertight (Figure 3).

EXPERIENCE

I have treated approximately 25 patients with this microincisional coaxial technique and have achieved excellent outcomes. I have had 100% watertight incisions, even with posterior wound-lip pressure. I do not hydrate the stroma of the main incision, but I do hydrate the

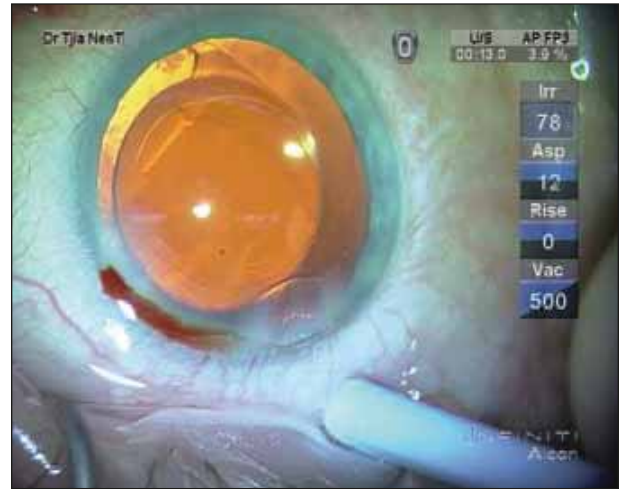


Figure 3. The author constructed the original wound as a traditional three-step incision. After he injected the IOL with this wound-assisted method (without stromal hydration), the wound was completely watertight. Even applying point pressure posterior to the incision produced no wound leakage.

small sideport incisions, which stretch with my manipulation of the bimanual I/A cannula.

The highlight of this technique is having an integrated phacoemulsification system that includes the superior fluidics of the Infiniti Vision System (Alcon Laboratories, Inc.) (due to its minimal compliance of the cassette and tubing), the innovation of the phaco tip and Ultra sleeve, a reliable injection system with the Monarch II, and a proven, high-quality IOL such as the single-piece AcrySof. In addition, Alcon's ongoing process of further innovation will undoubtedly lead to even higher-quality IOL injection through uncompromised, true, sub-2-mm phaco incisions. ■

Khiun Tjia, MD, is an anterior segment specialist in the Department of Ophthalmology at the Isala Clinics in Zwolle, the Netherlands. He is a paid consultant for Alcon Laboratories, Inc., but states that he holds no financial interest in any of the company's products. Dr. Tjia may be reached at +31 38 424 29 80; k.tjia@isala.nl.

