

# Sizing the Visian ICL

Accurate biometry with the Artemis VHF ultrasound may be the best way to size and evaluate the placement of the phakic collamer IOL.

BY PHILIP C. ROHOLT, MD

**T**he Visian Implantable Collamer Lens (ICL; STAAR Surgical Company, Monrovia, CA) was recently introduced as a treatment for high myopia. The Verisyse phakic IOL (Advanced Medical Optics, Inc., Santa Ana, CA) has a long track record with excellent results. Because a 6-mm incision is required for its implantation, however, visual recovery is slow, and astigmatic control is an issue.<sup>1,2</sup> The Visian ICL's advantages include relatively simple insertion and rapid visual recovery.<sup>3</sup> There were issues with the sizing of the Visian ICL from the very beginning, however, because the anatomic structures behind the iris are not easily observed. The FDA approval study<sup>4</sup> utilized the external, limbal, white-to-white measurement to estimate the appropriate length of the lens implant. Questions remain, however, as to the accuracy of this technique for sizing the ICL.

The Artemis VHF digital ultrasound arc scanner (Ultralink LLC, St. Petersburg, FL) may be the best current modality for obtaining accurate measurements of the anterior segment for the management of myopes requiring correction with a phakic lens. The Artemis is a relative of the older-style ultrasound biomicroscopy (UBM), which had no fixation device and required image reconstruction to produce a complete horizontal illustration, characteristics resulting in inaccurate measurements. Other current models of VHF ultrasound, such as the Quantel Lin50 (Quantel Medical, Bozeman, MT) or Sonomed Vumax UBM (Sonomed Inc, Lake Success, NY) cannot give the same information as the Artemis, because they do not have a fixation device to ensure reliable measurements. The biologic nature of the Visian ICL's soft collamer material lends itself to ultrasonic imaging, whereas the PMMA of the Verisyse IOL causes reflections.

This article focuses on the Visian ICL and the use of the Artemis for proper lens fitting.

## CLINICAL RESULTS WITH PHAKIC IOLS

The Verisyse phakic IOL was the first of its kind to be approved by the FDA. This lens provides excellent visual results but has some limitations, as mentioned earlier.

The Visian ICL was approved in 2005. According to recent

“The Artemis uses high-frequency ultrasound to penetrate the iris and visualize the sulcus and anterior crystalline lens.”

reports, 83% of patients achieve a UCVA of 20/20 or better.<sup>4</sup> In my clinical practice, no patients receiving the lens have lost BCVA. Compared with the Verisyse, the Visian ICL's insertion is easier, and my patients usually request surgery on their fellow eye immediately after the lens' implantation.

## WHITE-TO-WHITE MEASUREMENTS AND ADVANCED TECHNOLOGY

Because the haptics of the Visian ICL rest in the ciliary sulcus, it is desirable to obtain a direct measurement of the sulcus-to-sulcus dimension. Investigators<sup>5,6</sup> have used UBM to study the older, version 2 model of the Visian ICL. They noted the ICL's contact with the crystalline lens in 72.2% of cases as well as the lens' mobility and the variable placement of its haptics. This particular model was sized using the conventional method of obtaining the sulcus' width (ie, estimating the external, limbal, white-to-white measurement plus 0.5 mm).

A correlation between the external white-to-white measurement and the dimensions of the sulcus was not supported by a clinical study using UBM.<sup>7</sup> The problem with the UBM device is the inaccuracy of the horizontal measurement. A study of cadaveric eyes also failed to find a relationship between the white-to-white and sulcus-to-sulcus measurements.<sup>8</sup>

I believe, however, that direct measurements of eye-banked eyes are inaccurate because the globe is no longer intact. Thus, the white-to-white measurement was adequate in most cases and is the method recommended by the manufacturer. In the FDA study of the current V4 ICL, 3.1% of the 526 eyes required repositioning, replacement, or removal of the ICL.<sup>9</sup> Excessive vaulting resulting in the lens' explantation is still being investigated.

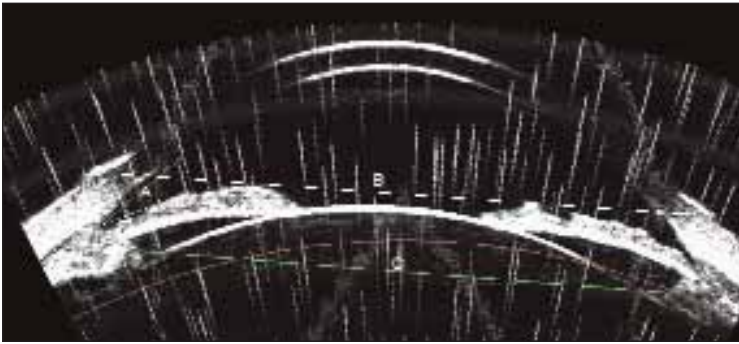


Figure 1. This preoperative image with the Artemis shows the anterior chamber angle at  $27.4^\circ$  (A), a white-to-white measurement of 12.2 mm (B), and a sulcus-to-sulcus measurement of 10.79 mm (C). The Visian ICL selected for this patient was 12.6 mm.




Figure 2. Postoperatively, the patient's anterior chamber angle was  $27.1^\circ$  (A). The arrow points at the anterior edge of the Visian ICL's haptic (B) and the increased sulcus-to-sulcus length of 11.28 mm (C), with the nasal haptic in the ciliary space and the temporal haptic's tip compressed into the ciliary body.

Other diagnostic modalities that better define anterior ocular structures are a new option for the proper fitting of lens implants. Optical coherence tomography (Visante OCT; Carl Zeiss Meditec, Inc., Dublin, CA) can obtain an optical cross-sectional image of the anterior segment, but measurements are limited in depth because of the iris' pigmentation. Thus, the critical sulcus-to-sulcus dimension cannot be observed.

The Artemis uses high-frequency ultrasound to penetrate the iris and visualize the sulcus and anterior crystalline lens. The device has been shown to measure the sulcus-to-sulcus dimension with high accuracy, repeatability, and reproducibility.<sup>10</sup> These qualities depend upon the patented fixation device embedded within the water bath of the instrument. Although my numbers are small, analysis illustrates a weak relationship between the white-to-white and the sulcus-to-sulcus measurements. For instance, longer white-to-white measurements are associated with longer sulcus-to-sulcus measurements (Figure 1).

When I use the Visian ICL, I add 2 mm to the length of the sulcus-to-sulcus measurement. This gives a length that most closely approximates the lens that would be chosen using the white-to-white measurement of the Orbscan (Bausch & Lomb, Rochester, NY). If there is a discrepancy, I place greater reliance on the Artemis measurements because they are a direct measurement of the sulcus' width.

### VIEWING THE ICL'S HAPTICS AND EFFECT ON ACCOMMODATION

A complete view of the Visian ICL's haptics in position in the ciliary sulcus is compromised by ultrasonic reflection from the surrounding ciliary tissue. The haptics compress the ciliary tissue, causing a widening of the ciliary sulcus' measurement compared to the preoperative width (Figure 2). Sometimes, the haptics are folded slightly against the ciliary body near the ciliary space.

Although 72% to 89% of haptics were located in the theoretical sulcus in the UBM studies,<sup>5,11</sup> the haptics of the Visian ICL in my patients are not always noted to project upward into this space immediately beneath the iris. Instead the haptics' tips more often rest adjacent to the zonules and press into the ciliary body. This positioning is most likely due to the posterior direction of the more highly vaulted V4

Visian ICL. According to recent reports,<sup>4</sup> an impairment of accommodation occurred after the implantation of the V4 Visian ICL. It is likely that the observed contact between the lens and the ciliary body and zonules inhibits the accommodative response.

### ANTERIOR CHAMBER ANGLE AND THE VISIAN ICL

The vaulting of the Visian ICL results in its contact with the posterior iris about 2 to 3 mm away from the ciliary body. This contact, coupled with the compression of the ciliary body, causes a narrowing of the anterior chamber angle. The mean preoperative anterior chamber angle was  $35.19^\circ$  (2.31 standard deviation), and, postoperatively, it was reduced to  $26.43^\circ$  (3.56 standard deviation). It is not yet known if this change has clinical implications in regard to angle closure with the age-related enlargement of the crystalline lens.

## SURGERY WITH THE VISIAN ICL

### Preoperative Evaluation

I offer myopic patients who are not candidates for LASIK the option of having a phakic lens implant. The preoperative examination includes a complete ocular evaluation with manifest and cycloplegic refractions, Orbscan topography, manual white-to-white measurements, an endothelial cell count, and Artemis UBM. After my analysis of the Artemis images, I select the most appropriate IOL, either the Verisyse phakic IOL or the Visian ICL. The anterior chamber depth must be 2.8 mm for the Visian ICL and 3.0 mm for the Verisyse phakic IOL (estimated corneal clearance can be obtained for the Verisyse by inserting an image of the lens). A contraindication for the Verisyse is a midperipheral bulge of the iris. For the Visian ICL, contraindications are an anterior chamber angle of less than 25° or an iris cyst in the proposed location of the haptics.

### Implantation

The Visian ICL is implanted with the patient under topical anesthesia with light sedation after the pupil is adequately dilated. The ICL is loaded into the cartridge. Paracenteses are made at the 12- and 6-o'clock positions, and 0.1 mL of nonpreserved intracameral lidocaine 1% is instilled. Next, the surgeon creates a 3-mm incision and injects Occucoat viscoelastic (Bausch & Lomb) into the anterior chamber. The lens is gently inserted into the anterior chamber, and the haptics are tucked into the sulcus from the superior paracentesis. Then, the ICL is gently nudged from side to side to ensure centration and equal compression against the ciliary body. Next, the Occucoat is gently irrigated away with a 25-gauge cannula via a bimanual technique to maintain the anterior chamber depth.

### Postoperative Regimen

I instruct the patient to return to my office 1 to 2 hours after the procedure for a check of his IOP. I provide patients with a Diamox sequel (Duramed Pharmaceuticals, Inc., Cincinnati, OH) to take 3 hours after surgery, and he is seen the following morning. Repeat UBM with the Artemis is performed at the 3-month postoperative visit.

## RESULTS WITH THE VISIAN ICL

So far, I have evaluated 19 implanted Visian ICLs using the Artemis. All of my patients who have received the lens are happy with their visual results. The mean preoperative refraction is  $-9.68 \pm 1.62$  D (spherical equivalent is  $-6.00$  to  $-14.50$  D). Postoperatively, the mean spherical equivalent refraction is  $-0.32$  D  $\pm 0.45$  D. I per-

formed limbal relaxing incisions 4 weeks after surgery on patients with astigmatism of greater than 1.00 D if they desired. After limbal relaxing incisions enhancements on both eyes of each patient, 78.9% (15 patients) achieved 20/20 UCVA, and all of them achieved 20/40 UCVA or better. No patient lost BCVA, and 26.3% (five patients) gained one or more lines of BCVA. The vault measured between 187 and 349  $\mu\text{m}$  (mean, 287.8  $\mu\text{m}$ ). No Visian ICL had to be exchanged due to an incorrect size or excessive vaulting.

## CONCLUSION

Accurate sizing of the Visian ICL is paramount to its successful implantation. A properly fit ICL yields several benefits: an adequate vault and improved aqueous circulation around the crystalline lens; maintenance of an adequate anterior chamber angle; stable refractive results; and a presumably lower compressive force against the ciliary body and zonules. I believe the Artemis VHF UBM allows improved visualization of the sulcus' anatomy to yield improved results with the Visian ICL. ■

*Philip C. Roholt, MD, is director of Ophthalmic Surgery, Roholt Vision Institute in North Canton, Ohio. He acknowledged no financial interest in the products or companies mentioned herein. Dr. Roholt may be reached at (330) 305-2200; proho12@yahoo.com.*

- Landesz M, Worst JG, Siertsema JV, van Rijn G. Correction of high myopia with the Worst myopia claw intraocular lens. *J Refract Surg.* 1995;11:16-25.
- Landesz M, Worst JG, Siertsema JV. Long term results of correction of high myopia with an iris claw phakic intraocular lens. *J Refract Surg.* 2000;16:310-316.
- US Food and Drug Administration; Visian ICL (Implantable Collamer Lens) - P030016. Available at: <http://www.fda.gov/cdrh/pdf3/p030016c.pdf>. Accessed April 23, 2007.
- Tanzer DJ. US FDA clinical trial of the toric implantable collamer lens for moderate to high myopic astigmatism. Paper presented at: The AAO Annual Meeting; November 10, 2006; Las Vegas, NV.
- Garcia-Feijoo J, Alfaro IJ, Cuina-Sardina R, et al. Ultrasound biomicroscopy examination of posterior chamber phakic intraocular lens position. *Ophthalmology.* 2003;110:163-172.
- Pitault G, Leboeuf C, Leroux L, et al. Ultrasound biomicroscopy of posterior chamber phakic intraocular lenses: a comparative study between ICL and PRL models. *J Fr Ophthalmol.* 2005;28:914-923.
- Pop M, Payette Y, Mansour M. Predicting sulcus size using ocular measurements. *J Cataract Refract Surg.* 2001;27:1033-1038.
- Werner L, Izak AM, Pandey SK, et al. Correlation between different measurements within the eye relative to phakic intraocular lens implantation. *J Cataract Refract Surg.* 2004;30:1982-1988.
- US Food and Drug Administration; Visian ICL (Implantable Collamer Lens) - P030016. Available at: <http://www.fda.gov/cdrh/pdf3/p030016b.pdf>. Accessed April 23, 2007.
- Reinstein DZ, Archer TJ, Dip CS, et al. Accuracy, repeatability and reproducibility of Artemis very high-frequency digital ultrasound arc-scan lateral dimension measurements. *J Cataract Refract Surg.* 2006;32:1799-1802.
- Trindade F, Pereira F, Cronemberger S. Ultrasound biomicroscopic imaging of posterior chamber phakic intraocular lens. *J Refract Surg.* 1998;14:497-503.