

Vitreous Loss

Pearls on anterior vitrectomy for cataract surgeons.

By Brad Feldman, MD, and Terry Kim, MD



With up to 6% of cataract surgeries complicated by vitreous loss,¹ anterior vitrectomy is an essential skill of today's cataract surgeon. Although the incidence of this complication is predictably higher in patients with complex cataracts due to pseudoexfoliation, intraoperative floppy iris syndrome, or posterior polar or dense cataracts, vitreous loss can occur unexpectedly in any case.



To decrease their anxiety and improve their outcomes, all surgeons should be well prepared to recognize and appropriately manage vitreous prolapse.

RECOGNIZING POSTERIOR CAPSULAR RUPTURE

The key to limiting the amount of vitreous prolapse is to quickly recognize when the posterior capsule has ruptured. Posterior capsular rupture most commonly occurs during emulsification of the final nuclear fragments or during cortical aspiration. The initial sign of a broken capsule is often a sudden deepening of the anterior chamber with enlargement of the pupil as the remaining lenticular material shifts posteriorly toward the lower-pressured vitreous cavity. If they miss this early sign, surgeons may come to suspect a ruptured posterior capsule if they encounter:

- A brightened red reflex
- Movement of lenticular particles away from the phaco tip or decreased followability
- Difficulty aspirating lenticular particles
- Pupillary distortion or peaking
- Directly visualized vitreous strands on an instrument's tip
- Visible lenticular particles in the vitreous

INITIAL STEPS

Upon recognizing a posterior capsular rupture, surgeons should immediately stop phacoemulsification and aspiration, but they should maintain the irrigation of balanced salt solution into the anterior chamber (foot pedal in position 1 or continuous irrigation mode) while injecting a dispersive viscoelastic through the sideport incision to fill the anterior chamber. The goal of this important maneuver is to maintain positive pressure in the anterior chamber in order to avoid the anterior prolapse of the vitreous. After completing this maneuver, surgeons may remove the phaco tip from the eye.²

Once they have stabilized the chamber, ophthalmologists may assess the size and extent of the rupture in order to plan their approach. Often, after a small tear, one can cautiously continue nuclear and cortical removal with low flow settings. Surgeons also need to determine the size and density of the remaining lenticular particles. If the rupture occurred early in the extraction of a dense lens, surgeons can consider enlarging the wound and converting to a manual extracapsular cataract extraction. If the lenticular particles can be prolapsed into the anterior chamber with viscoelastic or a second instrument, an option is to plug the capsule with a dispersive viscoelastic or cover it with a lens glide and then continue emulsification at low flow (20 mL/min), low pressure (20-mm Hg bottle height), moderate vacuum (120 to 200 mm Hg), and low phaco power (20% to 40%).³ If vitreous has already prolapsed into the anterior chamber, a vitrectomy must be performed prior to these techniques to avoid traction on the vitreous. If the lens has dropped posteriorly, a pars plana vitrectomy and lensectomy will be necessary, and an anterior approach should be avoided.

VITRECTOMY TECHNIQUE

The goals of an anterior vitrectomy are to remove vitreous from the wounds and anterior chamber, remove

lenticular particles, preserve as much capsule as possible, and allow for the placement of an IOL.

A bimanual technique is preferable to the traditional coaxial approach, because coaxial irrigation results in posteriorly directed flow that hydrates the vitreous, exacerbates the anterior prolapse of the vitreous, and potentially expands the capsular tear. To prepare for a bimanual vitrectomy, the surgeon can insert the vitrector's tip through the main phaco incision, depending on its size (ie, a standard 3-mm or larger incision may have to be partially sutured) and then insert a separate irrigation cannula through the sideport incision with a bottle height of 20 cm above the eye.

To minimize traction on the vitreous, the ophthalmologist performs the vitrectomy (if available, in cut I/A mode in which the guillotine-like cutter begins before vacuum builds) and sets the machine to a low aspiration flow rate of 18 to 20 mL/min, low vacuum of 100 mm Hg, and the maximum available cut rate (typically > 500 cuts/sec).⁴

The vitrector's tip should remain in place through the incision until all anterior chamber vitreous has been removed. The tip—which must be visualized at all times to avoid damaging the iris, ciliary body, retina, or capsule—is placed through the posterior capsular tear and kept in a central position as vitreous is removed to an extent just posterior to the capsule.

Soft nuclear fragments should be removed (by switching to I/A cut mode if available) with a slowed cutting rate (300 cuts/sec) to allow materials to be aspirated and molded into the instrument's tip before cutting. The surgeon can strip cortical material with the vitrector by switching to the I/A mode, but only after carefully removing all surrounding vitreous.⁴

COMPLETION

After removing vitreous and lenticular material, the surgeon instills acetylcholine chloride to check for pupillary peaking from vitreous strands. Ophthalmologists should use a cellulose sponge to check both the main and sideport incisions, and they should cut any vitreous manually with scissors. The IOL's placement is based on capsular and zonular integrity. At the conclusion of the case, all wounds that are not watertight should be sutured. Finally, surgeons should administer a subconjunctival antibiotic and corticosteroid (in addition to a longer and more intensive course of topical antibiotics, corticosteroids, and non-steroidal anti-inflammatory agents) to preemptively decrease the risk of further postoperative complications, including endophthalmitis and cystoid macular edema.

Brad Feldman, MD, is a fellow in cornea, external disease, and refractive surgery at the Duke University Eye Center in Durham, North Carolina. Dr. Feldman may be reached at (919) 684-6611; bradhfeldman@gmail.com.

Terry Kim, MD, is an associate professor of ophthalmology, cornea and refractive surgery, at the Duke University Eye Center in Durham, North Carolina. Dr. Kim may be reached at (919) 681-3568; terry.kim@duke.edu.

1. Vajpayee RB, Sharma N, Dada T, et al. Management of posterior capsular tears. *Surv Ophthalmol.* 2001;45(6):473-488.
2. Reeves SW, Kim T. Ophthalmic pearls: cataract. how to perform an anterior vitrectomy. *EyeNet Magazine.* April 2006. <http://www.aao.org/aaopublications/eyenet/200604/index.cfm>. Accessed March 20, 2009.
3. Buratto L. Phacoemulsification: Principles and Techniques. Thorofare, NJ: Slack Incorporated; 1998:211-262.
4. Waxman E. Capsular complications and management. In: Henderson BA, ed. *Essentials of Cataract Surgery.* Thorofare, NJ: Slack Incorporated; 2007:225-234.

Further Reading

Chang DF. Strategies for managing posterior capsular rupture. In: Chang DF, ed. *Phaco Chop: Mastering Techniques, Optimizing Technology, and Avoiding Complications.* Thorofare, NJ: Slack Incorporated; 2004:203-223.

A pars plana approach to vitrectomy for the anterior segment surgeon.

By Louis D. "Skip" Nichamin, MD



Arguably, the single most significant complication still faced by today's phaco surgeon is the rupture of the posterior capsule with subsequent vitreous loss.¹ Fortunately, in the setting of small-incision surgery, if the ophthalmologist adheres to certain fundamental principles and employs proper instrumentation and an appropriate surgical technique, then the vast majority of these complicated cases will have an outcome that differs little from that of an uncomplicated case.²

The key components of managing this condition include quickly recognizing the problem, avoiding hypotony, and maintaining a truly closed-chamber environment. All of this is predicated upon the use of watertight incisions, which permit a much lower rate and volume of infusion and thereby reduce intraocular turbulence. To further enhance control of the intraocular environment and reduce vitreoretinal traction, surgeons should use a separated or bimanual vitrectomy. In this way, the location and vector force of the infusion are displaced from the point where one is attempting to delicately remove vitreous. A reasonable approach is to place both instru-

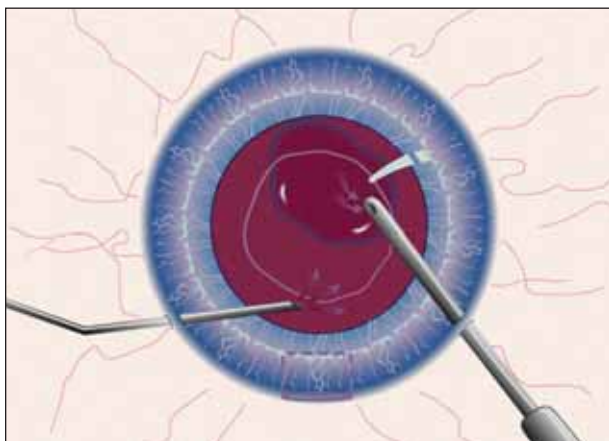


Figure 1. The surgeon performs a bimanual vitrectomy through limbal incisions. (Reprinted with permission from Slack Incorporated. Nichamin LD. Posterior capsule rupture and vitreous loss: advanced approaches. In: Chang DF, ed. *Phaco Chop: Mastering Techniques, Optimizing Technology, and Avoiding Complications*. Thorofare, NJ: Slack Incorporated; 2004.)

ments through limbal incisions (Figure 1).

I would submit that a much more efficient and potentially safer approach is to perform the vitrectomy through a pars plana incision (Figure 2).

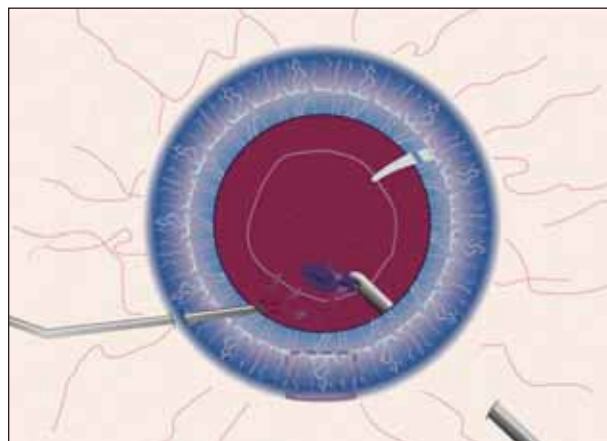


Figure 2. During bimanual vitrectomy, the surgeon places the vitreous cutter through the pars plana. (Reprinted with permission from Slack Incorporated. Nichamin LD. Posterior capsule rupture and vitreous loss: advanced approaches. In: Chang DF, ed. *Phaco Chop: Mastering Techniques, Optimizing Technology, and Avoiding Complications*. Thorofare, NJ: Slack Incorporated; 2004.)

ADVANTAGES

A pars plana vitrectomy allows the surgeon to “pull down” prolapsed vitreous from the anterior chamber,

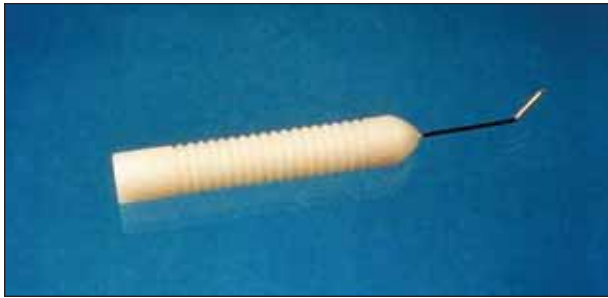


Figure 3. Nichamin A.C. Infusion Cannula No. E4421-S21. (Reprinted with permission from Slack Incorporated. Nichamin LD. Posterior capsule rupture and vitreous loss: advanced approaches. In: Chang DF, ed. *Phaco Chop: Mastering Techniques, Optimizing Technology, and Avoiding Complications*. Thorofare, NJ: Slack Incorporated; 2004.)

thus markedly reducing the amount of vitreous that is removed from the eye. When working from the limbus and bringing vitreous *up*, it is much more difficult to find an end point, and one often unintentionally removes a considerable portion of the vitreous body and must then deal with a hypotonus eye.

Another significant advantage to working through a pars plana incision is the enhanced access one has to residual lenticular material. The surgeon can remove cortex, epinucleus, and even medium-density nuclear material with the vitrector by gradually increasing vacuum and reducing the cutting rate. When addressing vitreous, the ophthalmologist uses the highest cutting rate with the lowest possible vacuum that will permit vitreous aspiration. This method achieves a more complete clean-up while reducing secondary complications such as increased IOP, inflammation, and cystoid macular edema.

TECHNIQUE

Care and effort must be directed toward the learning and acquisition of any new surgical technique, but in reality, the pars plana approach is quite straightforward. Typically, one first takes down the conjunctiva and applies light cautery at the site of the intended sclerotomy, although some surgeons will incise directly through the conjunctiva. The cardinal meridia should be avoided due to their increased vascularity. Given that the posterior capsule is open, the surgeon may place infusion through a limbal paracentesis incision or through a second pars plana incision. A useful infusion cannula for this technique is available from Storz (Bausch & Lomb, Rochester, NY) (Figure 3). Surgeons should select the clock hour of the vitrectomy incision to best access remaining lenticular material.

The pars plana is anatomically located between 3.0 and

4.0 mm posterior to the limbus, so the incision is most commonly placed 3.5 mm from the limbus, although an adjustment may be made for unusual axial lengths. Depending upon their preference, surgeons create incisions to accommodate either 19- or 20-gauge instruments. A dedicated disposable microvitrectomy blade should be used to create properly sized and therefore watertight incisions in both the pars plana and limbus. When creating the pars incision, the microvitrectomy blade is held perpendicular to the scleral surface and usually oriented in a limbal-parallel fashion. The surgeon directs the blade toward the center of the globe with a simple in-and-out motion.

As mentioned, when removing vitreous, surgeons should use the highest possible cutting rate and lowest possible vacuum setting. They can titrate up with vacuum and down on the cutting rate in order to remove remaining lenticular material. The goal is to preserve as much capsule as possible, especially the anterior capsular rim, in order to facilitate the implant's placement. Infusion should be minimal—just enough to maintain adequate IOP. The generous use of appropriate (often several different) viscoelastic agents will aid in maintaining intraocular volume and further decrease the need for infusion. A dispersive agent works best to tamponade the hyaloid face, and a more cohesive viscoelastic will best maintain space.

Surgeons should carefully clean and close the pars plana incision. The choices for suture closure include 9–0 nylon or 8–0 Vicryl (Ethicon Inc., Somerville, NJ). Recently, 25-gauge instrumentation has become available that, in some settings, may allow for sutureless surgery. The instruments' insertion, however, requires a firm globe. They can be used in a complicated setting if the surgeon first creates small incisions with a sharp blade as opposed to the usual trochar system. One downside is this instrumentation's lack of tensile rigidity and, therefore, its inability to manipulate the position of the globe.

CONCLUSION

Prudence dictates that surgeons not perform a pars plana vitrectomy for the first time while under duress during a live complication. Rather, they should first carefully study and practice the technique in a laboratory setting. The author firmly believes that, by adhering to the surgical principles described herein, surgeons may achieve a salutary outcome despite the posterior capsule's rupture.

Louis D. "Skip" Nichamin, MD, is the medical director of the Laurel Eye Clinic in Brookville, Pennsylvania. He acknowledged no financial interest in the products or com-

panies mentioned herein. Dr. Nichamin may be reached at (814) 849-8344; nichamin@laureleye.com.

1. Wu MC, Bhandari A. Managing broken capsule. *Curr Opin Ophthalmol.* 2008;19(1):36-40.
2. Nichamin LD. Posterior capsule rupture and vitreous loss: advanced approaches. In: Chang DF, ed. *Phaco Chop: Mastering Techniques, Optimizing Technology & Avoiding Complications.* Thorofare, NJ: Slack Incorporated; 2004:199-202.

Triamcinolone-assisted vitrectomy.

By Scott E. Burk, MD, PhD



Virtually invisible and always unwelcome, vitreous in the anterior segment makes surgery more difficult, and vitreous loss is associated with serious intraoperative and postoperative complications. Fortunately, meticulously

cleaning up vitreous can reduce the incidence of many vision-threatening complications associated with vitreous loss.¹ In a 2006 survey of attendees at the AAO Annual Meeting, over 80% of respondents had completed surgery only to find vitreous postoperatively at the slit lamp. This alarming statistic illustrates how difficult it is to adequately visualize vitreous in the anterior chamber under the operating microscope. Until recently, surgeons had to use indirect clues to look for vitreous gel in the anterior chamber.

By exploiting the propensity of vitreous to trap particulate matter, surgeons can make the invisible gel evident through the use of a triamcinolone acetonide suspension² and more thoroughly clean up vitreous.

LESSONS

The ability to visualize vitreous has allowed my colleagues and me to examine the behavior of the vitreous gel in an experimental setting.² A common misconception is that irrigating fluid in the presence of vitreous prolapse “hydrates” the vitreous, which results in more vitreous prolapse. In our study of cadaver eyes, irrigation in the anterior chamber did not increase the volume of vitreous or result in vitreous prolapse. When the triamcinolone suspension was injected directly within the substance of the vitreous gel, however, fluid pockets expanded to a degree directly related to the volume of irrigating fluid injected (Figure 1). The concept of *vitreous hydration* has probably been used to describe the direct inflation of fluid pockets in vitreous gel.

Injecting triamcinolone suspension directly into the substance of the vitreous gel greatly enhanced the dye's capture. We also found that, in a closed system, even strong posterior pressure did not send vitreous into the

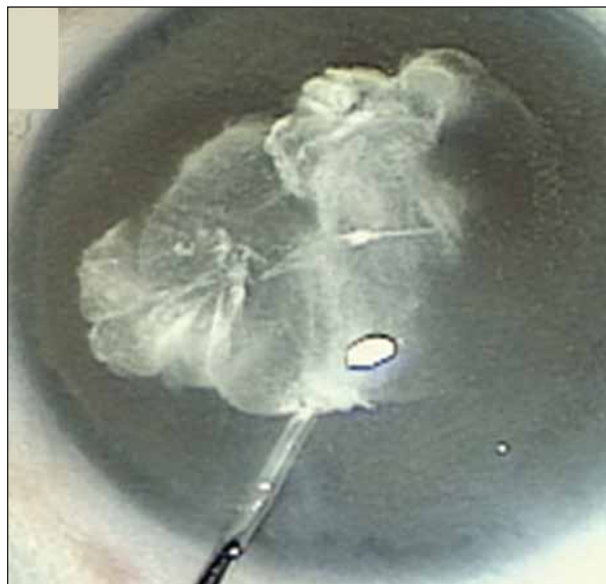

Figure 1. Injecting triamcinolone directly into the vitreous gel causes an expansion of fluid pockets.

anterior chamber. Posterior pressure did cause the vitreous gel to bulge forward, but in the absence of a wound leak, it rebounded to its original position when the pressure was relieved. The vitreous gel always moved from an area of higher pressure to an area of lower pressure. It streamed into the aspiration port of the I/A handpiece as soon as the aspiration was applied. Furthermore, if the vitreous were at or near an incision site, any fluid leak provided a pressure gradient that resulted in further vitreous prolapse and entrapment in the wound.

PREPARATION

To remove the benzyl alcohol preservative, my colleagues and I have been purifying triamcinolone for clinical use by a sterile capture-and-wash technique, which is a bit tedious. Briefly, 0.2 mL of Kenalog-40 (Bristol-Myers Squibb Co., Princeton, NJ) is drawn up into a tuberculin syringe and expressed into a 5- μ m filter, which captures the triamcinolone particles. We then rinse and resuspend the triamcinolone with balanced salt solution. The final resuspension volume is 2 mL, yielding an approximate concentration of 4 mg/mL.

Some surgeons dilute Kenalog-40 1:10 with balanced salt solution. This is the fastest and easiest technique, but the final product will contain 0.01% benzyl alcohol preservative. Another alternative is a sedimentation-resuspension-dilution technique. In its most conceptually simple form, a vial of Kenalog-40 sits undisturbed in the OR. When triamcinolone is needed, the supernatant is drawn off, replaced with an equal volume of balanced salt solution, and mixed thoroughly by shaking the vial. The desired amount of tri-

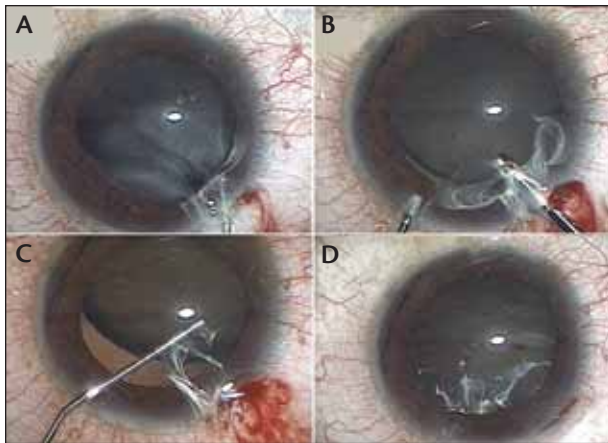


Figure 2. Sequential images in an eye with a traumatic cataract, zonular dialysis, and vitreous prolapse demonstrate the use of triamcinolone suspension for visualizing the location of vitreous and assisting vitrectomy. Triamcinolone is injected into the anterior chamber (A). The vitreous gel is visible during the anterior vitrectomy (B). Residual vitreous is trapped at the wound after the anterior vitrectomy (C). The surgeon removes residual vitreous from the anterior chamber by a limited pars plana vitrectomy (D).

amcinolone is typically then diluted 1:10 in balanced salt solution. Assuming supernatant removal of 90%, the final product will contain 0.001% benzyl alcohol. A third option is to purchase preservative-free triamcinolone from a compounding pharmacy. Finally, preservative-free triamcinolone is available in a sterile single-use vial as Triescence (Alcon Laboratories, Inc., Fort Worth, TX).

Triescence is approved and marketed for ocular inflammation and vitreous visualization. Presumably because of its dual indication, Triescence is supplied at 40 mg/mL, a concentration not ideally suited for visualizing vitreous. I prefer 10x dilution. I draw up 0.2 mL of Triescence into a 3-mL syringe containing 1.8 mL of sterile balanced salt solution. I find that concentrations much higher than 4 mg/mL tend to leave excess unbound triamcinolone in the anterior chamber, whereas a larger volume with a lower concentration of triamcinolone tends to distribute the particles more evenly.

TECHNIQUE

I prefer to inject the triamcinolone directly within the substance of the vitreous to obtain maximum visualization. Dusting the surface of the gel works but only until the surgeon has removed the surface, at which point reinjection is necessary. I like to swirl a little triamcinolone around the chamber to get an overview of the situation. Then, I bury the cannula's tip within the vitreous gel and deliver a controlled injection into the gel. It

is important to realize, however, that vitreous located near the wound will come out along with fluid during the injection. Thus, it is often helpful to insert the cannula through a distant paracentesis to avoid such reflux.

I perform the vitrectomy with a high cutting rate, low aspiration settings, and separate irrigation. Although not always necessary, a pars plana approach can be quite helpful, particularly for vitreous at the site of the corneal incision (Figure 2). Finally, all eyes that undergo a vitrectomy require a dilated peripheral fundus examination in the early postoperative period to identify retinal tears.

UNRESOLVED QUESTIONS

Triamcinolone is an invaluable tool for visualizing vitreous in the anterior chamber and has become a routine part of my practice for complicated cataract cases, especially in eyes with large or traumatic zonular dialyses. Two matters, however, remain unresolved.

The use of preservative-free or washed triamcinolone makes intuitive sense, but it is not clear that removing the benzyl alcohol preservative is necessary. The most recent study comparing preserved versus resuspended triamcinolone in a rabbit model found no difference in corneal thickness, endothelial cell count, or the endothelial cells' viability. The only difference was fewer microvilli on the endothelial cells that received preserved triamcinolone.³ The significance of this finding remains unknown.

Although glaucoma has been cited as a reason not to use triamcinolone during anterior vitrectomy, my colleagues and I have not experienced this complication. Furthermore, the risk of steroid-induced glaucoma seems to be minimal, because we use only a small amount of triamcinolone and remove the majority of it along with the vitreous gel. ■

The author wishes to acknowledge his colleagues who made this work possible: Andrea P. Da Mata, MD, PhD; Robert H. Osher, MD; Michael E. Snyder, MD; and Robert J. Cionni, MD.

Scott E. Burk, MD, PhD, is a staff ophthalmologist at the Cincinnati Eye Institute and is volunteer faculty in the Department of Ophthalmology, University of Cincinnati College of Medicine. He acknowledged no financial interest in the products or companies mentioned herein. Dr. Burk may be reached at (513) 984-5133; sburk@cincinnatieye.com.

1. Spigelman AV, Lindstrom RL, Nichols BD, Lindquist TD. Visual results following vitreous loss and primary lens implantation. *J Cataract Refract Surg.* 1989;15:201-204.
2. Burk SE, Da Mata AP, Snyder ME, et al. Visualizing vitreous using Kenalog suspension. *J Cataract Refract Surg.* 2003;29:645-651.
3. Oh JY, Wee WR, Lee JH, Kim MK. Short-term effect of intracameral triamcinolone acetonide on corneal endothelium using the rabbit model [published online ahead of print June 2, 2006]. *Eye.*