Unsatisfactory Result With LASIK Monovision

BY ANTHONY KAMEEN, MD; DAVID SCHNEIDER, MD; AND MARK KONTOS, MD

CASE PRESENTATION

A 42-year-old female with an interest in monovision has a preoperative prescription of -4.50 D sphere for a BCVA of 20/20 OD and -2.00 -1.00 X 165 = 20/20 OS. The patient is right-handed and right-eye dominant, and she has excellent pachymetry and wavefront values (Figure 1).

The patient undergoes uneventful Visx CustomVue LASIK (Advanced Medical Optics, Inc., Santa Ana, CA) for distance in her right eye and conventional LASIK for monovision in her left eye. The flap for both procedures is created with the IntraLase FS laser (Advanced Medical Optics, Inc.).

Ten months postoperatively, the patient is unhappy and states that her night vision in particular is poor. Her right eye has a UCVA of 20/20-, and her left eye has a BCVA of 20/20 with a refraction of -1.50 D sphere. Figure 2 shows her post-operative wavefront measurement.

How would you manage or counsel this patient?

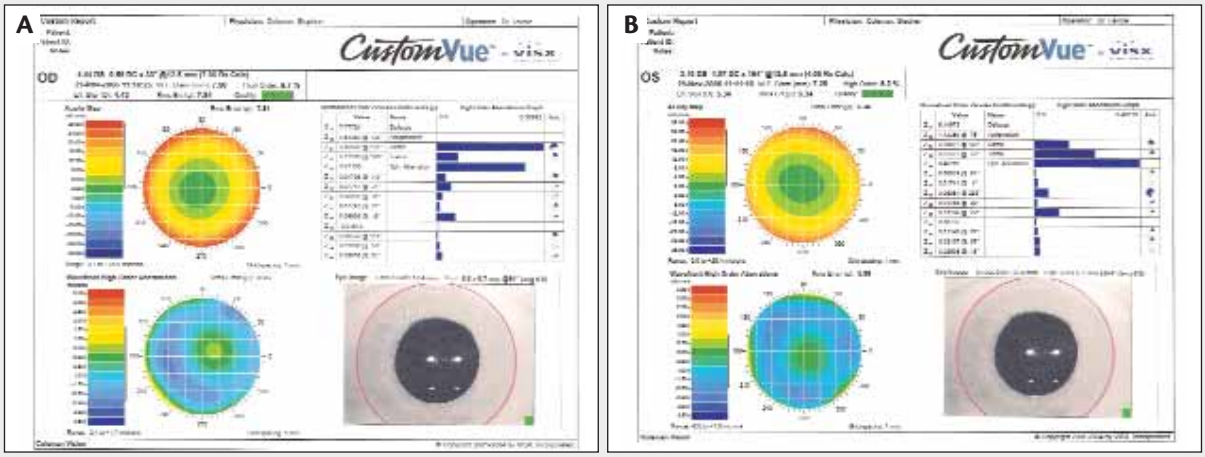

Figure 1. Preoperative wavefront analysis of the patient's right (A) and left (B) eyes.

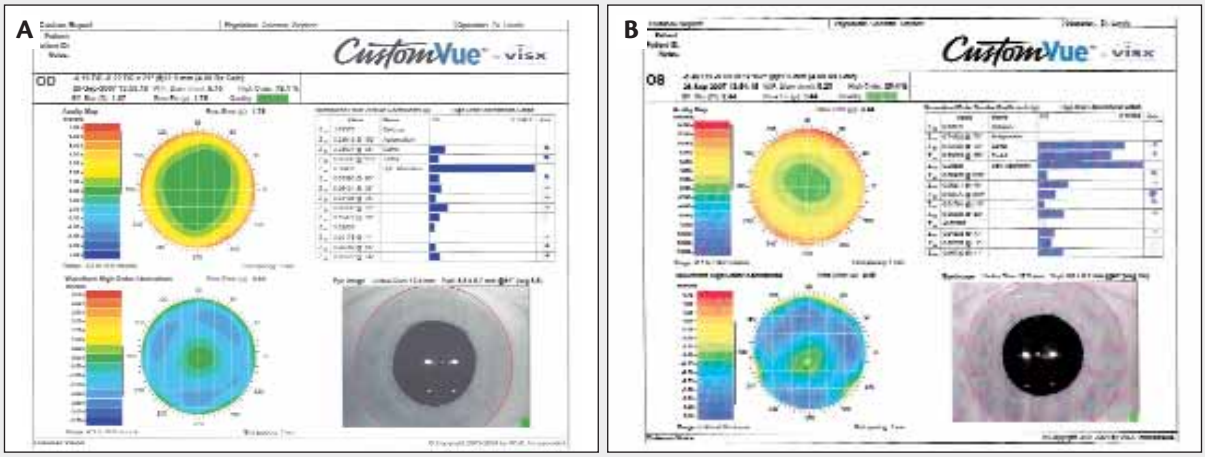

Figure 2. Wavefront analysis of the patient's right (A) and left (B) eyes 10 months after LASIK.

ANTHONY KAMEEN, MD

In retrospect, this patient was likely too young for a full monovision adjustment. A slight undercorrection of -0.75 D at most would have been more appropriate. The distance vision she sacrificed far exceeds the near-vision benefit she has realized. It is also my feeling that she is too young to be allowed to age into the near benefit. I doubt that she will ever be happy left the way she is. Although one could attempt to satisfy her with glasses for nighttime driving, the reality is that she underwent laser eye surgery to rid herself of glasses, not to get another pair. The same argument can be made when considering contact lens correction. These lenses would be quite useful, however, for determining if both eyes should be enhanced or just the patient's left eye.

> "Many monovision patients are classic examples of the postoperative traps into which all surgeons can fall."
> —Anthony Kameen, MD

In my experience, patients like this one are never totally happy until they have their distance "wow." I would proceed with a full-distance Visx CustomVue enhancement in her left eye only. It is likely that she will not need an enhancement of her right eye unless her personality dictates it. Of course, one can always re-treat the patient's right eye at a later time.

Many monovision patients are classic examples of the postoperative traps into which all surgeons can fall. Often, ophthalmologists are attempting to please someone in multiple areas and end up not pleasing them in any. One must never forget that the patient has the final vote on whether or not a procedure was successful.

DAVID SCHNEIDER, MD

I would first assure the patient that she has had an excellent result thus far and that some decreased nighttime vision and/or halos or glare at night often occur initially following monovision correction of this type. I am assuming that her poor nighttime vision is a result of the visual acuity in her left eye. Because she is only 42 years old, I am also assuming that she has never had a monovision correction prior to her LASIK surgery.

Initially, I would be very conservative in this case and would certainly try nighttime glasses as a starter with a plano correction in the patient's right eye and a full correction in her left eye. If this approach solved the problem, then I would either give the patient an appropriate contact lens for her left eye or encourage her to use the glasses as necessary, assuming that she is enjoying the monovision correction otherwise. This approach is safe and also buys some time until the Visx CustomVue monovision treatment option is available. I would not touch her right eye again unless it was clearly the source of her difficulties, and I would be surprised if that were the case.

Upon approval of the Visx CustomVue monovision treatment option, I would cut a PreVue lens for the patient to correct her astigmatism and whatever higher-order aberrations that the software might reduce. I have patients try this lens in the exam lane under nighttime-simulation conditions and also have them take the PreVue lens home to try when they are not driving. If she reported an improvement with the lens, then I would perform a Visx CustomVue monovision enhancement by lifting the original flap.

I am always hesitant to reverse a monovision correction, because, as a presbyope myself, I know how valuable monovision can be if one can overcome the initial difficulties. If all potential remedies failed, however, then laser reversal would be the appropriate solution.

MARK KONTOS, MD

This case illustrates the challenges with monovision surgery in patients who probably have little or no significant problems with their near vision prior to refractive surgery. Such individuals are often unhappy postoperatively and end up needing additional surgery if the initial procedure leaves them with less-than-perfect vision in their distance-dominant eye. Even after a retreatment, they may not be completely satisfied and may ultimately abandon monovision altogether.

For this patient, I would first determine if correcting the residual refractive error in her right eye with a temporary lens solved her complaint. If it did, then a customized enhancement of her right eye would be the next step. My guess is that this patient will still be dissatisfied with her nighttime vision. If so, she will need to understand that her options for improved nighttime vision are to wear glasses or a contact lens or to abandon monovision. If she wished to forgo monovision, I would proceed with a second surgery on her left eye with a goal of full distance correction. Because the patient's complaints relate to nighttime vision, I think customized surgery is the most logical choice. If all went well, the small residual refractive error and aberrations in the patient's right eye probably would not be of concern.

When I have encountered this situation prior to primary surgery, I have tried to persuade patients to choose full distance correction, because the need for

additional surgery is so common. Because monovision treatment with the Visx CustomVue software should soon be available, the outcomes in this group of patients may improve. Time will tell. ■

Section editor Karl G. Stonecipher, MD, is Director of Refractive Surgery at TLC in Greensboro, North Carolina. Parag A. Majmudar, MD, is Associate Professor, Cornea Service, Rush University Medical Center, Chicago Cornea Consultants, Ltd. Stephen Coleman, MD, is Director of Coleman Vision in Albuquerque, New Mexico. They may be reached at (505) 821-8880; stephen@colemanvision.com.

Anthony Kameen, MD, is Medical Director of Kameen Eye Associates in Baltimore. Dr. Kameen may be reached at (443) 695-4283; ajkameen@comcast.net.

Mark Kontos, MD, is in private practice with Empire Eye Physicians in Spokane, Washington. Dr. Kontos may be reached at (208) 772-2166; mark.kontos@empireeye.com.

David Schneider, MD, is an assistant clinical professor at the University of Cincinnati and is Director of the Midwest Eye Center in Cincinnati. Dr. Schneider may be reached at (513) 752-5700; drdms@aol.com.

SHARE THE COMPLEXITY

Do you have a complex case you would like to share for discussion in *Cataract & Refractive Surgery Today*? Please send refractive cases for consideration to Karl Stonecipher, MD, via e-mail at stonenc@aol.com and send cataract cases to Robert Cionni, MD, via e-mail at rcionni@cincinnatieye.com.