

# Sizing and Centering the Capsulorhexis

BY WILLIAM BOND, MD; BROCK K. BAKEWELL, MD;

AMAR AGARWAL, MS, FRCS, FRCOPHTH; AND DAVID SPALTON, FRCS, FRCP, FRCOPHTH

*Most surgeons have performed the capsulorhexis since its groundbreaking, simultaneous introduction in 1990 by Thomas Neuhann, MD, and Howard Gimbel, MD.<sup>1</sup> Now, as the use of aspheric and presbyopia-correcting IOLs becomes widespread, the sizing and centration of the capsulorhexis have never been more essential. Sufficiently sized for the intended IOL and adequately centered, the capsulorhexis is the framework for the production of a stable postoperative IOL/bag complex and the achievement of excellent postoperative vision.*

*How do surgeons optimize the capsulorhexis?*

—William J. Fishkind, MD, Section Editor

## WILLIAM BOND, MD

Over the years, I have favored a large capsulorhexis for better access to the lens proper, because I believe that the anterior capsule is part of the cataract. In the event of a posterior capsular rupture, there is virtually always enough anterior capsule to support a PCIOL in the sulcus, no matter how large the capsulorhexis was initially. Furthermore, it has been my experience that there are many more longitudinal tears in the anterior capsule in the course of the operation when a small capsulorhexis has been created. These tears greatly undermine the supportive strength available for a PCIOL should placement in the sulcus become necessary. Although it leaves less anterior capsule, a large capsulorhexis is much less likely to be associated with longitudinal tears, and the anterior capsule is thus a far more sturdy and reliable base for supporting a sulcus-fixed PCIOL.

I make a small central vent with a bent 30-gauge needle and grasp a flap of anterior capsule with a Utrata forceps fairly close to its edge. I try to tear parallel to the iris initially so as not to get too far out toward (or into) the zonules. The most frequent cause of a bad capsulotomy is a poor early start; too big or peripheral an initial tear with the needle or an overly enthusiastic early tear right after the initial grasp with the forceps easily puts the surgeon right out into, or even beyond, the zonules. In such cases, one can convert to a can-opener style 360° capsulotomy and abandon the capsulorhexis. My preference, however, is to pull the Utrata forceps straight back toward the center of the pupil while it is still holding the capsule in order to minimize the lateral extension of the possible zonular or posterior tear. When the

tear reappears, of course, I redirect it parallel to the iris and less peripherally.

The other common cause of extending a capsulorhexis too far is not to regrasp the tearing flap frequently enough. The tear will circumferentially expand as the edge gets farther from the forceps. This scenario seems elementary but can easily happen. A minimum of two regrabbings close to the tearing flap's edge, after the initial grab, is what I find easiest.

## BROCK K. BAKEWELL, MD

It is important to size the anterior capsulorhexis such that it overlaps the optic by 0.5 mm for 360° for a number of reasons. Doing so prevents an unintended myopic result due to anterior movement of the IOL, and it allows for an easy exchange of the IOL in the bag if the lens'

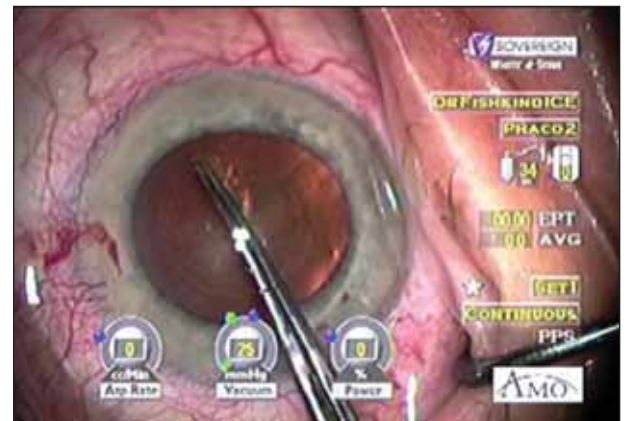
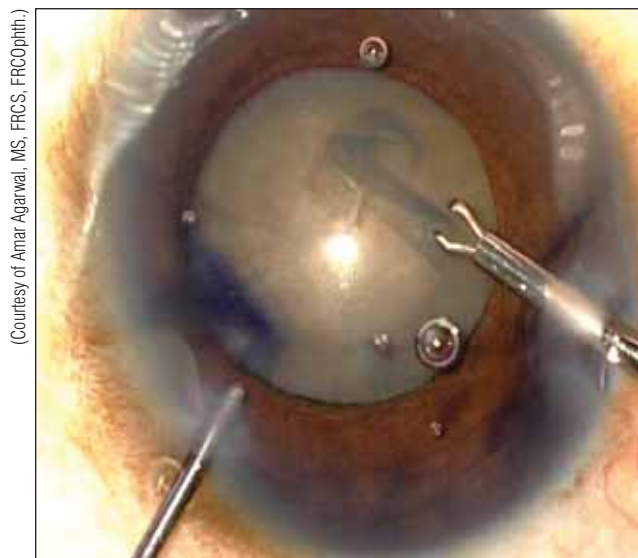


Figure 1. Etchings on the forceps help Dr. Bakewell to size the capsulorhexis accurately.

(Courtesy of Brock K. Bakewell, MD.)



(Courtesy of Amar Agarwal, MS, FRCS, FRCOphth.)

**Figure 2.** Professor Agarwal uses a microcapsulorhexis for- ceps (MicroSurgical Technology, Redmond, WA) to create the capsulorhexis during phakemulsification of an eye with a mature cataract. He has used trypan blue to stain the anterior capsule.

power is incorrect. In addition, if the capsulorhexis is relatively small, hydrodissection is more dangerous, and cataract surgery becomes more difficult, thereby increasing the chance of complications.

To precisely size the capsulorhexis, I use a modified Utrata forceps (Rhein Medical Inc., Tampa, FL) that has laser etchings 5 mm from the tips (Figure 1). They serve as an intraocular ruler that allows me to measure exactly 5 mm on the anterior capsule just before I start the tear. Because the capsule cannot be physically scored, it is necessary for the surgeon to make a mental note of how much space is between (1) the edge of the nasal pupil and the tips of the forceps and (2) the edge of the temporal pupil and the etchings. Also, it is important for the surgeon to remember that the capsulorhexis should be offset by about 0.5 mm nasally and 0.5 mm superiorly relative to the pupil, because a PCIOL usually centers slightly nasal and superior to the geometric center of the eye. The surgeon also must rotate the IOL to find the position of maximal overlap of the capsulorhexis' edge on the surface of the IOL. These strategies will help the surgeon precisely create the capsulorhexis and accurately center it on the IOL.

#### **AMAR AGARWAL, MS, FRCS, FRCO<sub>P</sub>H<sub>T</sub>H**

An appropriately sized, well-centered capsulorhexis is important for safe phacoemulsification and in-the-bag IOL placement. It also avoids the postoperative decentration of the IOL, especially in cases of capsular phimosis syndrome,

and it helps avoid dysphotopsia arising from the capsulorhexis' edge in cases of anterior capsular opacification. One may use a needle or forceps to ensure a well-centered capsulorhexis that is the right size for the chosen IOL. The only situation in which centration may not be possible is in the case of phacoemulsification in the presence of subluxated cataracts.<sup>2</sup>

The capsulorhexis should overlap the edge of the IOL's optic for 360°. This sizing helps to reduce posterior capsular opacification, particularly with PMMA lenses, by reducing the incidence of posterior capsular wrinkling.<sup>3</sup> The effect is less pronounced with the Acrysof single-piece lens (Alcon Laboratories, Inc., Fort Worth, TX), which prevents wrinkling even when the capsulorhexis is larger than the optic.<sup>4</sup>

The point when the surgeon is most likely to lose control of the tear is at the capsulorhexis' completion. It is therefore important to initiate the capsulorhexis from the center of the lens and to move the needle right and downward. If the tear ends on the left, every stroke of the phaco probe could produce a posterior extension of the capsulorhexis and ultimately cause a posterior capsular rupture. Terminating the capsulorhexis to the right will lower the risk of this complication. The opposite is true for a left-handed surgeon.

Visual cues can help the surgeon keep the tearing edge of the capsulorhexis parallel to the pupil and maintain a flap folded over itself. The first nick of the anterior capsular surface should be slightly smaller than the intended size of the capsulorhexis, because turning the flap will enlarge the tear somewhat. The alignment of the folded flap determines the direction and size that the capsulorhexis will take. Angling the flap outward will increase the size of the capsulorhexis, and angling it inward will have the opposite effect. For an eye with a mature or hypermature cataract, staining the anterior capsule with trypan blue (Figure 2) can help greatly.<sup>5</sup> The surgeon can enlarge a small pupil by injecting Healon 5 (Advanced Medical Optics, Inc., Santa Ana, CA) or by means of pupillary stretching techniques, pupil ring expanders, or iris hooks, as have been popularized by Samuel Masket, MD, and Luther Fry, MD.<sup>6-8</sup>

#### DAVID SPALTON, FRCS, FRCP, FRCO<sub>PHTH</sub>

Many studies show that a capsulorhexis that lies on the anterior surface of the IOL is associated with less posterior capsular opacification than if it is off the lens (Figure 3). A capsulorhexis on the implant may also reduce the amount of dysphotopic symptoms from the IOL's square edge. Ideally, one would like to have a capsulorhexis of approximately 5.50 to 5.75 mm in diameter that lies concentrically on an IOL with a 6-mm optic, but to achieve this consistently requires considerable surgical skill.

I believe that performing the same maneuver in the same

way on every case gives consistent results. I always operate with a clear corneal temporal incision under topical anesthesia using a hyaluronic acid viscoelastic. For complex cases, where there is going to be more intraocular manipulation, shallow anterior chambers, or small pupils, I like to use a soft shell technique with Viscoat (Alcon Laboratories, Inc.) and Healon (Advanced Medical Optics, Inc.).

I always use a Utrata forceps to make the capsulorhexis. With the closed forceps, I pierce the anterior capsule cleanly, just off-center from the visual axis so that the puncture is not obscured by the corneal light reflex from the microscope. After opening the forceps, I pick up the lateral margin of the puncture and tear the capsulorhexis counterclockwise. This step is important because it is most difficult to perform the capsulorhexis in the subincisional space, especially if disrupted or liquefied anterior lenticular cortex compromises visualization. It is therefore better to clear this area as soon as possible to ensure a good view.

I use the margin of the pupil as a guide for tearing the circle and have a mental picture of the diameter of the capsulorhexis that I want to achieve. Although I ideally target a 5.5-mm diameter, I tend to err on the conservative side, and, more often than not, my capsulorhexis is nearer to 5.0 than 5.5 mm. It is better to make the capsulorhexis smaller than larger, although too small increases the risk of postoperative phimosis. I usually regrip the capsulorhexis three or four times to complete the tear at the 12-o'clock position in the patient's right eye and the 6-o'clock position in his left eye. The use of VisionBlue (DORC International BV, Zuidland, the Netherlands) has transformed the management of mature white or dense brown cataracts, and it is always better to use the dye when adequate visualization is doubtful. ■

Section Editor William J. Fishkind, MD, is Codirector of Fishkind and Bakewell Eye Care and Surgery Center in Tucson, Arizona, and Clinical Professor of Ophthalmology at the University of Utah in Salt Lake City. He is a consultant for Advanced Medical Optics, Inc. Dr. Fishkind may be reached at (520) 293-6740; wfishkind@earthlink.net.



Amar Agarwal, MS, FRCS, FRCOphth, is Director of Dr. Agarwal's Group of Eye Hospitals in Chennai, India. He acknowledged no financial interest in the products or companies mentioned herein. Professor Agarwal may be reached at +91 44 28116233; dragarwal@vsnl.com.



Brock K. Bakewell, MD, is Codirector of Fishkind and Bakewell Eye Care and Surgery Center in Tucson, Arizona, and Clinical Assistant Professor at the University of Utah in Salt Lake City. He acknowledged no financial interest in the products or companies mentioned herein. Dr. Bakewell may be reached at (520) 293-6740; eyemanaz@aol.com.



William Bond, MD, is Medical Director of Bond Eye Associates in Pekin, Illinois. He acknowledged no financial interest in the products or companies mentioned herein. Dr. Bond may be reached at (309) 353-6660; bondeye@bondeye.com.

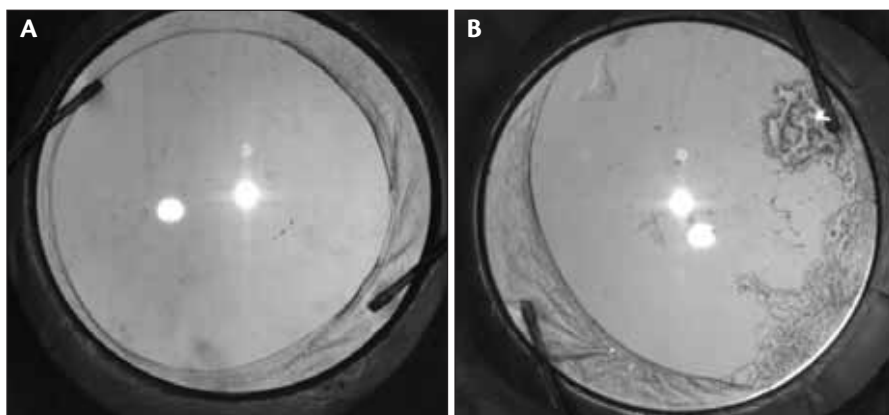


David Spalton, FRCS, FRCP, FRCOphth, is a consultant ophthalmic surgeon at St. Thomas' Hospital in London. He is a consultant to Alcon Laboratories, Inc. Mr. Spalton may be reached at +020 7935 6174; dspalton@hotmail.com.



1. Gimbel HV, Neuhann T. Development, advantages and methods of the continuous circular capsulorhexis technique. *J Cataract Refract Surg.* 1990;16:31-37.
2. Jacob S, Agarwal A, Agarwal A, et al. Efficacy of a capsular tension ring for phacoemulsification in eyes with zonular dialysis. *J Cataract Refract Surg.* 2003;29:315-321.
3. Hollick EJ, Spalton DJ, Meacock WR. The effect of capsulorhexis size on posterior capsular opacification: one-year results of a randomized prospective trial. *Am J Ophthalmol.* 1999;128:271-279.
4. Meacock WR, Spalton DJ, Hollick EJ, et al. The effect of polymethylmethacrylate and Acrysof intraocular lenses on the posterior capsule in patients with a large capsulorhexis. *Jpn J Ophthalmol.* 2001;45:348-354.
5. Jacob S, Agarwal A, Agarwal A, et al. Trypan blue as an adjunct for safe phacoemulsification in eyes with white cataract. *J Cataract Refract Surg.* 2002;28:1819-1825.
6. Agarwal S, Agarwal A, Agarwal A. *Phacoemulsification.* 2 vol. 3rd ed. Thorofare, NJ: Slack, Inc.; 2004.
7. Agarwal A, ed. *Handbook of Ophthalmology.* Thorofare, NJ: Slack, Inc.; 2005.
8. Agarwal A, ed. *Phaco Nightmares: Conquering Cataract Catastrophes.* Thorofare, NJ: Slack, Inc.; 2006.

(Courtesy of David Spalton, FRCS, FRCP, FRCOphth.)



**Figure 3.** The capsulorhexis should lie on the anterior IOL surface and press the IOL backward against the posterior capsule. Postoperative fibrosis will prevent posterior capsular opacification (A). Lens epithelial cells invade the posterior capsule where the capsulorhexis lies off the IOL's anterior surface (B).