

Corneoscleral Burn

BY LOUIS D. "SKIP" NICHAMIN, MD

Of the myriad intraoperative complications that I have encountered over 20 years of performing cataract surgery—including cases of vitreous incursion, dropped nuclei, detached Descemet's membrane, and iris disinsertions—one awful, terrifying case still blazes vividly in my mind. Despite its occurrence some 18 years ago, the case involved my first and only corneoscleral burn, arguably one of the worst such complications in the annals of phaco surgery.

Thermal wound damage has become a relatively rare complication, owing to improved fluidics, power modulations, and refined phaco techniques. Nevertheless, I believe that the potential for thermal burns is still an important consideration and that this complication may, in fact, be a significantly underreported event.¹ I hope that my story will help readers avoid this generally preventable problem.

CASE PRESENTATION

The patient was a retired schoolteacher who had been treated for years with 4% pilocarpine for glaucoma. At the time of his transfer to my care, the patient's BCVA was 20/40- OU, secondary to extremely brunescant cataracts.

As is typical of some elderly patients with nuclear cataracts, this gentleman was not particularly symptomatic visually, despite the Coca-Cola-colored brunescence of his lenses. Due to his latent hyperopia, long-term use of a strong miotic, and increasingly phacomorphic anatomy, it was obvious to me that his cataract surgery would be very challenging. As such, I beseeched him to consider undergoing implant surgery. After months of cajoling, he reluctantly acquiesced. He claimed that his decision was based solely upon his increasing IOP and glaucoma, which, due to the combined-mechanism disease, was in fact worsening.

The case was plagued from the start. The cataract incision was not shelved properly for the patient's short eye, leading to early iris prolapse and worsening of an already shallow chamber. Due to a lack of understanding on my part of viscoelastic properties, I switched from my usual cohesive agent and packed the chamber full of a dispersive ophthalmic viscosurgical device with the mistaken thought that this step would help create space. The opposite, of course, occurred.

The stage was now set. In order to avoid further collapse of the barely formed anterior chamber, I re-inserted the phaco probe without irrigation and then committed

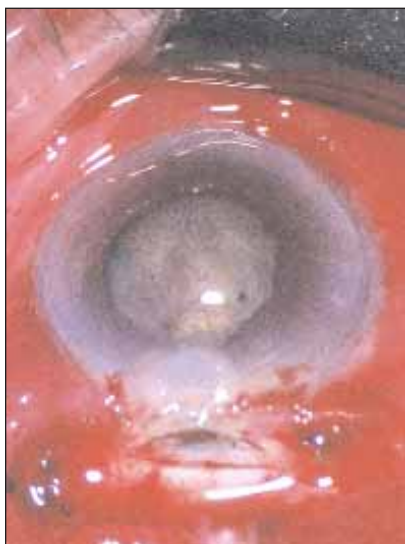

Figure 1. The immediate appearance of the wound following a corneoscleral burn.

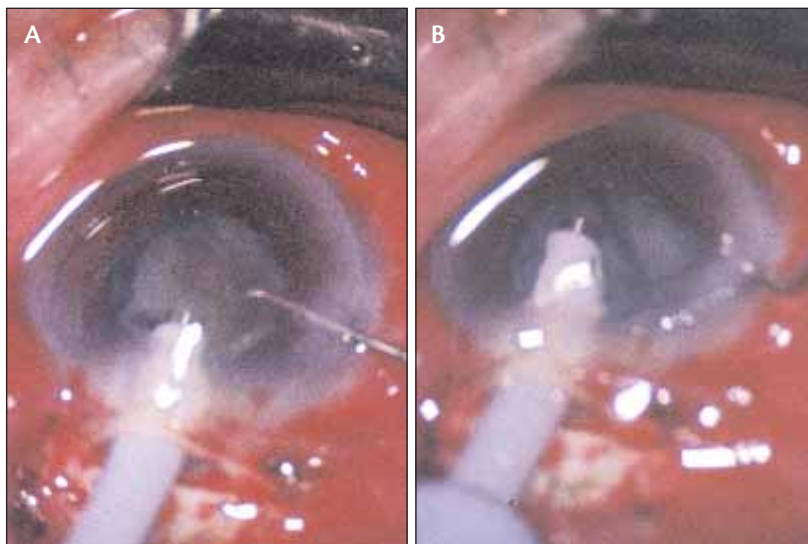


Figure 2. The author performed phacoemulsification using a divide-and-conquer technique (A, B).

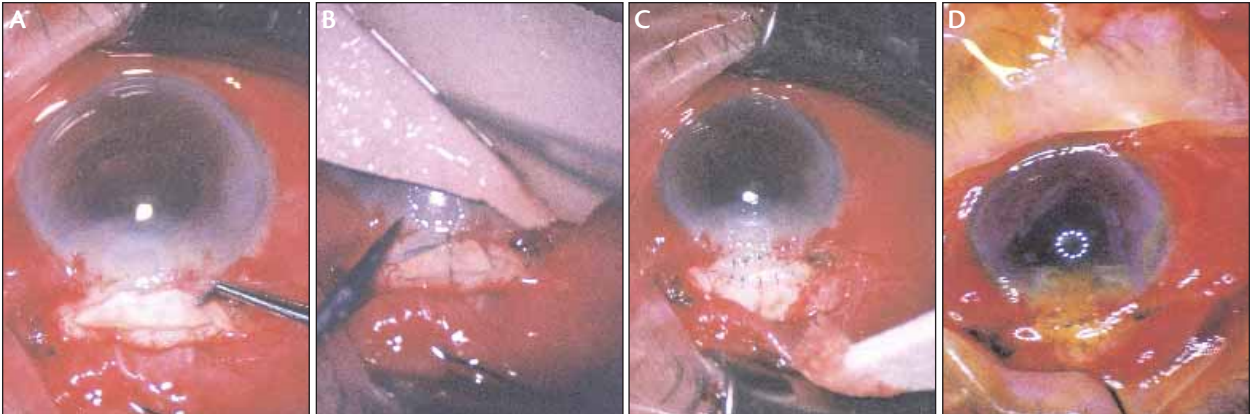


Figure 3. The author cut a scleral patch graft to a size and shape to fill the gaping wound defect (A). The initial placement of sutures (B) and the completed graft (C). Staining confirmed a watertight closure. Note the relatively round corneal mires (D).

the ultimate sin: I stepped down on the pedal and directly engaged position three without first establishing patency to the I/A system. Nearly instantly, an unforgettable searing burn of the scleral incision occurred. Upon the withdrawal of the phaco instrument, I was met with a huge, gaping incisional defect (Figure 1). In what seemed like a millisecond, after only a brief telltale puff of lens emulsate, a full-fledged phaco burn had occurred—just as described in the literature and aptly termed the *visco-plug syndrome*.^{2,3}

Following a wave of nausea and shock, I came to the inevitable conclusion that somehow surgery must continue. Numb, I completed the phacoemulsification and managed to implant a lens (Figure 2). I then had to deal with the gaping wound. Various options for closure exist to manage a situation like this one, including the placement of a horizontal mattress suture at the internal aspect of the tunnel's opening, which may leave the external aspect at least partially open. Conjunctival closure is then performed, perhaps resulting in an inadvertent conjunctival bleb. Given the extent of this particular defect, I had serious doubts as to whether I could close the wound in a primary fashion, even with the sturdiest of sutures. Fortunately, I had preserved sclera in the OR and tremulously managed to create a scleral patch graft to fill in the cavernous defect. Much to my amazement and extreme relief, this technique resulted in a watertight closure (Figure 3). The patient recovered remarkably well and, weeks later, had only minimal residual astigmatism—not atypical for thermally induced corneal cylinder.

PATHOPHYSIOLOGY OF A BURN

The etiology of a corneoscleral burn can generally be attributed either to a cessation of inflow or an obstruction of outflow. Causes of the former may

include an empty infusion bottle, crimping of the infusion tubing, or too tight an incision. Obstructed outflow may be secondary to lenticular material's blocking the handpiece, tubing, or cassette. As in this case, a viscoelastic plug may also contribute to obstruction.

Again, wound burns were more common with early generations of phaco equipment and techniques and, in my case, a rather bold use of viscoelastics without an appropriate understanding of their behavior. Fortunately, this dreaded complication has become less frequent due to surgeons' improved understanding of incisional dynamics, marked technological advances in the phaco handpiece, the development of protective sleeves, and perhaps most importantly, the use of sophisticated computer software and power modulations that greatly reduce emulsification energy. Today, advanced phaco technologies can even sense occlusion at the phaco tip and, in fractions of a second, automatically curtail the excessive use of power. Nonetheless, it is still important for cataract surgeons to fully comprehend the physics behind wound burns and, one hopes, therefore avoid their occurrence. ■

Section editor David F. Chang, MD, is a clinical professor at the University of California, San Francisco, and is in private practice in Los Altos, California. Dr. Chang may be reached at (650) 948-9123; dceye@earthlink.net.

Louis D. "Skip" Nichamin, MD, is the medical director of the Laurel Eye Clinic in Brookville, Pennsylvania. Dr. Nichamin may be reached at (814) 849-8344; nichamin@laureleye.com.



1. Bradley MJ, Olson RJ. A survey about phacoemulsification incision thermal contraction incidence and casual relationships. *Am J Ophthalmol*. 2006;141(1):222-224.
2. Emergency Care Research Institute. Scleral and corneal burns during phacoemulsification with viscoelastic materials. *Health Devices*. 1988;17:377-380.
3. Nichamin LD. Acute intraoperative suprachoroidal hemorrhage (letter). *J Cataract Refract Surg*. 1994;20(1):106-107; reply 107-108.