Vision Correction After Corneal Collagen Cross-linking

BY RENATO AMBRÓSIO JR, MD, PHD; MICHAEL W. BELIN, MD;
AND ERIK L. MERTENS, MD, FEBOPHTH

CASE PRESENTATION

A 26-year-old female law student presents to you with an inquiry about vision correction surgery.

Her UCVA measures 20/200 OD and 20/400 OS. Her manifest refraction is +0.50 -5.50 X 85 = 20/20 OD and -3.00 = 20/20 OS. Her cycloplegic refraction is +1.00 -5.00 X 70 = 20/20 OD and -3.00 = 20/20 OS.

The patient underwent corneal collagen cross-linking (CXL) in her right eye 18 months ago, and topography shows stability (Figures 1 and 2). She has not had any intervention in her left eye. The patient wears rigid gas permeable contact lenses but is growing intolerant in her right eye.

How would you counsel her regarding the surgical options for her right eye? Would you offer any intervention for her left eye?

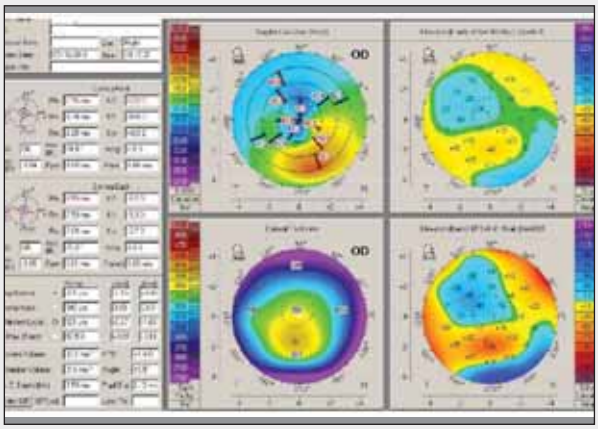

Figure 1. Imaging results for the patient's right eye with the Pentacam Comprehensive Eye Scanner.

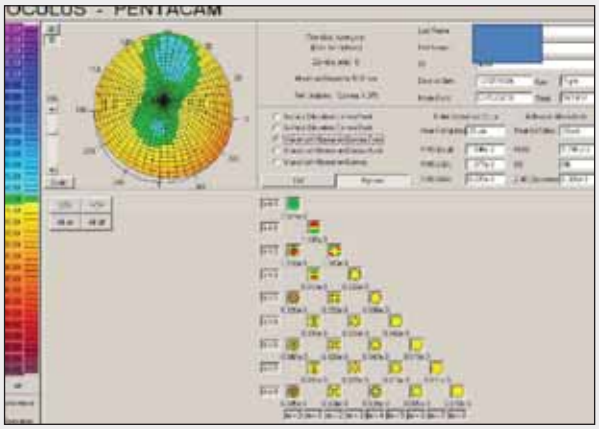

Figure 2. Zernike analysis (Pentacam) of the patient's right eye.

RENATO AMBRÓSIO JR, MD, PHD

The front curvature map displays highly asymmetric keratoconus with a claw-shaped pattern in the patient's right eye (Figure 3). This topographic pattern is also seen in pellucid marginal degeneration (PMD), but the corneal thickness and elevation maps in this case (Figure 4), along with the vertical Scheimpflug corneal image (Figure 5), are consistent with inferior keratoconus.[1] In true PMD, there is marked inferior thinning.[2] It is very important to differentiate keratoconus and PMD, something we can only achieve with proper tomographic analysis.

My approach to keratoconus is surgery if the patient is contact lens intolerant and unhappy with his or her spectacle-corrected visual acuity. I would also consider surgery to be indicated if there were documented ectatic progression, which is best confirmed with sequential examina-

(Figures 3–9 courtesy of Renato Ambrósio Jr, MD, PhD.)

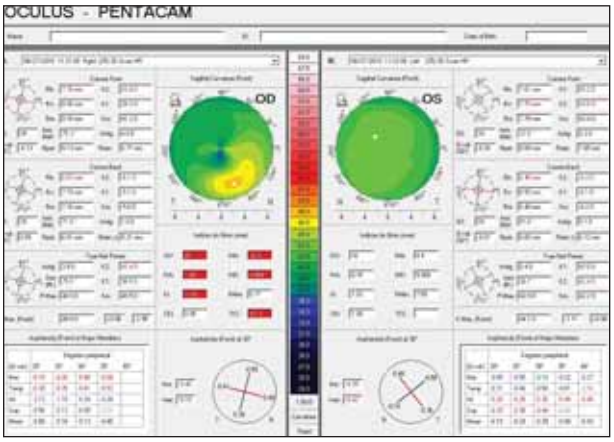

Figure 3. Sagittal or axial front curvature map (absolute Smolek-Klyce scale). (Figures 3 to 8 from the analysis of the u12 raw Pentacam data.)

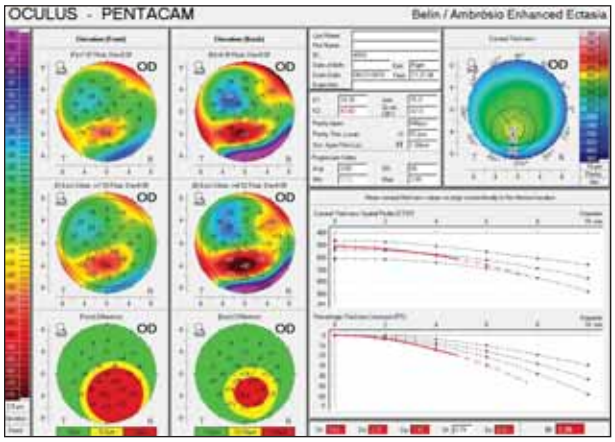

Figure 4. Belin/Ambrósio Enhanced Ectasia Display of the patient's right eye.

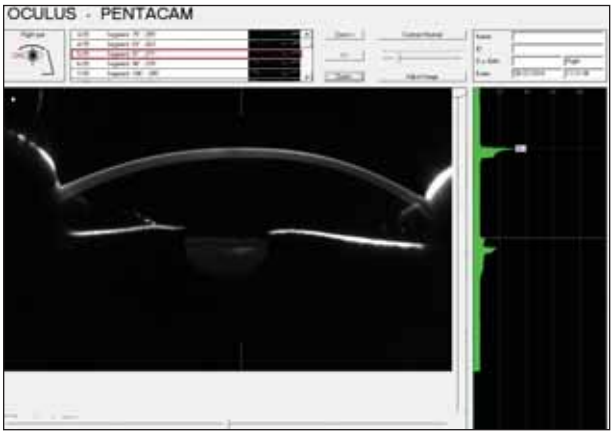

Figure 5. Scheimpflug image of the patient's right eye, with no peripheral thinning.

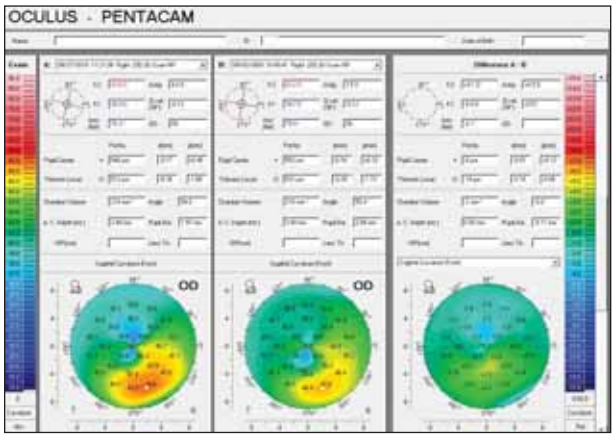

Figure 6. Sagittal front curvature maps of pre- and post-CXL and subtraction map for the patient's right eye.

tions but could be based on clinical history as well.

In this case, I would have performed femtosecond laser-assisted implantation of intrastromal corneal ring segments (ICRS) instead of CXL in the patient's right eye. The latter procedure aims to reduce ectatic progression but has a variable effect on corneal curvature. Indeed, it produced approximately 4.00 D of flattening over the cone in this eye (Figure 6). In my experience, however, ICRS would have produced a more significant improvement in the patient's astigmatism and visual performance.

Considering that the patient is unhappy with her glasses due to anisometropia and does not tolerate contact lenses, surgery is necessary. Because topographic stability has been documented, there are different options for surgically approaching her right eye. Although the implantation of ICRS produces a less pronounced improvement in keratoconus when *followed* by CXL,[3] I would still place ICRS in this case due to their reversibility and possible adjustment. I would place one SI5 Keraring (Mediphacos, Belo Horizonte, Brazil; not available in the United States), with 160º arc and 250 µm, inferiorly. Using the IntraLase iFS Femtosecond Laser System (Abbott Medical Optics Inc., Santa Ana, CA), I would make a temporal incision at 165º and a depth of 385 µm. A second option is customized advanced surface ablation, which is an attractive alternative due to this eye's corneal thickness and refraction, but the patient's age raises concern.[4] A third option would be a toric phakic IOL (not available in the United States).

The curvature map for the patient's left eye is relatively normal (Figure 3). Intriguingly, corneal elevation and central thickness are within normal limits (Figure 7). Corneal hysteresis and the resistance factor from the Ocular Response Analyzer (Reichert, Inc., Depew, NY) are also relatively normal. The only abnormal finding is the marked displacement of the thinnest point, located 1.2 mm temporally and inferiorly to the center, so that vertical displacement is 3.61

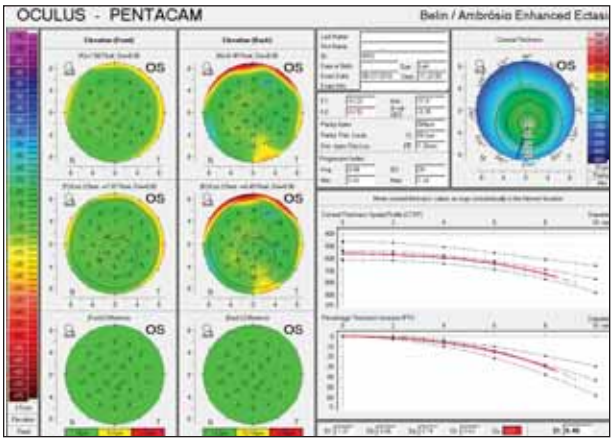

Figure 7. Belin/Ambrósio Enhanced Ectasia Display of the patient's left eye.

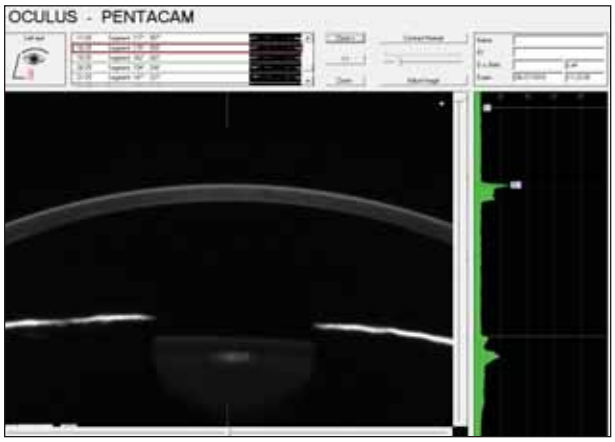

Figure 8. Scheimpflug image of the patient's left eye. The mild increase in corneal scattering at Descemet's level is compatible with the second hump (camel sign).



Figure 9. Specular photography of the endothelium in the patient's left eye, with moderate pleomorphism and polymegatism.

standard deviations from normal. This finding is expected in fewer than 1% of normal corneas, but the final deviation value in the Belin-Ambrósio Enhanced Ectasia Display, which combines elevation and pachymetric parameters, is 0.46—within the normal range.

Certainly, our screening tests for ectasia and susceptibility must evolve.[5,6] Highly asymmetric presentations of ectasia provide us with an opportunity to improve our understanding of the disease. My colleagues and I were able to detect abnormalities at the tomographic and biomechanical level in more than 90% of eyes with normal topography from patients with asymmetric keratoconus in their contralateral eye (R.A. and The Rio de Janeiro Corneal Tomography and Biomechanics Study Group, unpublished data, 2008).

There are different explanations for the clinical puzzle this case presents. The patient may have developed ectasia in an originally normal cornea after severely rubbing her right eye—trauma that did not occur in her left eye. Alternatively, the patient has a combination of mild ectasia and endothelial disease. In this case, there is a mild increase in scattering at the level of Descemet's membrane, detectable with Scheimpflug imaging (Figure 8). This was described as the second hump (camel sign),[7] and it is consistent with endothelial disease and is commonly seen in cases with corneal guttae. In this case, however, there is no guttata but marked polymegatism and pleomorphism on the specular endothelial image (Figure 9). Another possibility is that the patient's left eye is influenced by recent contact lens wear, with mild edema and an unusual type of warpage that can reduce the ectatic presentation.

Customized surface ablation might be considered for the patient's left eye, but detailed informed consent about the possible progression of endothelial and ectatic disease would be mandatory. Perhaps the best option in this case would be to observe the patient and repeat tomography and biomechanical tests over time. A special phakic IOL for low myopia would be an option, but the endothelium would require very careful monitoring.

MICHAEL W. BELIN, MD

This is an interesting case, complicated by incomplete or missing information. The examination of the patient's left eye (September 2, 2009) is clearly abnormal. She has an anterior elevation at the thinnest point that is greater than 30 µm and a posterior elevation at the thinnest point that is higher than 60 µm (normal, 1.7 ±2.0 µm for anterior, 3.6 ±4.7 µm for posterior; about 13 standard deviations from the norm) as well as a progression index of 2.53. There is no doubt this represents advanced ectatic disease, despite a low simulated keratometry reading. The patient under-

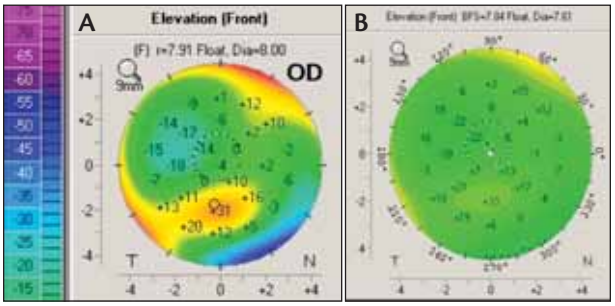

(Courtesy of Michael W. Belin, MD.)

Figure 10. Preoperative (A) and postoperative (B) anterior elevations with the Pentacam. The effect of scaling is evident. The overly wide scale used on the postoperative examination (right side) masks the pathology in spite of greater elevation (33 vs 31 µm).

went CXL and is now reportedly stable. The difficulty here is what "reportedly stable" actually means. The follow-up examination with the Pentacam Comprehensive Eye Scanner (Oculus, Inc., Lynnwood, WA) done 1 year later (August 27, 2010) cannot be directly compared to her preoperative examination. The scales used on the follow-up map are inappropriately broad (±300 µm anterior, ±150 µm posterior) compared to the preoperative 2009 examination (±75 µm). While not affecting the actual elevation data, the difference changes the appearance of the maps and can mask pathology (Figure 10).

Of greater concern is that, when making comparisons over time, it is important to use the same sphere of reference. This was not done. The preoperative reference surface on both the anterior and posterior surfaces is slightly flatter and would cause some change (greater positive elevation) on the postoperative map. I requested the U12 file (actual data file) to make these adjustments, but it was not available.

Because the patient appears to be asymptomatic in her left eye, I would not offer any refractive options. One could make a reasonable argument for prophylactic CXL in her left eye in light of the known ectatic change in her right eye, her young age, and significant displacement of the thinnest point. One could make an equally valid argument for closely observing the "normal" eye for further change before recommending treatment. For me (and most surgeons in the United States), this is a moot discussion, because CXL is not currently available in this country. If it were, I would suggest treating the left eye.

Probably the more controversial issue is how to treat the patient's obviously abnormal right eye, which has already undergone CXL, now that she is reportedly developing contact lens intolerance. In my experience, growing intolerance is not uncommon with soft lenses or among older patients as their tear production decreases, but the problem is not common with rigid lenses if the patient's cornea is truly stable. This patient's decreased tolerance for a rigid lens needs to be examined more closely, as it raises questions about corneal stability.

Whether the cornea is stable or not, I would first determine why she is developing lens intolerance and attempt to correct it. I have had luck fitting back toric lenses or customized lenses based on the anterior surface topography in cases of highly astigmatic corneas. If I were convinced that her cornea was truly stable, I might entertain the possibility of surface ablation, but I do not have a lot of comfort with it. Moreover, the cases I have reviewed in the literature have typically not exhibited this degree of posterior change.

ERIK L. MERTENS, MD, FEBOPHTH

The keratoconus in this young patient's right eye is obvious and was previously treated with CXL. Topography shows corneal stability in this eye and no actual pathological signs in the patient's left eye. Keratoconus is a bilateral disease, however, which I would bear in mind before treating her left eye.

There are two options available for treating this patient. One would be to perform topography-guided PRK (not available in the United States) on her right eye to treat the myopic astigmatism. This option would not be my preference because of the high cylinder, significant existing spherical aberration, and large amount of corneal tissue (approximately 80 µm with an optical zone of 6 mm) that will be removed. Recently published articles[8,9] report on simultaneous CXL with ultraviolet A and PRK, which could be an option outside the United States if the patient wishes to undergo treatment of her left eye.

My first choice for treating the patient's right eye would be the Visian TICL (V4B; STAAR Surgical Company, Monrovia, CA; not available in the United States). The anterior chamber depth measures 3 mm from the endothelium, as evident on the Pentacam map. This toric implant recently became available in Europe and was previously manufactured only as a custom-designed phakic IOL.[10] More and more surgeons[11-13] propose this approach as the best option for treating refractive errors in keratoconic eyes. I would correct the stable myopia in the patient's left eye with the Visian ICL (STAAR Surgical Company), which would not compromise corneal stability. ■

Section Editor Stephen Coleman, MD, is the director of Coleman Vision in Albuquerque, New Mexico. Parag A. Majmudar, MD, is an associate professor, Cornea Service, Rush University Medical Center, Chicago Cornea Consultants, Ltd. Karl G. Stonecipher, MD, is the director of refractive surgery at TLC in Greensboro, North Carolina. Dr. Majmudar may be reached at (847) 882-5900; pamajmudar@chicagocornea.com.

Renato Ambrósio Jr, MD, PhD, is the clinical director of cornea and refractive surgery at Instituto de Olhos Renato Ambrósio in Rio de Janeiro, Brazil. He is a consultant to Oculus GmbH. Dr. Ambrósio may be reached at +5521 2234 4233; renatoambrosiojr@terra.com.br.

Michael W. Belin, MD, is a professor of ophthalmology & vision science at the University of Arizona in Tucson. He is a consultant to Oculus GmbH. Dr. Belin may be reached at (518) 527-1933; mwbelin@aol.com.

Erik L. Mertens, MD, FEBOphth, is the chief medical editor of Cataract & Refractive Surgery Today Europe. *Dr. Mertens is the medical director of Medipolis in Antwerp, Belgium, and of FYEO Medical in Eersel, The Netherlands. He is a consultant to Alcon Laboratories, Inc., and STAAR Surgical Company. Dr. Mertens may be reached at +32 3 828 29 49; e.mertens@medipolis.be.*

1. Lee BW, Jurkunas UV, Harissi-Dagher M, et al. Ectatic disorders associated with a claw-shaped pattern on corneal topography. *Am J Ophthalmol*. 2007;144:154-156.
2. Krachmer JH, Feder RS, Belin MW. Keratoconus and related noninflammatory corneal thinning disorders. *Surv Ophthalmol*. 1984;28:293-322.
3. Coskunseven E, Jankov MR 2nd, Hafezi F, et al. Effect of treatment sequence in combined intrastromal corneal rings and corneal collagen crosslinking for keratoconus. *J Cataract Refract Surg*. 2009;35:2084-2091.
4. Tamayo GE, Serrano MG. Treatment of irregular astigmatism and keratoconus with the VISX C-CAP method. *Int Ophthalmol Clin*. 2003;43:103-110.
5. Ambrosio R Jr, Dawson DG, Salomao M, et al. Corneal ectasia after LASIK despite low preoperative risk: tomographic and biomechanical findings in the unoperated, stable, fellow eye. *J Refract Surg*. 2010;26:906-911.
6. Belin MW, Ambrosio R Jr. Corneal ectasia risk score: statistical validity and clinical relevance. *J Refract Surg*. 2010;26:238-240.
7. Kwon RO, Price MO, Price FW Jr, et al. Pentacam characterization of corneas with Fuchs dystrophy treated with Descemet membrane endothelial keratoplasty. J Refract Surg. 2010;26(12):972-979.
8. Krueger RR, Kanellopoulos AJ. Stability of simultaneous topography-guided photorefractive keratectomy and riboflavin/UVA cross-linking for progressive keratoconus: case reports. *J Refract Surg*. 2010;26(10):S827-S832.
9. Kymionis GD, Kontadakis GA, Kounis GA, et al. Simultaneous topography-guided PRK followed by corneal collagen cross-linking for keratoconus. *J Refract Surg*. 2009;25(9):S807-S811.
10. Mertens EL, Sanders DR, Vitale PN. Custom-designed toric phakic intraocular lenses to correct high corneal astigmatism. *J Refract Surg*. 2008;24:501-506.
11. Kamiya K, Shimizu K, Ando W, et al. Phakic toric implantable collamer lens implantation for the correction of high myopic astigmatism in eyes with keratoconus. *J Refract Surg*. 2008;24:840-842
12. Alfonso JF, Fernández-Vega L, Lisa C, et al. Collagen copolymer toric posterior chamber phakic intraocular lens in eyes with keratoconus. *J Cataract Refract Surg*. 2010;36:906-916.
13. Kamiya K, Shimizu K, Kobashi H, et al. Clinical outcomes of posterior chamber toric phakic intraocular lens implantation for the correction of high myopic astigmatism in eyes with keratoconus: 6-month follow-up [published online ahead of print October 16, 2010]. *Graefes Arch Clin Exp Ophthalmol*.