

Managing the Unhappy Cataract Patient

Tips for improving outcomes and patients' satisfaction with premium IOLs.

BY KENNETH A. BECKMAN, MD

In this era of immediate gratification and premium IOLs, patients have become more demanding. The following scenario is common. A postoperative cataract patient presents with a visual acuity of 20/20- and a manifest refraction of -0.25 D. Upon entering the room, the patient greets the surgeon with the question, "Why can't I see?" This article discusses my strategies for preventing and solving this dilemma.

PREOPERATIVE ASSESSMENT

The preoperative assessment begins with a detailed history identifying the patient's visual complaints and determining how these affect specific activities of his or her daily living. In my practice, I use a questionnaire to determine the patient's visual acuity demands and postoperative visual acuity goals. A physical examination helps me to determine if the findings are consistent with the patient's visual complaints. Contributing pathology that may be related to the ocular surface, anterior segment, posterior segment, or central visual pathways should be ruled out or treated appropriately.

It is important to pay close attention to the lid margins, cornea, and tear film and, obviously, to address retinal and neurologic pathology. The lid margins and ocular surface often represent the source of future problems. Preoperative examinations include a refraction with glare testing, keratometry, topography, and biometry; I use the IOLMaster (Carl Zeiss Meditec, Inc., Dublin, CA). Other testing may include pachymetry, optical coherence tomography, or visual field testing if indicated. I prefer to obtain multiple keratometry readings, making sure that they are con-

sistent, and I also perform topography with placido images to determine if the mires are regular. If the keratometry readings are not consistent, or the mires are not regular, I attempt to clean up the ocular surface

THERAPEUTIC REGIMEN

For patients with blepharitis, I begin azithromycin (AzaSite; Inspire Pharmaceuticals, Inc.) q.h.s. for 1 week preoperatively. I have noted that this regimen has considerably decreased the persistent "oil slick," which may occur intraoperatively and require constant irrigation. I also prescribe a fourth-generation fluoroquinolone topical antibiotic and a topical steroid.

Nonsteroidal anti-inflammatory drops may reduce postoperative pain and inflammation¹ as well as be useful for the prevention and treatment of cystoid macular edema.² I have patients begin using ketorolac 0.45% (Acuvail; Allergan, Inc.) b.i.d. beginning 1 week preoperatively and continuing for 4 weeks postoperatively. I favor the carboxymethylcellulose vehicle as well as the lack of preservatives in Acuvail, as I want to minimize the variables that may alter the corneal surface and affect the outcome.

1. Acuvail [package insert]. Irvine, CA: Allergan Inc.; 2009.

2. Wittmann JR, Silverstein S, Heier J, Kenyon KR, et al. A randomized mass comparison of topical ketorolac 0.4% plus steroid versus steroid alone in low-risk cataract surgery patients. *Am J Ophthalmol.* 2008;146:554-560.

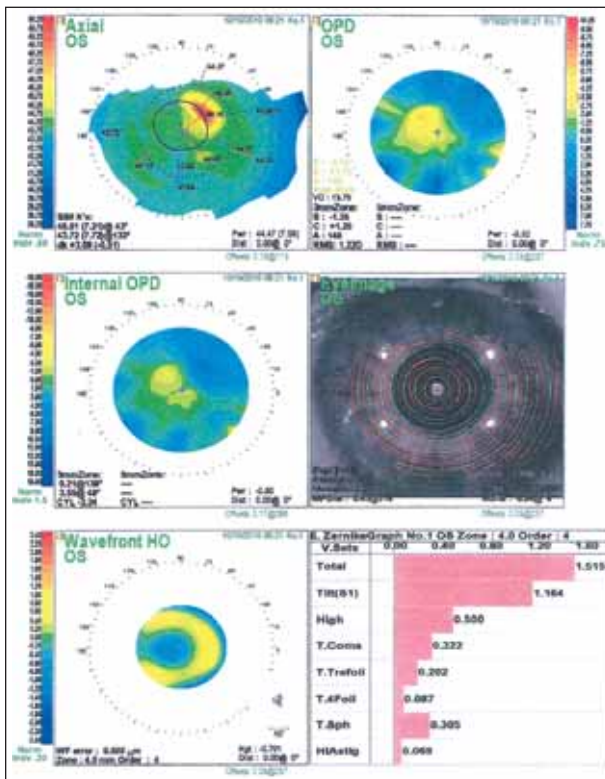


Figure 1. Corneal topography for a patient with blepharitis and dry eye disease. Note the irregular mires and 3.00 D of irregular astigmatism.

and bring the patient back at a later date for further testing. Although this delay can frustrate the patient, it is essential for optimizing outcomes.

Detected abnormalities are frequently related to lid margin disease. Common findings include thickened meibomian gland secretions and lash debris, for which aggressive treatment is essential. In addition to perioperative infection, lid margin disease can lead to inaccurate IOL power calculations that will result in a poor refractive outcome and postoperative aberrations that compromise visual acuity.

PREOPERATIVE TREATMENT

I instruct patients with lid margin disease to use warm compresses and lid hygiene. My first-line medical therapy is topical azithromycin (AzaSite; Inspire Pharmaceuticals, Inc.) b.i.d. for 2 days followed by q.h.s. for up to 4 weeks. A study by Jodi Luchs, MD,¹ demonstrated that topical azithromycin with warm compresses was superior to warm compresses alone for the treatment of the signs and symptoms of posterior blepharitis. Tear film dysfunction may coexist with blepharitis and contribute to poor outcomes. I fre-

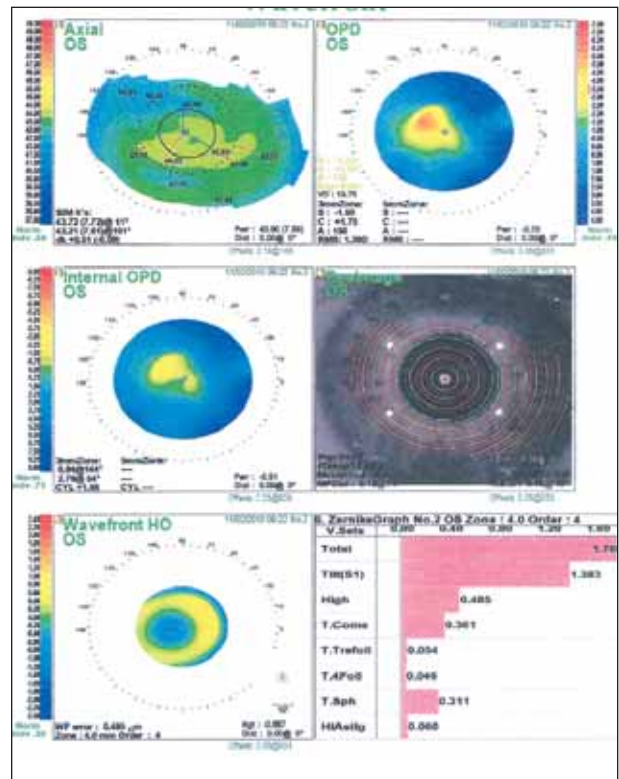


Figure 2. Corneal topography for the same patient after 2 weeks of treatment. Note the regular mires and dramatic decrease in corneal astigmatism.

quently measure the tear breakup time and assess conjunctival staining with lissamine green; I do not typically do Schirmer's testing.

To treat the tear film, I prefer preservative-free artificial tears and do not hesitate to add topical cyclosporine A (Restasis; Allergan, Inc.) b.i.d. immediately. It is important to ensure that patients understand that these treatments do not provide immediate results, and it might take 6 weeks or more to obtain accurate measurements. Because they are eager to proceed with surgery, patients may need extensive counseling so as to understand the importance of accurate IOL calculations. Figure 1 shows the corneal topography for a patient with blepharitis and dry eye disease. Figure 2 shows the corneal topography for the same patient after 2 weeks of treatment. Note the regular mires and dramatic decrease in corneal astigmatism.

Another external factor that may contribute to inaccurate preoperative measurements is lid position, as significant ptosis may alter corneal measurements and compromise vision. Contact lens wear may lead to corneal warpage and inaccurate keratometry readings,

THE GOAL: AMAZING OUTCOMES

BY EHSAN SADRI MD

As progressive-minded ophthalmologists, we have one goal: outcomes. With the large number of baby boomer patients expecting exciting advances in cataract surgery, it is mandatory that we provide excellent postoperative visual acuity.

I use Bromday (bromfenac ophthalmic solution 0.09%; Ista Pharmaceuticals, Inc.) as my “go to” nonsteroidal anti-inflammatory drug for the treatment of pain and inflammation after cataract surgery. Although it is an off-label indication, I also believe the agent is useful for the prevention of cystoid macular edema. The effectiveness and comfort as well as patients’ adherence with this product have led to my using it after all cataract surgeries—especially with premium IOLs. It has been well demonstrated in glaucoma patients that adherence to medical regimens drops off the more frequently the medications are dosed. With once-a-day dosing, Bromday is a pillar in my defense against postoperative inflammation. I combine Bromday, Durezol (difluprednate

ophthalmic emulsion 0.05%; Alcon Laboratories, Inc.), and Vigamox (moxifloxacin HCl ophthalmic solution 0.5%; Alcon Laboratories, Inc.) and use them one, two, and three times per day, respectively. The results I see at the slit-lamp examination are remarkable, and patients really enjoy the “wow” factor.

As an example, I recently saw a patient at her 1-week postoperative appointment with a visual acuity of 20/20 and J1/2 OU after Tecnis Multifocal IOL (Abbott Medical Optics Inc., Santa Ana, CA) placement. It was as if she had won the lottery! She was elated. The bottom line is that patients talk to one another and the word is out. They expect results and fast.

Ehsan Sadri, MD, is a board-certified ophthalmologist and a fellowship-trained glaucoma and cataract surgeon in practice in Newport Beach, California. He is a consultant to Allergan, Inc., and Ista Pharmaceuticals, Inc. Dr. Sadri may be reached at (949) 642-3100; esadri@gmail.com.

so I require patients to discontinue their contact lens wear for 1 week with soft lenses and at least 2 weeks with rigid lenses. Patients are instructed to return at a later date for a repeat evaluation. Occasionally, they may require more time out of contacts if I am not satisfied with their keratometry and topography results on their return visit.

Coexisting corneal disease can alter postoperative outcomes as well. It is not uncommon for patients to present with previous infections and residual scarring as well as corneal dystrophies. Patients with anterior basement membrane dystrophy may require debridement to create a more regular surface. I counsel those with Fuchs dystrophy on the risk of corneal decompensation and the possibility they may require endothelial keratoplasty. Pachymetry is useful in the assessment of Fuchs dystrophy and for decision making as to the patient’s need for endothelial keratoplasty. Topical hypertonics may aid in resolving corneal edema.

CONCLUSION

Extensive preoperative counseling is essential for cataract patients electing premium IOLs. They should understand why they must undergo detailed preopera-

tive testing and occasional delays prior to surgery to obtain the best results possible. When patients have elected new-technology lenses, I say that there is no guarantee that they will be completely free of spectacles after surgery. Rather, I explain that the goal is to improve their best-corrected visual acuity. Patients should be informed that, if other unrelated pathology is present, their final visual outcome may be limited.

By following the principles described herein and with careful attention to preparation and patients’ expectations, many of the issues that cause patients’ complaints can be prevented, and the number of unhappy postoperative patients can be minimized. ■

Kenneth A. Beckman, MD, is the director of corneal services at Columbus Ophthalmology Associates and a clinical assistant professor of ophthalmology, The Ohio State University. He is a consultant to and a speaker for Allergan, Inc., and Inspire Pharmaceuticals, Inc.

Dr. Beckman may be reached at (614) 766-2006; kenbeckman22@aol.com.



1. Luchs J. Efficacy of topical azithromycin ophthalmic solution 1% in the treatment of posterior blepharitis. *Adv Ther.* 2008;25:858-870.