

The Visian Toric ICL

This new lens reduces the need for additional phakic IOL implants and keratorefractive procedures.

BY ERIK L. MERTENS, MD, FEBO

Refractive surgery options to correct moderate-to-high myopia and myopic astigmatism are limited. LASIK, PRK,^{1,2} LASEK, and more recently Epi-LASIK^{3,4} are less predictable and safe versus refractive IOLs for the treatment of moderate myopia with or without astigmatism. Complications reported for the laser correction of high refractive errors include corneal ectasia, low predictability, poor quality of vision under dim illumination, and regression.^{5,6} Although refractive lens exchange corrects the ametropia, young patients often lose accommodation, and the risk of retinal detachment is significant.⁷ The implantation of IOLs has been a part of cataract surgery for many years, but these lenses only recently became available specifically for refractive correction.

Surgeons respect refractive lens implants' accuracy at restoring vision,⁸ because their method of correction is reversible and predictable. Moreover, the eye heals rapidly, and the procedure does not permanently alter the shape or structures of the cornea.

The difficulty currently lies in convincing patients to undergo the procedure. Generally, they find laser surgery more attractive, because they view IOL implantation as far too invasive. One option is to suggest the Visian Toric ICL (not available in the US; STAAR Surgical Company, Monrovia, CA).

VISIAN TORIC ICL

The Visian Toric ICL is made of STAAR's proprietary collagen copolymer collamer. From November 2003 to present, I have implanted 166 Toric ICLs at the Antwerp Eye Center in Belgium. The myopic correction has ranged from -2.00 to -14.00D, and the cylindrical correction has ranged from -1.00 to -5.25D.

PATIENTS AND METHODS

I conducted an investigation to explore the efficacy and predictability of the Visian Toric ICL. The study included

patients between the ages of 18 and 50 years with a stable refraction for at least 1 year and astigmatism greater than 1.00D. Subjects also had an otherwise normal ophthalmologic examination. The patients received preoperative counseling (ie, an outline of potential surgical complications as well as alternative refractive techniques and their respective benefits and risks) at their initial consultation. Exclusion criteria were anterior segment pathology; an anterior chamber depth from the endothelium of fewer than 2.8mm; abnormal iris function; recurrent uveitis; any form of cataract, glaucoma, retinal detachment, preexisting macular degeneration, or macular pathology; chronic treatment with corticosteroids or any immunosuppressive treatment or state; and pregnancy.

SURGICAL PROCEDURE

Each patient received two Nd:YAG laser iridotomies at the 10:30- and 1:30-o'clock positions at least 1 week before surgery. Immediately before surgery, I marked the horizontal axis with a pointed marker at the limbus. I treated the patient's left eye first. I applied povidone iodine 10% to the eyelids, draped the patient, and inserted a lid speculum. I used four drops of oxybuprocaine hydrochloride 4mg/mL (not available in the US; Unicaïne; Bournonville Pharma, Breda, the Netherlands;) to anesthetize each eye. Three minutes before making the corneal incision, I administered povidone iodine 5% to the ocular surface. I then made a paracentesis superiorly for the left eye and inferiorly for the right eye and injected methylcellulose 20mg/mL (Ocucoat; Bausch & Lomb, Rochester, NY) into the anterior chamber.

I made a 2.65-mm temporal clear corneal incision with a 30° stab knife and a 2.65-mm blade (Bausch & Lomb). I then reinjected methylcellulose 20mg/mL into the anterior chamber.

Under the microscope, I loaded the Visian Toric ICL into the STAAR injector cartridge using a Vukich ICL forceps (ASICO, Westmont, IL)

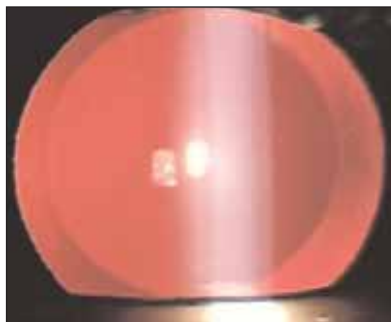


Figure 1. Pictured is an eye implanted with the Visian Toric ICL.

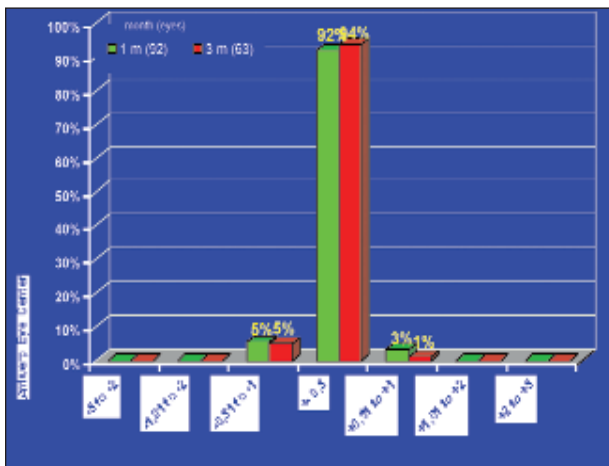


Figure 2. At 3 months postoperatively, the majority of the patients implanted with the Visian Toric ICL were within 0.50D of their intended refractions.

and a modified Aus der Au forceps (not available in the US; Janach, Como, Italy). Next, I inserted the tip of the injector cartridge into the temporal corneal wound, injected the Toric ICL, and tucked the haptics behind the iris with a manipulation forceps (Duckworth & Kent, Baldock, Hertfordshire, UK). I rotated the Toric ICL according to the lens' implantation software (ie, clockwise or counter-clockwise) (Figure 1).

After irrigating away the methylcellulose with copious amounts of balanced salt solution (BSS; Alcon Laboratories Inc., Fort Worth, TX), I instilled 6mg/mL of vancomycin in the anterior chamber. I then administered one drop of combined dorzolamide 20mg and timolol 5mg/mL suspension (Cosopt; MSD, Riyadh, Saudi Arabia; available in the US from Merck & Co, Inc., West Point, PA); lomefloxacin 3mg/mL; and a terracortril suspension (hydrocortisonacetat 17mg, oxytetracycline 5.7mg, polymyxine B 11400IE/g; Pfizer Inc., New York, NY). Immediately after surgery, I administered acetazolamide 250mg (Diamox; Haupt Pharma, Berlin, Germany; available in the US from Wyeth Pharmaceuticals, Philadelphia, PA) to the patients to minimize rises in IOP. They took this drug again 1 day postoperatively.

All cases involved bilateral surgery. I changed my gown and gloves and used a separate set of surgical instruments for each eye. I instilled povidone iodine solution before surgery for a second time. Different lots of BSS, methylcellulose, and vancomycin were used in all cases.

The patients' postoperative medication included infectoflam collyre (fluorometholone 1mg/mL, gentamycin 3mg/mL; Novartis, Basel, Switzerland) and indomethacin 1mg/mL administered q.i.d. for the first week. The dose was tapered to one daily drop 4 weeks postoperatively. Additionally, patients instilled hyabak

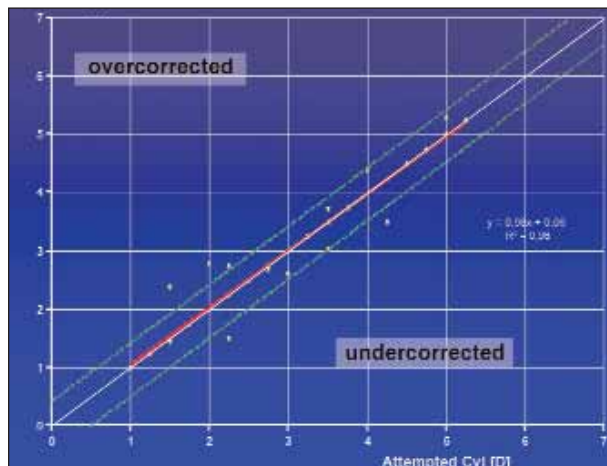


Figure 3. Eighty-seven of 92 eyes implanted with the Visian Toric ICL were within 1.00D of their intended cylindrical correction.

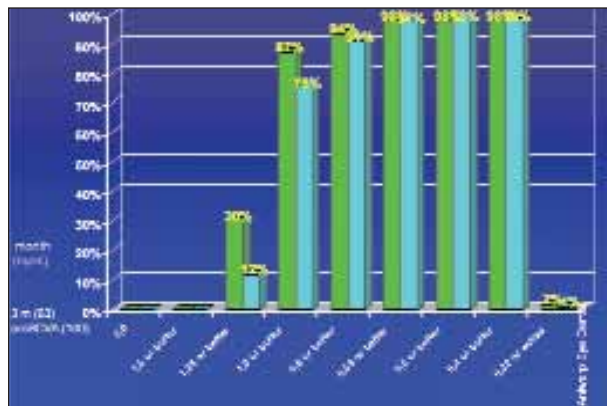


Figure 4. According to the efficacy index (ie, mean postoperative UCVA/mean preoperative BSCVA), patients with the Visian Toric ICL achieved significant improvements in UCVA 3 months postoperatively.

collyre (not available in the US; sodium hyaluronate 1.5mg/mL; Thea Pharma, Schaffhausen, Germany) and Genteal Gel (hypromellose 3mg/mL; CIBA Vision, Duluth, GA) q.i.d. for 1 month. Postoperative examinations occurred at 1 day, 1 week, 1 month, and 3 months.

RESULTS

Predictability

Three months after surgery, 94% of the eyes (n = 63) were within ±0.50D of their intended refraction, and 100% were within ±1.00D (Figure 2).

Astigmatic Correction

A total of 94.5% eyes (87 of 92) were within 1.00D of their intended cylindrical correction (Figure 3). Three ICLs were misaligned and were rotated into the correct axis without any problem.

Efficacy

Three months after surgery, the overall efficacy index (ie, mean postoperative UCVA/mean preoperative BSCVA) was 112.2%. The postoperative UCVA measured 20/25 or better in 94% of the eyes, 20/20 or better in 87% of the eyes, and 20/16 or better in 30% of the eyes (Figure 4). All improvements in UCVA and BSCVA were statistically significant.

Complications

Three percent of eyes (n = 5) required a secondary intervention. In two eyes, acute angle-closure glaucoma occurred due to excessive vaulting of the Visian Toric ICL, and the lens was explanted. This sizing issue, however, did not occur again. I used the Vumax II (Sonomed, Inc., Lake Success, NY), which is an ocular high frequency ultrasound biomicroscopy device that accurately measures the sulcus-to-sulcus diameter. In my most recent 86 Visian Toric ICL implants, 16 eyes had a discrepancy in their sulcus-to-sulcus diameter with respect to their white-to-white corneal diameter. By readjusting the lens' size to the sulcus-to-sulcus diameter, no excessive vaulting occurred postoperatively. I repositioned the three Visian Toric ICLs that were misaligned after approximately 1 month because of a 15° to 25° deviation from the target axis. No potentially sight-threatening complications (eg, iris prolapse, iris atrophy, touch of the anterior capsule, persistent corneal edema, cataract formation, retinal detachment, endophthalmitis, or serofibrinous reaction) were reported during follow-up.

CONCLUSION

The introduction of the Visian Toric ICL has significantly decreased the need for combining the implantation of a posterior chamber phakic IOL with keratorefractive procedures (ie, bioptics). The technology thus helps surgeons avoid complications such as flap striae, reduced contrast sensitivity under low-light conditions, and haze. Spherical and cylindrical corrections are combined in the Visian Toric ICL, which is designed to correct the total refractive error, corneal astigmatism, and lenticular astigmatism.⁹ The predictability of this phakic IOL is so high that secondary procedures are indicated in only a few cases. This level of efficacy is hard to achieve with other phakic IOLs or laser refractive procedures.

With the introduction of new-generation ultrasound biomicroscopy instruments such as the Vumax II, my

accuracy in sizing the Visian Toric ICL has improved dramatically. In 18.6% of eyes, a Visian Toric ICL size other than that suggested by the corneal white-to-white measurements needed to be implanted. Sizing became a non-issue in my practice (Figure 5).

Reversibility is an important consideration for both the surgeon and the patient, especially when other refractive corneal surgeries permanently alter the cornea.

The Visian Toric ICL will soon be available in the US, and I believe it will be quickly adopted by ophthalmic surgeons. In my opinion and practice, the accuracy in correcting preexisting astigmatism with this phakic IOL is much higher than with limbal relaxing incisions or placing the cataract incision at the steepest axis. At the Antwerp Eye Center, all eyes with astigmatism of 1.00D and higher (50% of all study cases) receive the Visian Toric ICL. Except for the lens' alignment in the posterior chamber, there is no difference in the implanta-

tion technique compared with the Visian ICL. The toric design will significantly broaden the indications for phakic IOLs, and I predict that, in a few years, 20% of refractive surgery cases will use these implants.

My colleagues' and my data have shown that the Visian Toric ICL reduced preoperative spherical and astigmatic errors with high predictability and good stability, and it achieved extremely successful visual outcomes and strong patient satisfaction. Complications were minimal and responsive to treatment. ■

Erik L. Mertens, MD, FEBO, is the medical director of the Antwerp Eye Center in Belgium. He is a paid consultant for STAAR Surgical Company. Dr. Mertens may be reached at +32 3 8282949; e.mertens@zien.be.



Figure 5. Vaulting of the Visian Toric ICL can easily be checked by performing a slit-lamp examination.

- Buratto L, Ferrari M, Genisi CM, Genisi C. Myopic keratomileusis with the excimer laser: one year follow up. *Refract Corneal Surg.* 1993;9:12-19.
- Sher NA, Barak M, Daya S, et al. Excimer laser photorefractive keratectomy in high myopia. A multicenter study. *Arch Ophthalmol.* 1992;110:935-943.
- Pallikaris IG, Kalyvianaki MI, Katsanevaki VJ, Giniis HS. Epi-LASIK; preliminary clinical results of an alternative surface ablation procedure. *J Cataract Refract Surg.* 2005;31:879-885.
- Dai J, Chu R, Zhou X, et al. One-year outcomes of epi-LASIK for myopia. *J Refract Surg.* 2006;22:589-595.
- Seiler T, Holschbach A, Derse M, et al. Complications of myopic photorefractive keratectomy with the excimer laser. *Ophthalmology.* 1994;101:153-160.
- Seiler T, Koufala K, Richter G. Iatrogenic keratectasia after laser in situ keratomileusis. *J Refract Surg.* 1998;14:312-317.
- Lee KH, Lee JH. Long-term results of clear lens extraction for severe myopia. *J Cataract Refract Surg.* 1996;22:1411-1415.
- Bartels MC, Santana NTY, Budo C, et al. Toric phakic intraocular lens for the correction of hyperopia and astigmatism. *J Cataract Refract Surg.* 2006;32:243-249.
- Mertens E. Integrating phakic IOLs in a private practice. *Ophthalmology Times Europe.* 2006;2:1:28-29.