

Corneal Correction of Astigmatism During Cataract Surgery

A surgeon's ability to diminish or eliminate corneal astigmatism at the time of lenticular surgery is valuable.

BY UDAY DEVGAN, MD

In the age of refractive cataract surgery, addressing the patient's preexisting corneal astigmatism at the time of surgery is important to delivering postoperative emmetropia and satisfaction. Minimizing postoperative astigmatism (no more than 0.50 to 0.75D) is particularly important for achieving optimal results with multifocal IOLs (Figure 1).

Treating astigmatism with an excimer laser in pseudophakic patients is precise, but many cataract surgeons may not have access to this modality. Toric

"In refractive cataract surgery, addressing preexisting corneal astigmatism is important to delivering postoperative emmetropia and satisfaction."

IOLs are an alternative, but they do not correct presbyopia. Another viable option is to treat the astigmatism via corneal incisions—a relatively safe and easy method with a minimal learning curve.

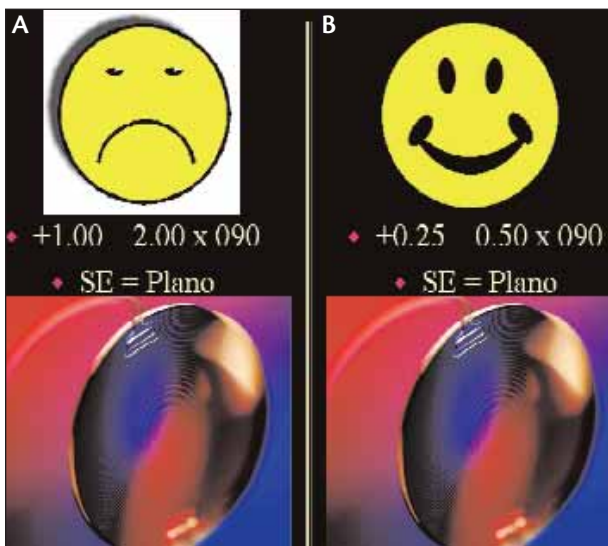


Figure 1. Pictured is a comparison of differences between patients with identical postoperative spherical equivalents, but markedly differently astigmatism. The patient with a multifocal IOL with 2.00D of cylinder will probably be unhappy (A), whereas the patient with the same IOL and only 0.50D of cylinder likely will be happy (B).

BASIC CONCEPTS

Understanding the basics of corneal incisions is an important first step. There are five primary concepts:

1. The corneal coupling effect explains why making a relaxing incision in the cornea flattens that meridian and steepens the cornea 90° away. For peripheral relaxing incisions, like limbal relaxing incisions (LRIs), this coupling ratio is 1:1. No change in the IOL power is needed because the cornea's spherical equivalent has not changed.

2. The larger the corneal incision is, the more it will flatten that meridian, and the more steepening it will cause 90° away.

3. The more central an incision is, the more flattening it will cause at that meridian. Peripheral incisions, like LRIs, have less effect but are more forgiving and less likely to induce irregular astigmatism. Central incisions such as astigmatic keratotomies (AKs) are significantly stronger in their effect, but they are also more likely to cause irregular astigmatism.

4. With penetrating incisions, short tunnels cause

more flattening than long ones. For example, with the clear corneal incisions used during cataract surgery, the shorter the tunnel length, the more the flattening effect at that meridian and the steeper the effect 90° away. The long, square corneal incisions seal well and have little effect on astigmatism. The short tunnels are better able to reduce the astigmatism in their meridian, but they are more likely to leak at the end of the surgery.

“Most temporal clear corneal incisions of 2.6 to 3.0mm cause about 0.25 to 0.75D (with an average of about 0.50D) of flattening at the meridian.”

5. With nonpenetrating incisions such as LRIs and AKs, the deeper the cuts, the more the flattening effect. Most LRIs are performed with set depths of 500, 550, or 600 μ m, whereas AKs are usually performed at a depth that is a percentage of the total corneal thickness at that site. Although surgeons are less likely to cause an unintentional corneal perforation with the shallower incisions, they have less ability to modulate the astigmatism.

A FIRST STEP

It is important for cataract surgeons to know the effect of their incisions. Most temporal clear corneal incisions of 2.6 to 3.0mm cause about 0.25 to 0.75D (with an average of about 0.50D) of flattening at that

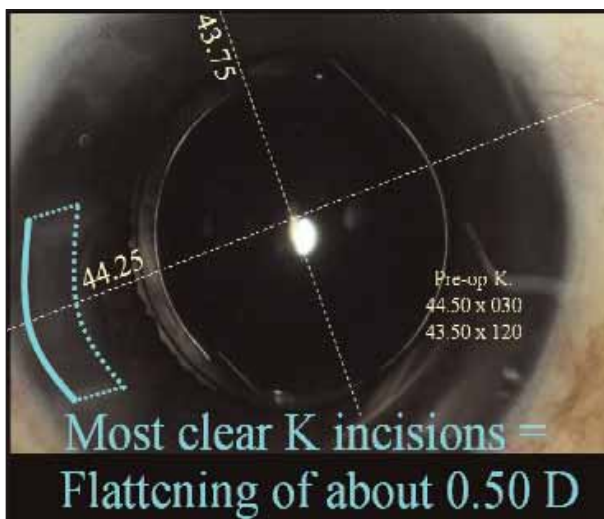


Figure 2. Most clear corneal phaco incisions cause a net flattening of about 0.50D.

meridian.¹ In order to determine the effect of your incisions, carefully measure the pre- and postoperative keratometry and calculate the difference. Surgeons can place the corneal incision on the steep axis in order to induce an intentional astigmatic reduction of about 0.50D² (Figure 2).

The surgeon can even make a second, full-thickness, perforating, clear corneal incision 180° away from the main incision in order to further increase the astigmatic effect.³ I would suggest making this second clear corneal incision at the end of the case, while the anterior chamber is still inflated with viscoelastic. This technique for managing astigmatism does not require the purchase of any additional instruments (Figure 3).

LRIs can provide ophthalmologists with additional control in effectively managing astigmatism during cataract surgery. Nomograms guide the extent and location of these incisions.

Among the pioneers of LRIs at the time of cataract surgery are Louis D. “Skip” Nichamin, MD;⁴ James Gills, MD;⁵ and Douglas Koch, MD.⁶ Each has developed and published his own nomogram that yields excellent results (Figure 4).

A SIMPLER STEP

Some of the simplest nomograms for astigmatic incisions come from Kevin Miller, MD, and Eric Donnenfeld, MD (Figures 5 and 6). Both nomograms are based upon the clock hours of treatment. Dr. Miller’s nomogram can be summed up as follows: perform 1 clock hour of paired incisions at 600 μ m on the steep axis for each diopter of corneal astigmatism. Dr. Donnenfeld’s nomogram is so easy that he calls it *LRIs for dummies*.




Figure 3. Making two paired clear corneal phaco incisions 180° apart can increase the net flattening.

TIPS AND TRICKS

Double even triple check that you are making the incisions on the correct axis. The most common mistake is making the incision 90° off, thereby doubling the patient’s astigmatism.

Preoperative corneal topography allows surgeons to understand the extent and location of the corneal astigmatism and to screen out patients who may have sub-clinical keratoconus.

Do not overcorrect the astigmatism, as this will flip

Intralimbal Relaxing Incision Nomogram for Modern Phaco Surgery Empiric blade-depth setting of 600µm Louis D. “Skip” Nichamin, MD ~ Laurel Eye Clinic, Brookville, PA								
SPHERICAL								
(up to +0.75 X 90 or +0.50 X 180)								
<i>Incision Design</i>	“Neutral” temporal clear corneal incision (ie, 3.5mm. or less, single plane, just anterior to vascular arcade)							
AGAINST-THE-RULE								
(Steep Axis 0-44°/136°-180°)								
Paired Incisions in Degrees of Arc*								
PREOPERATIVE CYLINDER		30-40 yrs old	41-50 yrs old	51-60 yrs old	61-70 yrs old	71-80 yrs old	81-90 yrs old	91+ yrs old
+0.75 to +1.25	Nasal limbal arc only*						35°	
		55°	50°	45°	40°	35°		
+1.50 to +2.00		70°	65°	60°	55°	45°	40°	35°
+2.25 to +2.75		90°	80°	70°	60°	50°	45°	40°
+3.00 to +3.75		90°	90°	85°	70°	60°	50°	45°
		o.z = 8mm		o.z = 9mm				
<i>Incision Design</i>	The temporal incision, if greater than 40° of arc, is made by first creating a two-plane, grooved phaco incision (600 µ depth), which is then extended to the appropriate arc length at the conclusion of surgery.							
WITH-THE-RULE								
(Steep Axis 45°-135°)								
Paired Incisions in Degrees of Arc								
PREOPERATIVE CYLINDER		30-40 yrs old	41-50 yrs old	51-60 yrs old	61-70 yrs old	71-80 yrs old	81-90 yrs old	91+ yrs old
+1.00 to +1.50		50°	45°	40°	35°	30°		
+1.75 to +2.25		60°	55°	50°	45°	40°	35°	30°
+2.50 to +3.00		70°	65°	60°	55°	50°	45°	40°
+3.25 to +3.75		80°	75°	70°	65°	60°	55°	45°
<i>Incision Design</i>	“Neutral” temporal clear corneal along with the following peripheral arcuate incisions							
<i>When placing intralimbal relaxing incisions following or concomitant with radial relaxing incisions, total arc length is decreased by 50%</i>								

(Courtesy of Louis “Skip” D. Nichamin, MD.)

Figure 4. Skip Nichamin, MD, has developed an accurate nomogram for the treatment of corneal astigmatism at the time of cataract surgery. He uses an empiric blade depth of 600µm, and his nomogram depends on the age of the patient as well as the amount of preoperative corneal astigmatism.

(Courtesy of Kevin Miller, MD.)

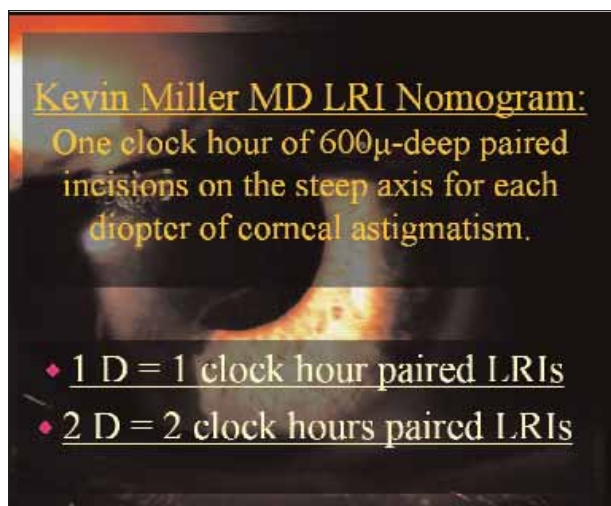


Figure 5. The simplest of all nomograms comes from Kevin Miller, MD, who has found no significant differences between depths of 450µm and 600µm. His nomogram is easy to remember, as it is just 1 clock hour of paired incisions for each diopter of symmetrical corneal astigmatism.

(Courtesy of Eric D. Donnenfeld, MD.)

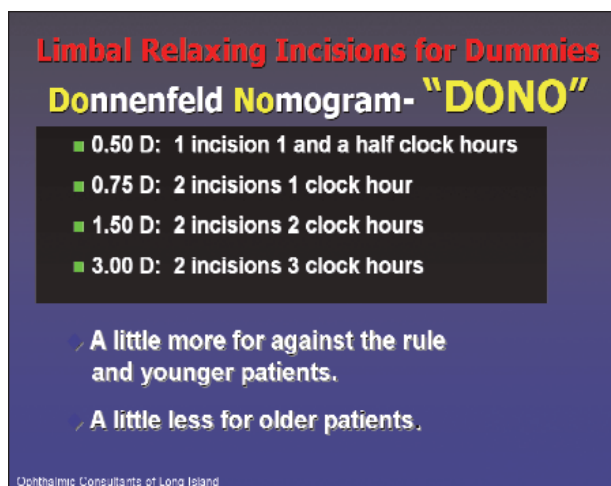


Figure 6. Eric Donnenfeld, MD, has developed a simple nomogram for his LRI procedures. Note that he uses a blade depth of 600µm and makes a mild correction for age as well.

the axis and give the patient astigmatism to which he is not accustomed. Overcorrection of with-the-rule astigmatism will result in new against-the-rule astigmatism and an unhappy patient. It is far better to leave the patient a little undercorrected.

Apply a thin coating of a dispersive viscoelastic to the external cornea prior to performing the LRI. Doing so will help the blade glide smoothly and prevent roughing up the epithelium.

Mark the 90° position with a surgical marking pen

while the patient is seated upright and before injecting anesthetics (topical drops are fine). This technique will ensure that any cyclotorsion of the eye does not cause a misplacement of the incisions.

I feel that the best instruments for making corneal relaxing incisions are diamond knives, which are available in preset or adjustable depths from many manufacturers. In particular, Accutome Inc. (Malvern, PA) makes diamond LRI knives for less than \$500.

CONCLUSION

The arena of multifocal IOLs, premium IOLs, and refractive lens surgery, requires the surgeons be able to reduce or eliminate corneal astigmatism at the time of lenticular surgery. With a minimal investment of instruments and time, most can begin with the simple nomograms presented herein, track their results, and then hone their technique. Managing corneal astigmatism is an important part of refractive cataract surgery that I teach to all of my residents and regularly perform in my own private practice. ■

Section Editor Eric D. Donnenfeld, MD, is a partner in Ophthalmic Consultants of Long Island and is Co-Chairman of Corneal and External Disease at the Manhattan Eye, Ear and Throat Hospital in New York. He acknowledged no financial interest in any products mentioned herein. Dr. Donnenfeld may be reached at (516) 766-2519; eddoph@aol.com.

Uday Devgan, MD, is in private practice at the Maloney Vision Institute in Los Angeles. Dr. Devgan is Acting Chief of Ophthalmology at Olive View-UCLA Medical Center and Assistant Clinical Professor at the UCLA Jules Stein Eye Institute. He acknowledged no financial interest in the products or companies mentioned herein. Dr. Devgan may be reached at (310) 208-3937; devgan@ucla.edu; www.maloneyvision.com.



1. Borasio E, Mehta JS, Maurino V. Torque and flattening effects of clear corneal temporal and on-axis incisions for phacoemulsification. *J Cataract Refract Surg.* 2006;32:2030-2038.
2. Kaufmann C, Peter J, Ooi K, et al. Limbal relaxing incisions versus on-axis incisions to reduce corneal astigmatism at the time of cataract surgery. *J Cataract Refract Surg.* 2005;31:2261-2265.
3. Khokhar S Lohiya P, Murugiesan V, Panda A. Corneal astigmatism correction with opposite clear corneal incisions or single clear corneal incision: comparative analysis. *J Cataract Refract Surg.* 2006;9:1432-1437.
4. Nichamin LD. Nomogram for limbal relaxing incisions. *J Cataract Refract Surg.* 2006;32:1408.
5. Gills JP. Treating astigmatism at the time of cataract surgery. *Curr Opin Ophthalmol.* 2002;13:2-6.
6. Wang L, Misra M, Koch DD. Peripheral corneal relaxing incisions combined with cataract surgery. *J Cataract Refract Surg.* 2003;29:712-722.