

# Why Cataract and Refractive Surgeons Need the Pentacam

Four surgeons discuss the device's value, including new software additions.

Produced under an unrestricted educational grant from Oculus, Inc..

Extremely accurate anterior and posterior corneal surface measurements  
Keratoconus detection software • Holladay Report for more accurate "Ks" for postrefractive surgery patients receiving IOL implants • Very early cataract detection with exclusive "Densitometry" feature • Accurate post-LASIK ectasia detection  
Accurate anterior chamber measurements aid in proper sizing of ACIOLs

**MICHAEL W. BELIN, MD, FACS, MODERATOR**

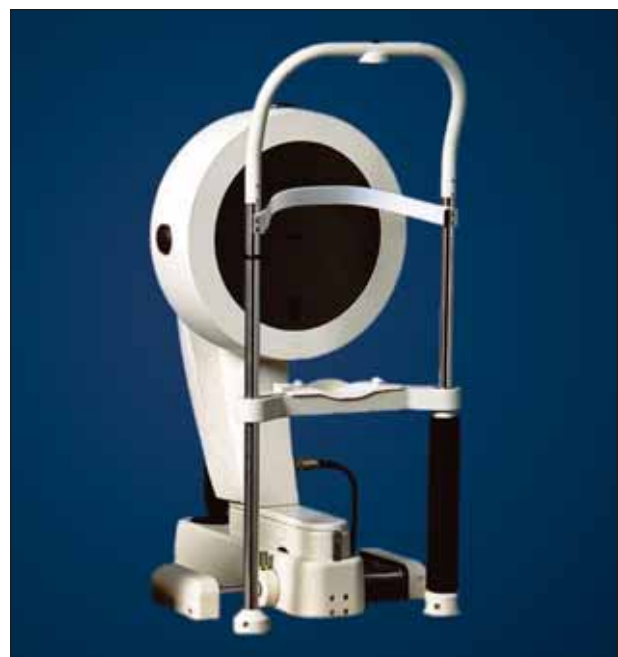**JACK T. HOLLADAY, MD, MSEE, FACS • H. BURKHARD DICK, MD, PhD • RENATO AMBRÓSIO, JR, MD, PhD**

## ***EVALUATING POST-LASIK ECTASIA WITH THE OCULUS PENTACAM***

Front and back corneal measurements improve the accuracy of calculations.

**BY MICHAEL W. BELIN, MD**

Almost 10 years ago, I published an article<sup>1</sup> showing the extreme variability between different topography systems in the analysis of abnormal corneal shapes. Since then, the ability to accurately image the anterior corneal surface has greatly improved. We are now being told, however, that the elevation of the posterior surface is important in diagnosing early keratoconus and post-LASIK ectasia. Currently, two commercially available systems are able to measure back-surface elevation: the Pentacam comprehensive eye scanner (Oculus, Inc., Lynnwood, WA), which is a rotating Scheimpflug device, and the Orbscan corneal topographer (Bausch & Lomb, Rochester, NY), a scanning slit device.



### ELEVATION DATA

The most common way to display elevation data is to compare it to a known shape to amplify the data. The most appropriate shape is a best-fit sphere. The reason for examining corneal data against a best-fit sphere is that raw elevation data on any patient, no matter how pathologic, all look the same, like trying to identify Earth's mountains from space. A topographic picture of the Earth's surface, however, detects the hills and the valleys. Likewise, a best-fit sphere amplifies the corneal surface for the ophthalmologist and is intuitively logical (Figure 1). One may also compare elevation data to other shapes, such as an ellipse or a toric ellipsoid. A distortion map is effectively a best-fit elevation map using a toric ellipsoid. Eliminating the area that can be corrected by a pair of spectacles (a sphere and cylinder) produces, in essence, an irregularity map.

Again, not only is examining the posterior surface important, but many experts have stated that changes in the posterior surface are often missed and that most post-LASIK patients have significant changes on their posterior corneal surfaces.

### DIFFERENCES BETWEEN SYSTEMS

The Orbscan has almost no peer-reviewed literature to support its accuracy in nonspherical, nonsymmetric shapes (what we see clinically), and no peer-reviewed literature has documented the accuracy of that system's posterior data. There are however, numerous articles to show that the Orbscan's postoperative pachymetry is wrong and typically underestimates the corneal thickness by 35 to 40 $\mu$ m. If the anterior surface is relatively easy to map, but the posterior surface is more problematic, and pachymetry is determined by subtracting the posterior surface from the anterior surface, then the error probably is in the posterior surface. Such an underestimation would likely make the posterior surface too anterior or "ectatic" in the post-LASIK patient.

Figure 2 clearly illustrates the differences between pachymetric maps with the Orbscan and the Pentacam. The images are posterior elevations maps of a single patient imaged on the same day after his LASIK surgery. The physician used the same scale and same colors,  $\pm 75\mu$ m. Positive elevation (ectasia) is visible on the Orbscan, but appears completely normal with the Pentacam. Although many Orbscan users would say that up to 50 $\mu$ m of posterior ectasia is normal, it is not. It is a problem with that system. The postoperative picture has the same normal values as the preoperative picture.

When comparing Orbscan and Pentacam images, how do we know which one is correct? Although it is very difficult to validate posterior data, we can compare it to ultra-

sound data, with which the Pentacam has a very good correlation. We also know that, with the Orbscan, the postoperative cornea is 35 to 40 $\mu$ m thinner than corresponding ultrasound values.

Another example between the two systems is one of a patient who was recently referred to me for a buttonhole flap (Figure 3). The patient's central cornea was clear and had undergone no surgery prior to the LASIK procedure that produced the buttonhole, and it was of normal thickness and topography preoperatively. The patient's other eye was completely healthy. No ablation was performed, and because a buttonhole was created, there was no flap in the central cornea. On his postoperative Orbscan, positive elevation (or positive ectasia or displacement of the posterior surface) is visible. On the other hand, the Pentacam image looks completely normal. As this example illustrates, it is mandatory that the hardware be capable of measuring what the ophthalmologist is trying to examine. The Orbscan does not appear capable of measuring postoperative corneas, a fact that is fairly well known.

### ONLY AS GOOD AS THE OPERATOR

Joseph Ciolino, MD, and I studied a series of 124 patients to determine their post-LASIK posterior displacement with elevation topography. We examined the eyes preoperatively and at 1 month postoperatively and calculated the difference. We used a two-display difference map, a preoperative first map and a postoperative second map, and the difference was the third map. We examined 104 LASIK and 20 PRK patients. Because we wanted to use postoperative corneas, we used PRK eyes as our control. The average correction was -3.70D for the LASIK patients and -2.80D for the PRK patients, with a range of -0.90 to -10.10D. Central corneal thickness averaged 546 $\mu$ m for the LASIK patients and 521 $\mu$ m for the PRK patients, with a range of 493 to 617 $\mu$ m. The residual bed averaged 329 $\mu$ m for the LASIK patients and 472 $\mu$ m for the PRK patients, with no calculated residual below 263 $\mu$ m.

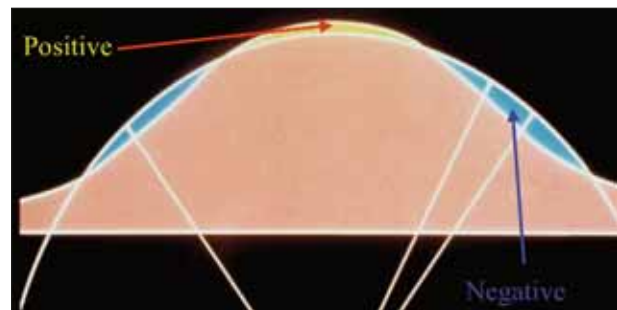


Figure 1. The best-fit display shows the variation from a known shape.

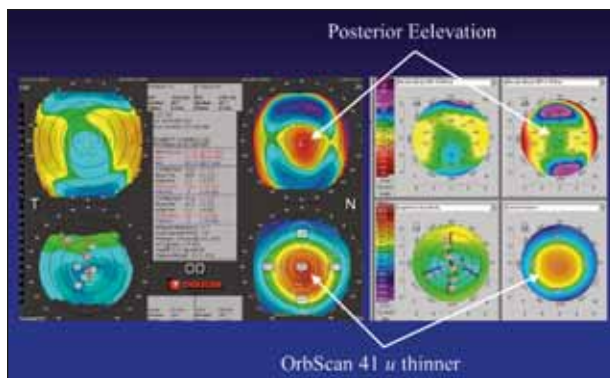


Figure 2. This post-LASIK patient was imaged on the same day with both the Orbscan and Pentacam. The Orbscan reads the central cornea 41 $\mu$ m thinner due to a faulty localization of the posterior corneal surface. The Orbscan shows a posterior surface compatible with an ectasia, whereas the Pentacam reveals a normal posterior surface.

When we analyzed the corneas graphically, it was apparent that there was no difference in the posterior displacement between the LASIK and PRK patients. In other words, within our preoperative parameters, routine posterior displacement after LASIK did not occur. Central corneal thickness, the residual bed's ablation depth, or the residual bed versus the central corneal thickness ratio did not seem to be factors. One has to keep in mind that these findings can only be applied to our patient population. That is, I neither perform LASIK on corneas with a preoperative pachymetry of less than 500 $\mu$ m, nor PRK on corneas with less than 475 $\mu$ m. I typically respect a 275- $\mu$ m post-LASIK residual bed.

I am not suggesting that post-LASIK ectasia does not exist. Obviously, we have all seen it. I am proposing, however, that its frequency has been greatly exaggerated and that, like keratoconus with placido systems, some elevation systems are associated with a very high false-positive rate.

### ASTIGMATISM VERSUS ECTASIA

I think one issue about which people get very confused is astigmatism versus ectasia. Ectasia is an island of positive deviation in the central or paracentral region of the cornea on the elevation map, whereas astigmatism has its maximum deviation in the periphery. The higher the degree of astigmatism, the greater the peripheral deviation, elevated on the flat axis (positive) and depressed on the steep axis (negative deviation). It is also important to look at the pachymetric map, not just in the thinnest region but to evaluate the pachymetric distribution. A normal cornea is thinnest in the center. Although nothing is absolute, I use greater than 12 $\mu$ m of central anterior

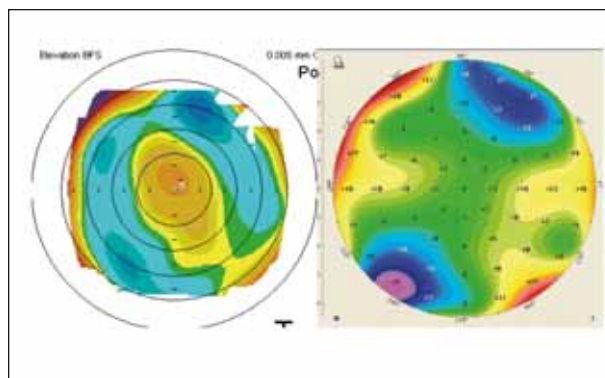


Figure 3. This patient was referred after sustaining a button-hole. No ablation was performed, and his preoperative topography was completely normal. Although no tissue was removed, the Orbscan map shows a dramatic shift in the posterior elevation, whereas the Pentacam map shows a completely normal, unaltered posterior surface.

elevation as abnormal and greater than 15 $\mu$ m on the posterior surface. If there is a gray zone, such as 10 $\mu$ m of anterior elevation and 12 $\mu$ m of posterior, but the pachymetric map is also displaced toward the cone, then this is much more suspicious. I rarely look at curvature maps for keratoconus, because an abnormal curvature map does not imply keratoconus. A false-positive may occur with a displaced apex, which will not affect elevation but will significantly affect curvature maps.

An accurate examination of the posterior corneal surface is important. No one would look at half an X-ray; likewise, we should not rely on an analysis that only reports on half of the cornea. In the past, assessing the posterior corneal surface was problematic, particularly in the postoperative or distorted cornea. The Pentacam's unique imaging system, which uses a rotating Scheimpflug camera, appears capable of accurately assessing both the anterior and posterior corneal surfaces, both pre- and postoperatively. The Pentacam enables the ophthalmologist to better diagnose ectatic disorders and to better quantify the normal postoperative cornea.

*Michael W. Belin, MD, is Professor of Ophthalmology and Director of Cornea & Refractive Surgery at the Albany Medical Center Lions Eye Institute and is Adjunct Professor of Ophthalmology at the University of Ottawa in Canada. He has received travel support and honoraria from Alcon Laboratories, Inc., and Oculus, Inc. Dr. Belin may be reached at (518) 475-1515.*

1. Belin MW, Ratliff CD. Evaluating data acquisition and smoothing functions of currently available videokeratoscopes. *J Cataract Refract Surg.* 1996;22:421-426.

## MEASURING CORNEAL POWER AFTER CORNEAL REFRACTIVE SURGERY

How the Pentacam improves the accuracy of these calculations.

BY JACK T. HOLLADAY, MD, MSEE, FACS

I have used the Pentacam comprehensive eye scanner (Oculus, Inc., Lynnwood, WA) for more than 1 year, ever since I saw how well it measured the front and back surfaces of the cornea. As most surgeons know, the difference between topography and tomography is that topography measures the surface of the cornea, whereas tomography measures its three-dimensional thickness.

The Pentacam is a rotational Scheimpflug device, and the Orbscan corneal topographer (Bausch & Lomb, Rochester, NY) is a translational device. The major difference between the two is that the Pentacam takes images of 50 meridional sections through the center of the cornea. This approach allows the system to realign the central thinnest point of each section before it reconstructs the corneal image, thus eliminating any eye movement that occurs during the examination (Figure 1). The Pentacam is the only device that rotates around a common axis and thus allows the user to toggle down through each meridional image to see if there is a blinking eyelid or some other type of movement that degrades the image's quality for that meridian.

### REVIEWING THE BASICS

In addition to providing an image of each section, the Pentacam gives densitometry readings related to the amount of scattered light (Figure 2). The result is that the user may know the density of the crystalline lens and objectively measure the amount of its cataractous changes. The Pentacam can map any structure in the anterior segment that is not opaque. For example, the ciliary sulcus cannot be imaged in dark brown eyes, because the pigment epithelium of the iris is opaque.

### PERFECTING CALCULATIONS

The Pentacam allows users to take direct measurements of the power of the cornea, thus avoiding the two problems that plague keratometers and topographers and cause errors, especially with IOL calculations in patients who have undergone refractive surgery. The first problem is that keratometry and topography cannot sample the central 2mm of the cornea, which is the most important

area. Topographers and keratometers have a camera or viewer in their centers that obscures the central area (1.8mm for a topographer and the central 3mm for a keratometer). This first error results in a 15% error of the refractive change from refractive surgery for the keratometer and an error of about 5% for the topographer.

The second error with LASIK and PRK relates to the change in the ratio of the back-to-front radius of the curvatures, which is normally 82%. This error accounts for approximately 10% of the refractive change from refractive surgery. The total is therefore about a 25% (15% + 10%) error in the refractive change for keratometry and approximately 15% (5% + 10%) for topography using the central refractive power. So, if a patient experienced a 10.00D refractive change from refractive surgery, then the keratometer would make a 2.50D error, and the topographer would make a 1.50D error in the measured corneal power. This is the reason why surgeons do not achieve accurate corneal measurements with topographers or keratometers following refractive surgery.

There is one additional problem with keratometry that must be addressed. Ophthalmologists have always reported keratometric power, not the true net power of the cornea, within IOL calculations. When a 45.00D keratometric reading is reported, surgeons assume that the standardized keratometric index of refraction of 1.3375 has been used and that the corresponding anterior corneal radius of curvature is 7.5mm. All IOL calculation formulas reduce the reported keratometric power by approximately 2% (approximately 0.75D) to achieve the average net power that has been determined for normal corneas in true net power studies. Therefore, the actual power used in the vergence calculation is approximately 44.25D, when the keratometric power

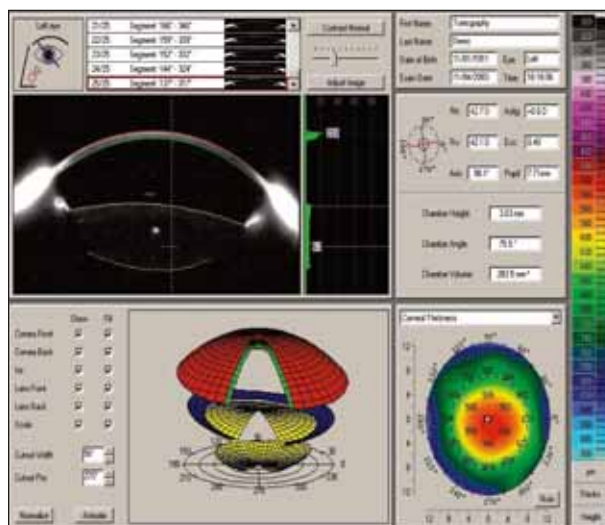


Figure 1. The system allows a three-dimensional display with the ability to toggle through each meridional section.

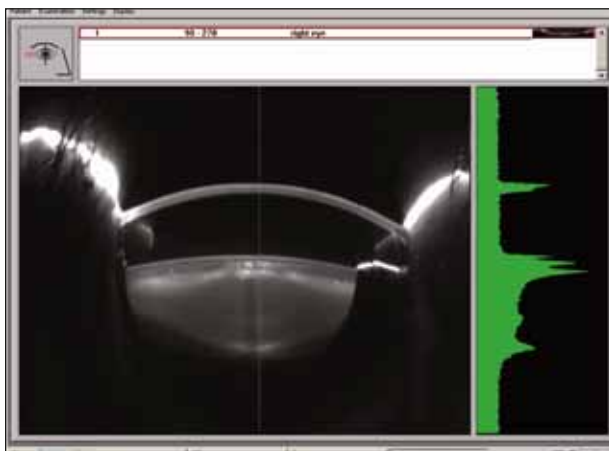


Figure 2. The Pentacam's densitometry readings measure the density of the crystalline lens and objectively measure the amount of its cataractous changes.

measures 45.00D. The Pentacam can report the net power (44.25D), but IOL calculation formulas would reduce the power by 0.75D to 43.50D and create a new error from double compensating the value. The Pentacam therefore reports the equivalent K-reading, which would be 45.00D in the normal patient with no refractive surgery (the same as with keratometry and topography).

### TREATMENT RANGE AND FOCUS

For IOL calculations with the Pentacam, what area should be used to determine the corneal power? The device has parameters in a zone from 2 to 12mm that can be used. We must first determine the size zone, or diameter (not the radius), for which we want to know the net power. When the Pentacam was first developed, I conducted a study with Andreas Steinmueller of Oculus Optikgeraete GmbH (Wetzlar, Germany) to determine the answer to this question.

We first calculated the power of a preoperative cornea with the Pentacam, a Humphrey Atlas Topography System (Carl Zeiss Meditec Inc., Dublin, CA), and an Eyesys 2000 Corneal Analysis System (Eyesys Vision, Houston, TX). The three systems agreed on the same measurement within approximately 0.03D. Then, we enrolled 50 patients (100 eyes) who had undergone LASIK or PRK and whose refractions ranged from +3.00 to -8.00D, and we recorded their refractive changes at 3 months. We vertexed the measured refractive change to the cornea at 3 months and subtracted it from the patients' preoperative corneal power. Next, we correlated these measurements with the Pentacam over various treatment zones. The 4-mm zone had the best agreement of the measured corneal power with the calculated power. In retrospect, this finding is consistent with previous studies because, when correlating refraction with wavefront

### PACHYMETRY IN POST-LASIK PATIENTS

Surgeons should always regard the pachymetry in post-LASIK patients taken at 3 months with suspicion, because the reading depends on the amount of interface scatterer present, which may not be due to scarring. It takes 1 to 2 months for the cornea to pump out all of the fluids in the space underneath the LASIK flap. This fluid makes the flap somewhat edematous, which produces forward light scatter that causes people to see halos. It is similar to the kind of edema caused by contact lenses.

aberrometry, refractometry, and retinoscopy, the highest correlation is always between 4.0 and 4.5mm. Sampling a zone smaller than 4mm excludes too much of the pupil through which the rays are passing. Alternatively, with a zone larger than 5mm, the Stiles Crawford effect weighs the rays beyond 5mm so little that they contribute very slightly to the retinal image and are therefore not important.

### THE PENTACAM'S REPORTS

In designing the Holladay Report that the Pentacam generates, Andreas and I wanted all of the patient's information available to the physician on one report. Therefore, we included a map for refractive power and one displaying the tangential (which is a poor name; it is really the local radius of curvature). The refractive power map uses Snell's law and shows positive spherical aberration. Any change in a patient's refraction will be exactly related to the change in the topographic map.

We also included a tangential curvature map. It does not use Snell's law; it only gives the local radius at every point on the surface. These kinds of data are also called *instantaneous radius of curvature*, because they illustrate




Figure 3. The Pentacam correlates the measured corneal power and the calculated power.

the radius of curvature of every little bump instantaneously. The map does not reflect the change in refractive power, but it will reveal such things as flat spots in the periphery, a capability that makes it a valuable tool.

The lower maps in the Pentacam's report show elevation. They become important when discussing terms such as *best-fit sphere*. Using positive and negative reference points, the map illustrates the height of an area on the cornea relative to a best-fit sphere. It will also compare these points to shapes other than a sphere, such as an aspheric shape or Q values.

The back surface float on the Pentacam's report details the back curvature of the cornea and helps the surgeon determine its elevation. The posterior float on the Pentacam is far more accurate than on the Orbscan, but it is still not as accurate as the Pentacam's front curvature. One reason is that the posterior curvature is a virtual image seen through the optics of the front of the cornea and stroma and their thicknesses and curvatures. Therefore, to determine the precise back curvature of the cornea, one needs to know its exact index of refraction, of which there is a gradient in the cornea. Minute errors ultimately have a minimal effect on back-surface pachymetry, but the curvature is usually accurate to within 10 to 12 $\mu$ m. On the Orbscan, the float is accurate to within 20 $\mu$ m. On the Pentacam's posterior float, only changes greater than 10 to 12 $\mu$ m are significant. Once we determined that the 4-mm measurement zone was optimal, we again performed the correlation between the measured corneal power and the calculated power, and we achieved an R2 of 96%, which was  $\pm 0.55$ D of the corneal power (Figure 3).

*Jack T. Holladay, MD, MSEE, FACS, is Clinical Professor of Ophthalmology at Baylor College of Medicine in Houston and is a consultant for Oculus, Inc. He may be reached at (713) 668-7337; docholladay@docholladay.com and www.docholladay.com.*

### ANTERIOR SEGMENT ANALYSIS FOR PHAKIC IOL IMPLANTATION

The information that the device supplies allows surgeons to serve patients better.

**BY H. BURKHARD DICK, MD, PhD**

Preoperative planning for phakic IOL implantation is of the utmost importance in order to exclude poor candidates who do not have optimal intraocular space

for this kind of lens. Many phakic IOLs, such as toric lenses, require precise implantation in terms of the location of enclavation to the iris. As most surgeons know, the more a lens is displaced from the target axis, the greater the induced astigmatism is. For example, even 15° of displacement equals approximately a 50% reduction in the quality of the refractive effect. To optimize our placement of these lenses, our department uses two Pentacam comprehensive eye scanners (Oculus, Inc., Lynnwood, WA).

### PREOPERATIVE CALCULATIONS

To illustrate the value of the Pentacam, one patient of mine had a preoperative refraction of +7.00D sphere combined with -3.00D of astigmatism, so he had spherical aberration and a spherical equivalent refraction of +5.50D. Is he a good candidate for refractive lens exchange or phakic lens implantation? The latter requires sufficient space in the anterior chamber and would be a good option if the patient could not accommodate. The Pentacam showed that this patient's eye had a small peripheral anterior chamber. Regarding the depth of the anterior chamber, the distance from the peripheral optic is more important than the central distance (the anterior chamber depth). The ophthalmic literature and training courses for phakic IOLs refer to the central anterior chamber depth but stress the importance of the peripheral depth, because these IOLs' periphery is closer to the endothelium. The space is important to avoid any intermittent touching of the

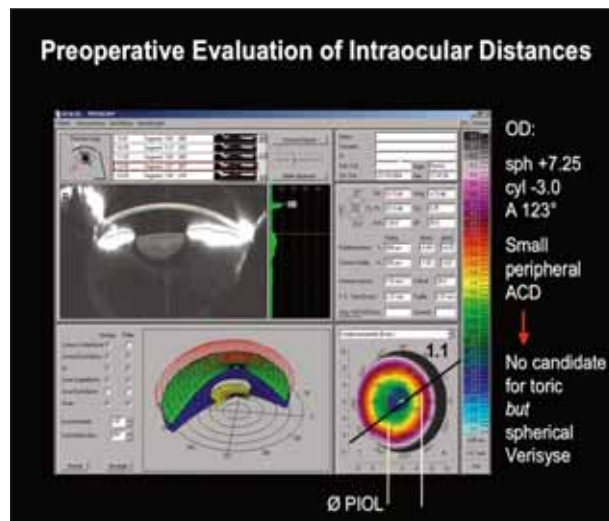


Figure 1. For this eye with a refractive error of +7.25 comb. -3 at 123°, the Pentacam demonstrates that there is insufficient space for a toric phakic IOL in the peripheral anterior chamber at the target implantation axis but enough space at the horizontal meridian for phakic lens implantation.

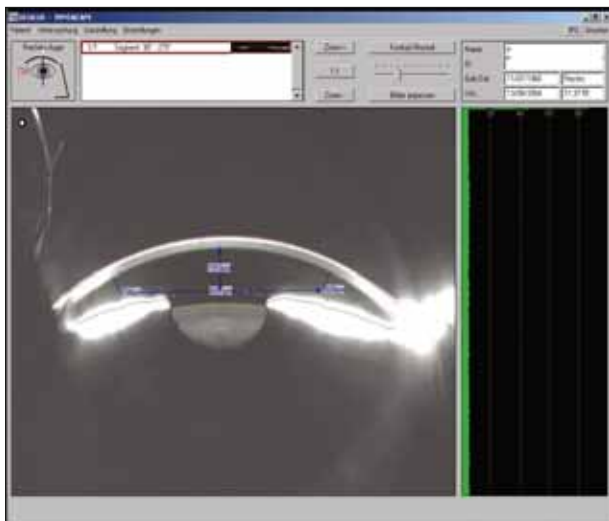


Figure 2. Determination of the safety distances after phakic IOL implantation in a myopic eye operated elsewhere. Obviously, the safety distances are already smaller than allowed, underlining the necessity to perform Pentacam evaluations in the future follow-up.

lens if the patient rubs his eyes, for example, which might induce continuous endothelial cell loss. A safe amount of space for this kind of lens is a minimum of 1mm in the periphery. The central anterior chamber depth should be approximately 3mm, according to phakic IOL manufacturers. However, anterior chamber depth does not tell the surgeon everything, because the smallest distance has to be the exclusion criterion, and this distance is found in the periphery only. The Pentacam nicely addresses this point. The user simply implements an 8.5-mm line into the Scheimpflug image that represents the overall diameter of the phakic IOL. He can then measure the eye's shortest distance between the IOL's optic and the endothelium manually. Using this method, the surgeon can easily decide if the patient is an appropriate candidate for toric lens implantation.

### ADDITIONAL APPLICATIONS

Surgeons planning to reduce astigmatism may analyze incisional architecture with the Pentacam, because the device provides a topographic map of both sides of the cornea as well as a pachymetric map. However, what is most important is the way in which the Pentacam aids in the postoperative evaluation of safety issues. With age, the anterior segment grows smaller, and the crystalline lens thickens. What is much more important is the closest distance from the optic's periphery to the endothelium, because myopic lenses

are always thicker in the periphery. Highly myopic eyes have great side height. I do not recommend taking the perpendicular measurement between the phakic IOL and the endothelium in the periphery, but rather the shortest distance. The Pentacam allows the surgeon to quickly see the closest distance. Interestingly, when my colleagues and I took some measurements with the Pentacam, the more important peripheral measurement was always smaller than the central measurement.

Another particular case illustrates the Pentacam's usefulness well. The patient presented for phakic lens implantation. Based on his slit-lamp examination, my staff and I were convinced that he was a good candidate for implantation with a Verisyse phakic IOL (Advanced Medical Optics, Inc., Santa Ana, CA). Although the implantation was successful, during a routine postoperative check, we performed an examination with the Pentacam (which was not available in our office prior to the implantation) that revealed synechiae posterior to the iris. The iris bulged slightly anteriorly, and the space from the endothelium to the iris was small. Again, based on the slit-lamp examination alone, we were confident of this patient's candidacy for a phakic implant, but the Scheimpflug image of the Pentacam provided information that would have excluded this patient from this procedure. With the Verisyse IOL, there is a tiny but important distance between the iris, the pupil, and the internal margin of the optic. The central thickness of the anterior chamber of this patient's eye was 3.2mm, but the peripheral distance was just below the safety distance at 900 $\mu$ m. Thus, the patient definitely was not a perfect candidate for implantation with this -9.00D lens.

### PRAISE FOR THE PENTACAM

In conclusion, the Pentacam is more comfortable for patients than other measurement devices. It operates very quickly, gives immediate results, and is extremely easy to use (it may be operated by anyone in the office). It also has the potential for many new applications. I feel it is a great addition to my clinical practice; it has become an irreplaceable tool, because I no longer implant any phakic IOLs without checking the results that the Pentacam provides. ●

*H. Burkhard Dick, MD, PhD, is Clinical Professor and Head Physician for the Department of Ophthalmology, Johannes Gutenberg-University, Mainz, Germany. He acknowledged no financial interest in any product or company mentioned herein. Professor Dick may be reached at +49 61 31175445; bdick@mail.uni-mainz.de.*

## ECTASIA DETECTION AND CLASSIFICATION WITH CORNEAL TOMOGRAPHY

How this technology complements topography and thus increases the safety of refractive surgery.

BY RENATO AMBRÓSIO, JR, MD, PhD

In today's world of refractive surgery, screening patients preoperatively for a predisposition to developing severe complications such as postoperative ectasia is vitally important. One of the most high-profile examples of this problem was covered in the October 2005 issue of *Cataract & Refractive Surgery Today*, "Anatomy of a Lawsuit II."<sup>1</sup> The Schiffer-Speaker trial was a very sad situation in which a highly skilled surgeon with a very good reputation treated a patient who experienced ectasia after LASIK, and the result led to a disastrous \$7.25 million lawsuit. The case illustrates the risk of developing ectasia after LASIK, even when corneal topography and pachymetry readings—the current standard of care for the preoperative evaluation of refractive candidates—are considered normal. Although other similar medicolegal cases have been reported in the peer-reviewed literature,<sup>2</sup> the exact scope of this problem is unknown, because the majority of cases are not reported. Thus, we must identify the need for improving the screening process for refractive candidates if we are to raise the bar for safety in refractive surgery. It is critical to identify patients who are at risk for ectasia, and any suspicious signs should be considered contraindications for LASIK.

To this end, technologies such as the Pentacam comprehensive eye scanner (Oculus, Inc., Lynnwood, WA) are raising the bar. The Pentacam is a tomographer, which is different than placido-disc topography. A tomographer enables a mathematical reconstruction of the internal picture of the element studied, whereas topographers study its surface exclusively. Corneal tomography goes beyond topography and pachymetry in a preoperative examination. Corneal tomography enables a three-dimensional corneal reconstruction, which evaluates its anterior and posterior curvatures and creates a pachymetric map. This map gives the thinnest point's value and location, whereas ultrasound pachymetry evaluates a single point at the center of the cornea, which might not be the thinnest one. However, the technologies are complementary. For example, the evaluation of the integrity and stability of the tear film and the corneal surface provided by the reflection of the placido rings still gives very useful clinical data. I wish that, on the podium, speakers

would refer to these devices by their technological names rather than brand names to help others understand the different tasks they perform. The Orbscan (Bausch & Lomb, Rochester, NY) was the first tomographer clinically available, and subsequent devices such as the Pentacam have improved upon it.

## THE PROGRESSION OF CORNEAL THICKNESS FOR IDENTIFYING KERATOCONUS

*Keratoconus* is a noninflammatory pathologic condition characterized by progressive thinning and protrusion of the cornea. The thinning process occurs in one particular area so that the surrounding area remains disproportionately thicker. Physiologically, the normal cornea is thinner in its center and thicker in the periphery. I hypothesize that the gradual increase of the corneal thickness from the center toward the periphery in healthy eyes falls within a normal range and that this characteristic could lead to a criterion for identifying pathology such as ectasia.

Based on this theory, I conducted studies with certain colleagues that revealed significant differences between keratoconic and normal corneas using different tomographic systems. I performed the first study in 2003 using the Orbscan II at the Hospital de Olhos de Sergipe in Brazil with Mario Ursulino, MD, and Allan Luz, MD. In this study, we analyzed 100 normal eyes and 25 eyes with mild keratoconus. Using the pachymetric numeric map (0.92), we identified and recorded the thinnest point. Also, we manually drew several circles concentric to the thinnest point with radii that increased at 1-mm steps up to 7mm. We calculated and recorded the average of the thickness values of the points located within each circle so that we could create a graph for the progression of corneal thickness from the thinnest point toward the periphery for each eye. This approach enabled us to study the rate of increase for each eye proportionally from the thinnest point. We were very impressed by how the lines created were parallel in normal eyes. When we applied statistical tests, we found significant differences in the pachymetric progression between normal eyes and early keratoconic eyes at all positions. Interestingly, there were some cases with early keratoconus evident on the anterior corneal maps that had normal posterior elevation maps and a peak-to-valley difference of less than 0.100 $\mu$ m using the best-fit sphere. Thus, we observed that pachymetric progression data could provide information to identify ectasia and add to the surgeon's armamentarium in the preoperative screening process. Such information would help indicate the risk of postoperative ectasia, which might be much higher than what was previously thought.



**ECTASIA DETECTION: IS THE PACHYMETRIC PROGRESSION MORE SENSITIVE?**

Classically, corneal topography is considered the most sensitive method for detecting ectasia. More than half of the cases of keratoconus and pellucid marginal degeneration identified among refractive candidates by corneal topography had normal eye examinations, including nor-

mal BCVA.<sup>3</sup> However, the condition first induces structural changes on the cornea that might be detectable with tomography before the condition becomes evident on the surface with topography. Some cases considered unilateral keratoconus serve as excellent examples for this point (Figure 1). Although keratoconus is a bilateral disease, in some cases, there is evidence of it in only one eye.

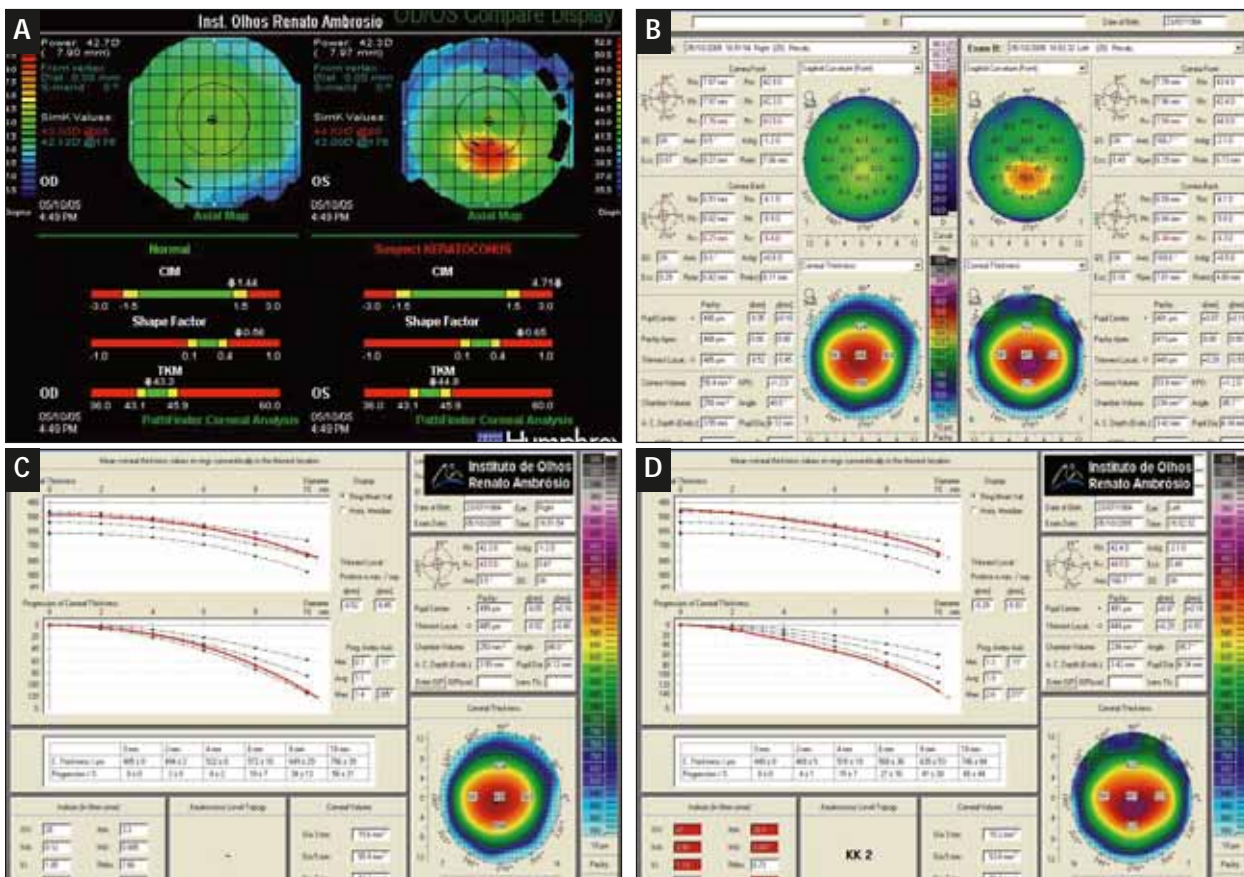


Figure 1. This 26-year-old male patient with a history of unilateral keratoconus was referred to me for a second opinion. Both eyes had myopic astigmatism with BSCVAs of 20/20+. Corneal topography detected ectasia OS and a normal pattern OD (A). Comparing front sagittal (axial) and pachymetric maps provided by the Pentacam clearly illustrated the asymmetry between his eyes (B). Corneal pachymetric progression detected an abrupt increase of the thickness values from the thinnest point (485µm, located 0.52µm temporally and 0.45µm inferiorly) toward the limbus OD (C). Note the progression of corneal thickness on the graph with the line very close to the limit. The artificial intelligence indices for an 8-mm zone from the anterior cornea are all normal for the detection of ectasia. In his left eye, a typical abrupt increase in the pachymetric values is seen from the thinnest point (449µm, located 0.29µm temporally and 0.93µm inferiorly) toward the limbus. The artificial intelligence indices for an 8-mm zone from the anterior cornea also detect keratoconus, grade 2 (D). Interestingly, corneal hysteresis and the corneal resistance factor, measured with the Ocular Response Analyzer (Reichert Ophthalmic Instruments, Depew, NY), were low in both eyes. Corneal hysteresis was 9.8mmHg OD and 9.1mmHg OS. The corneal resistance factor was 7.74mmHg OD and 7.23mmHg OS. In normal corneas, corneal hysteresis has a mean of 11.9mmHg (range, 7.63 to 17.9mmHg), and a standard deviation of 1.97. The corneal resistance factor has a mean of 11.4mmHg (range, 6.19 to 16.81mmHg) with a standard deviation of 2.07. The diagnosis is truly form fruste keratoconus OD and early keratoconus OS. Because early changes were detected OD, the term *unilateral keratoconus* is misleading. Experienced clinicians may note an increase in corneal asphericity, but the changes are very slight or even undetectable by corneal topography (placido) OD. Other such cases in which both eyes show very early forms of ectasia could be refractive surgery candidates who are at high risk for iatrogenic post-LASIK progressive ectasia.

Generally, this is not true unilateral keratoconus, but asymmetrical. True unilateral keratoconus is very rare and, in most cases, related to trauma to one eye. In most of these cases, the contralateral eye with a normal anterior surface might already have developed some changes in the pachymetric map that are detectable using the functions we are developing.

The evaluation of the posterior corneal elevation might also reflect early structural changes as observed in several studies using corneal tomography with the Orbscan.<sup>4</sup> However, the need for using a reference plane such as the best-fit sphere makes this approach less than optimal. Even by employing a better reference to fit the corneal contour, such as a toric or an ellipsoid, the map created is artificially affected by the reference plane used. This is the main reason why the pachymetric map is so important. It considers data from the anterior and posterior cornea and reflects the architecture of the corneal tissue.

### **PACHYMETRY'S FUNCTION**

The Pentacam has implemented several functions to better describe corneal thickness data. Pachymetric evaluation gives us two important insights. The first is locating the correct thinnest point of the cornea and its value. The distance and position of the thinnest point relative to the apex of the cornea are important characteristics. It is not uncommon to find cases in which the ultrasound data are higher than the thinnest point detected by the Pentacam. By repeating the ultrasound measurement at the location detected on the map, we find a lower value than the one at the corneal center. For example, one patient of mine who was going to undergo LASIK for approximately -6.00D of myopia appeared to have 510 $\mu$ m of central corneal thickness with pachymetry by ultrasound, but the Pentacam revealed an area that had less than 490 $\mu$ m of thickness inferiorly, which was further confirmed by careful regional ultrasound pachymetry. Interestingly, the central cornea had 509 $\mu$ m of thickness on the map, in agreement with the value first found by the ultrasound probe. It is critical to note that only because of the pachymetric map did I find the thinnest spot. This was actually my first day of using the Pentacam. This patient had been a friend of mine since high school, so this information was critical to my decision not to perform LASIK. Based on normal corneal topography, I discussed the patient's options with him and opted for customized wavefront-guided surface ablation. He fared very well in both eyes. I would not have been able to explain it if this patient had developed postoperative ectasia after LASIK, which, considering the thinnest value, would have been a significant risk. The mistaken detection of the thinnest point of the cornea is a possi-

### **NEW METHOD OF SURFACE ABLATION**

Paolo Vinciguerra, MD, of Milan, Italy, will present this year a new, aggressive method of surface ablation in which he ablates deeply in the cornea and leaves a very thin residual bed. He uses a homogenous area of thinning and a large treatment zone, which leaves the cornea more biomechanically stable and more receptive to biomechanical evaluation. I believe that this technique is another advancement in refractive surgery.

ble explanation in eyes that develop iatrogenic ectasia after LASIK despite normal corneal topography and pachymetry.

This case illustrates why I believe that the standard of care today should include the tomographic evaluation of the cornea with a pachymetric map. I believe that the Pentacam is the best tomographer currently available, because one can rely on the data it provides from multiple Scheimpflug images. The examiner can analyze each image and evaluate the edge detection to confirm accuracy. This step is impossible or else very difficult to perform using other tomography systems. Additionally, my colleagues and I have conducted studies comparing the Pentacam data and central ultrasound measurements, and we have found a very high similarity with an R2 value higher than 0.9.

The Pentacam is also useful in differentiating and classifying various types of ectasia. Pellucid marginal degeneration has different features than keratoconus, and this knowledge is important for clinicians as well as for academia.<sup>5</sup> Treating these conditions with contact lenses or corneal surgery, including the implantation of intrastromal ring segments and keratoplasty, is very different. These features are easily recognized by corneal tomography maps (Figure 2A and B).

Furthermore, one can use the Pentacam's data to plan a corneal transplant according to the location of the ectasia on the cornea. It also allows surgeons to plan and prepare for implanting intrastromal ring segments, determine the depth of the incisions, and develop customized nomograms for improving outcomes.

### **ROOM FOR BOTH TECHNOLOGIES**

It is important to note that corneal placido-based topography will not be eclipsed by tomography; they complement each other, and one should not be substi-

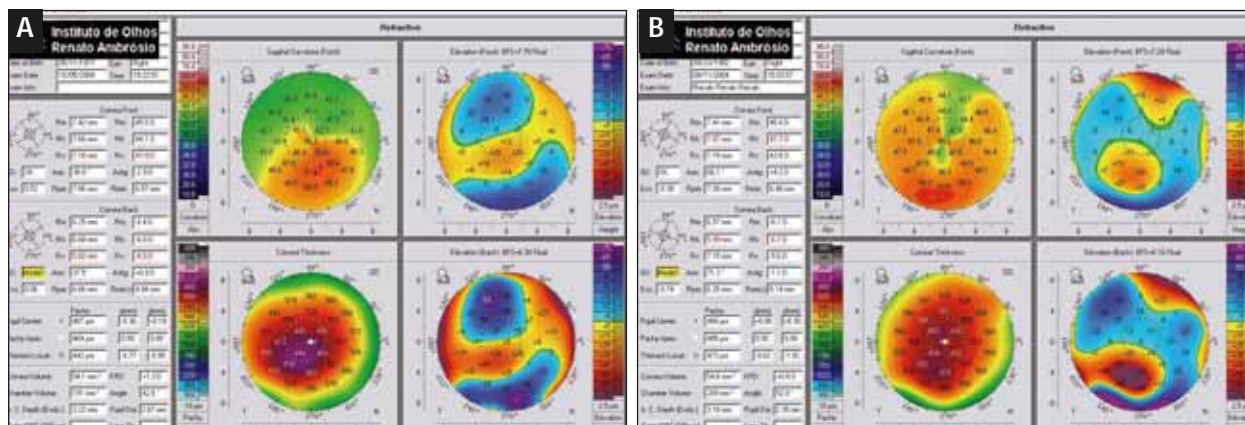


Figure 2. These images show keratoconus (A) and pellucid marginal degeneration (B).

tuted for the other. Topography has its purpose; it is still crucial for evaluating the corneal surface, and it also has advantages for examining the tear film. There are many circumstances in which topography gives more detail for surface evaluation. Nevertheless, corneal tomography and biomechanical measurements will certainly increase the detection of poor candidates for refractive surgery and thus avoid postoperative disasters (and lawsuits).

I believe that ectasia is more likely to occur with lamellar surgery, and I prefer to perform surface ablation if I suspect any problems related to the architecture of the cornea. Proceeding with PRK, LASEK, Epi-LASIK, or other types of surface ablation may suffice, but the bottom line is never perform LASIK on a suspicious cornea, because flap creation by itself disrupts the corneal structure. In my opinion, patients with definitive or suspicious signs of ectasia need to be well oriented. I usually tell patients that customized surface ablation could be an option, mainly if the cornea and eye's total wavefront measurements are stable over time (for

at least 1 year). I also explain that there is a risk of ectasia progression, with, without, or even despite refractive surgery. ●

*Renato Ambrósio, Jr, MD, PhD, is Director of Cornea and Refractive Surgery at the Instituto de Olhos Renato Ambrósio and Refracta-RIO and Clinical Assistant Professor at the Fluminense Federal University in Rio de Janeiro, Brazil. He is a consultant for Oculus, Inc., but acknowledged no direct financial interest in any product or technology discussed herein. Dr. Ambrósio may be reached at: 55-21-2234-4233; renatoambrosiojr@terra.com.br.*

1. McDermott G, Krafczek AB. Anatomy of a lawsuit II. *Cataract & Refractive Surgery Today*. 2005;5:10:75-104.
2. Binder PS, Lindstrom RL, Stulting RD, et al. Keratoconus and corneal ectasia after LASIK. *J Refract Surg*. 2005;21:6:749-752.
3. Ambrosio R Jr, Klyce SD, Wilson SE. Corneal topographic and pachymetric screening of keratorefractive patients. *J Refract Surg*. 2003;19:1:24-29.
4. Cairns G, McGhee CN. Orbscan computerized topography: attributes, applications, and limitations. *J Cataract Refract Surg*. 2005;31:1:205-220.
5. Ambrosio JR, Klyce SD, Smolek MK, Wilson SE. Pellucid marginal corneal degeneration. *J Refract Surg*. 2002;18:1:86-88.

# Cataract & Refractive Surgery

TODAY!

**German precision and innovation goes into every Oculus Instrument.**  
*The results are reliable, well-designed, accurate diagnostic devices that help eyecare professionals see more patients, obtain better repeatable readings, and ultimately grow a more efficient practice.*

1-888-284-8004  
[www.OculusUSA.com](http://www.OculusUSA.com)  
[Sales@OculusUSA.com](mailto:Sales@OculusUSA.com)

