

# CRST

Cataract & Refractive Surgery Today

## A new MIGS on the block?



Performed as a standalone procedure or as an adjunct to cataract surgery, ABiC—canaloplasty performed in an ab interno approach to Schlemm canal—is a new MIGS procedure that can comprehensively restore the natural outflow pathways for your glaucoma patients.

*Ab interno canaloplasty (ABiC, as developed by Ellex) is a new, comprehensive MIGS procedure. Performed via a self-sealing, clear corneal incision, ABiC conserves the clinically proven benefits of 360° viscodilation of Schlemm canal provided by traditional canaloplasty, but with the speed and ease of implementation of a MIGS procedure. Unlike other currently available MIGS procedures, however, ABiC preserves tissue and does not require the permanent placement of an implant in the eye. It has also been shown to be effective as both a standalone procedure and when combined with cataract surgery. In short, ABiC may finally be the answer ophthalmic surgeons have been waiting for—a MIGS procedure that flushes out the eye's natural outflow channels, without damaging tissue and without leaving behind a stent or shunt.*

Primary open-angle glaucoma (POAG) is a sight-threatening condition caused by suboptimal ocular outflow that leads to elevated IOP. Although topical eye drops have long been the mainstay treatment of glaucoma, the efficacy of this approach not only varies greatly between patients, but it seldom yields the results expected, because of poor patient compliance.<sup>1</sup> Also, the chronic use of anti-glaucoma medications can lead to a host of ocular side effects such as itching, burning, and a change in iris color, as well as systemic side effects such as headaches, pain, and depression.<sup>2-4</sup>

Whereas conventional surgical interventions such as aqueous shunts and trabeculectomy are effective in lowering IOP and are still widely used, they can be associated with numerous intra- and postoperative complications and safety issues. Thus, they are usually reserved for late-stage glaucoma or patients who need to achieve very low levels of pressure.<sup>5,6</sup>

Consequently, physicians are increasingly turning toward nonpenetrating, bleb-free, minimally invasive glaucoma surgery (MIGS) procedures for their early- or mid-stage glaucoma patients. MIGS is defined as an FDA-approved, minimally invasive, ab interno procedure that is performed through a small incision (usually through the cornea) that spares the conjunctiva.

### MIGS: A NEW PHILOSOPHY OF TREATING GLAUCOMA

The advent of MIGS has substantially changed the way physicians treat glaucoma patients, with glaucoma now treated as a surgical disease in its early stages. Indeed, today, physicians are considering glaucoma surgery in much the same way as they do medical or laser therapy.

Historically, glaucoma surgery was reserved for patients who were losing vision despite maximal medical therapy. Treating it as a last resort was appropriate, because of the high risks associated with trabeculectomy and tube shunt surgery. The hallmark of MIGS, however, is its safety profile.<sup>7</sup> Therefore, MIGS challenges ophthalmologists to consider it as a valid treatment option in cases of mild-to-moderate glaucoma. For example, in the past, a patient with early glaucoma who had well-controlled IOP on one or two medications would not have been a candidate for surgical glaucoma treatment. Today, this patient could undergo a MIGS procedure at the time of cataract surgery with the goal of reducing the need for ongoing glaucoma medications. This is a very different strategy from performing a trabeculectomy with

the goal of helping a patient with advanced glaucoma discontinue or reduce the number of medications needed to control IOP.

### CANALOPLASTY

With 10 years of clinical experience behind it, canaloplasty has been proven to be a highly effective and safe surgical technique for treating POAG. To date, the procedure has been evaluated in more than 60 peer-reviewed clinical studies and performed in more than 60,000 procedures worldwide.

As a restorative procedure, canaloplasty uses patented microcatheter technology (iTrack by Ellex) to restore the function of the eye's natural outflow system. Unlike trabeculectomy, which works by bypassing the trabecular meshwork, canaloplasty specifically addresses all areas of potential "blockage" in the eye's natural outflow system. By addressing all of the possible sites of resistance, including potentially occluded collector channels, canaloplasty delivers a significant degree of IOP reduction and has been shown to be as effective as trabeculectomy in reducing IOP.<sup>8</sup> While the IOP-lowering benefits of canaloplasty and trabeculectomy are similar, the safety profiles of the two techniques are vastly different.<sup>9</sup>

One of canaloplasty's most significant advantages is that it works without a filtering bleb, which leads to more predictable outcomes and easier postoperative management. Indeed, canaloplasty has a better safety profile than trabeculectomy<sup>9</sup> and enables surgeons to reduce or eliminate many of the intra- and postoperative complications associated with the latter procedure, including restrictions on lifestyle, ocular discomfort, over- and under-scarring of the bleb, and infection.

### INTRODUCING ABiC

The latest evolution in canaloplasty is ABiC, a subtle but significant refinement of traditional (ab externo) canaloplasty. Like traditional canaloplasty, ABiC addresses the trabecular meshwork, Schlemm canal, and collector channels. It follows the same dilation principles of traditional canaloplasty, where the controlled delivery of Healon/Healon GV (Abbott Medical Optics) during withdrawal of the iTrack microcatheter creates microperforations in the trabecular meshwork and separation of the compressed tissue planes within Schlemm canal. The procedure pulls any herniated inner wall and juxtacanalicular tissue out of the collector channels.

Based on the preliminary results of a 228-eye case series by Mark J. Gallardo, MD (El Paso Eye Surgeons, PA) and Mahmoud A. Khaimi, MD (Dean McGee Eye Institute, OK), ABiC offers a highly effective addition to the MIGS treatment armamentarium. Specifically, ABiC achieved a 28% reduction in mean IOP from  $19.0 \pm 6.5$  mm Hg to  $13.7 \pm 3.0$  mm Hg at 6 months. It also reduced the mean number of medications by 50% (Table 1).

ABiC was found to be effective as both a standalone procedure and in conjunction with cataract surgery. Of the 21 patients who underwent ABiC as a standalone procedure, mean IOP was reduced from  $22.0 \pm 7.4$  mm Hg at baseline to  $13.0 \pm 3.6$  mm Hg at 6 months. This is an important distinction of ABiC, as the majority of MIGS procedures available on the market today are indicated for use during cataract surgery only.

From a practice management standpoint, it is also worth noting that ABiC requires minimal ASC investment and has Category 1 reimbursement (CPT Code 66174 Canaloplasty w/o Stent).

### ABiC IS A COMPREHENSIVE MIGS

During the ABiC procedure, the surgeon performs goniotomy, 360° cannulation, and viscodilation of Schlemm canal with the iTrack microcatheter. He or she does not use the tensioning suture employed in traditional canaloplasty. Eschewing the tensioning suture makes ABiC quick and easy; it is routinely performed in conjunction with phacoemulsification in just 15 minutes. The ABiC aspect of the combined procedure takes between 5 to 10 minutes to perform. It is also important to note that ABiC is performed via a self-sealing, clear corneal incision—there is no need for the surgeon to ever touch the sclera.

The most defining aspect of ABiC is its comprehensive approach. To date, ABiC is the only MIGS that successfully and comprehensively addresses all aspects of potential outflow resistance. Whereas other MIGS procedures treat only one aspect of aqueous outflow, ABiC accesses, catheterizes, and viscodilates the trabecular meshwork, Schlemm canal, and importantly, the distal outflow system, beginning with the collector channels.

Another hallmark of ABiC is that it does not involve a permanent implant or stent. Not only does this ensure a more

**Of the 21 patients who underwent ABiC as a standalone procedure, mean IOP was reduced from  $22.0 \pm 7.4$  mm Hg at baseline to  $13.0 \pm 3.6$  mm Hg at 6 months. This is an important distinction of ABiC, as the majority of MIGS procedures available on the market today are indicated for use during cataract surgery only.**

simplified postoperative course, along with a reduced risk of possible complications, it is also well accepted by patients. Additionally, the fact that ABiC does not require placement of an implant or stent speaks to the truly minimally invasive nature of the procedure: rather than trying to mechanically change or bypass the pathway of aqueous outflow, ABiC, along with its predecessor canaloplasty, acts to restore the natural outflow process.

### ABiC: THE NEW MIGS ON THE BLOCK

In summary, ABiC represents a truly minimally invasive and maximally effective glaucoma surgery. Clinical evidence to date indicates that the procedure is safe and effective in mild-to-moderate POAG with similar IOP-lowering effects to tried-and-true traditional canaloplasty. Importantly, ABiC enables physicians to apply a proven technique and technology earlier in the disease process, both in conjunction with cataract surgery as well as on pseudophakic patients. Unlike other MIGS procedures, ABiC ensures that all potential “blockages” in the ocular outflow pathway are addressed, including distal structures such as the collector channels. ABiC is also fast to perform and, unlike other currently available MIGS procedures, preserves tissue and does not require the permanent placement of an implant in the eye. Put simply, ABiC is a comprehensive MIGS. ■

**TABLE 1. ABiC CASE SERIES, ALL EYES**

	n	Mean IOP (mm Hg) $\pm$ SD	Mean Medications (n) $\pm$ SD
Exam Baseline	228	$19.0 \pm 6.5$	$2.0 \pm 1.0$
1 Month	215	$15.7 \pm 5.0$	$0.3 \pm 0.7$
3 Months	123	$14.3 \pm 3.8$	$1.0 \pm 1.0$
6 Months	52	$13.7 \pm 3.0$	$1.0 \pm 1.0$

Source: Mark J. Gallardo, MD (El Paso Eye Surgeons, PA) and Mahmoud A. Khaimi (Dean McGee Eye Institute, OK)

- Okeke CO, Quigley HA, Jampel HD, et al. Adherence with topical glaucoma medication monitored electronically the Travatan Dosing Aid study. *Ophthalmology*. 2009;116(2):191-199.
- Kramer TR, Noecker RJ. Comparison of the morphologic changes after selective laser trabeculoplasty and argon laser trabeculoplasty in human eye bank eyes. *Ophthalmology*. 2001;108:773-779.
- Osborne SA, Montgomery DM, Morris D, et al. Alphagan allergy may increase the propensity for multiple eye-drop allergy. *Eye*. 2005;19:129-137.
- Nelson WL, Fraunfelder FT, Sills JM, et al. Adverse respiratory and cardiovascular events attributed to timolol ophthalmic solution, 1978-1985. *Am J Ophthalmol*. 1986;102:606-611.
- Rulli E, Biagioli E, Riva I, et al. Efficacy and safety of trabeculectomy vs nonpenetrating surgical procedures: a systematic review. *JAMA Ophthalmol*. 2013;131(12):1573-1582.
- Zahid S, Musch DC, Niziol LM, Lichter PR. Collaborative Initial Glaucoma Treatment Study Group. Risk of endophthalmitis and other long-term complications of trabeculectomy in the Collaborative Initial Glaucoma Treatment Study (CIGTS). *Am J Ophthalmol*. 2013;155(4):674-680.
- Brandao LM, Grieshaber MC. Update on minimally invasive glaucoma surgery (MIGS) and new implants. *J Ophthalmol*. 2013;705915.
- Lewis RA, von Wolff K, Tetz M, et al. Canaloplasty: three-year results of circumferential viscodilation and tensioning of Schlemm's canal using a microcatheter to treat open-angle glaucoma. *J Cataract Refract. Surg*. 2011(37):682-690.
- Klink T, Panidou E, Kanzow-Terai B, et al. Are there filtering blebs after canaloplasty? *J Glaucoma*. 2012;21(2):89-94.



# THE BENEFITS OF CANALOPLASTY

Ab interno and ab externo approaches.

BY MAHMOUD A. KHAIMI, MD



I have been a practicing glaucoma specialist for 9 years, and I was one of the first adopters of canaloplasty. I welcomed the advent of this truly minimally invasive, maximally effective procedure. My own clinical experience with canaloplasty over the past 7 years, which is corroborated by more than 60 peer-reviewed publications, has confirmed that it is as effective as trabeculectomy at lowering patients' IOP and reducing their dependence on medications, but with a much better safety profile.<sup>1-6</sup> I also like being able to offer my patients a procedure where the follow-up resembles that for cataract patients. Furthermore, with the recent advent of ABiC (Ellex), which is canaloplasty performed via an ab interno approach to Schlemm canal, the procedure can now be performed with the speed and efficiency of a MIGS device insertion.

## CANALOPLASTY

### Easy for Patients and Surgeons

Canaloplasty eliminates the challenges of a filtering bleb—that is to say, it functions long-term, but without the potential major complications of a bleb, such as: bleb dysesthesia, bleb leakage, bleb-related endophthalmitis, hypotony, choroidal effusion, and decreased vision postoperatively. Although such complications are not an everyday occurrence, they are significant enough to negatively affect both the patient and the physician. Comparatively, I find canaloplasty extremely refreshing: patients who arrive for their postoperative check-up rarely ever have complications; they are smiling, because they feel their quality of vision has improved; and they are out the door in a matter of minutes.

### How It Works

The traditional canaloplasty procedure involves isolating Schlemm canal, passing the iTrack microcatheter (Ellex) through the canal, passing a suture through the canal to apply tension, and viscodilating the canal. The procedure does not involve the creation of a bleb, nor an application of mitomycin C. It is also worth noting that canaloplasty is the only glaucoma treatment that addresses all of the outflow pathways—the trabecular meshwork, Schlemm canal, and the distal outflow system, beginning with the collector channels.

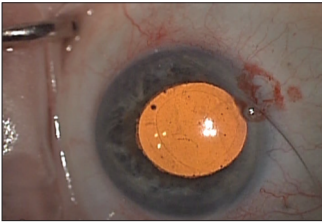
After viscodilating and placing suture tensioning into the canal, we effectively open up the intertrabecular meshwork, which allows aqueous to pass through the trabeculum. The intertrabecular route is a natural outflow system for aqueous; it is thought that the maximal resistance is at the level of the trabecular meshwork. This procedure also lifts open Schlemm canal (the aqueous passes through the trabecular meshwork and into Schlemm canal). If Schlemm canal is collapsed, obstructed, or if the trabecular meshwork is herniated into Schlemm canal due to high IOP, then we perform viscodilation followed by suture tensioning, which is similar to performing cardiac angioplasty. The blood vessels collapse or block, and they require a stent to remain open. Interestingly, the viscoelastic material that is injected into Schlemm canal not only opens up the canal itself, but it can open up the trabecular meshwork and distend the canal. It can also open up the ostia of the collector channels, which lead off Schlemm canal, thereby freeing up the passage to the venous plexus. This phenomenon is sometimes visible during surgery: when we viscodilate, it is possible to see the viscoelastic material flowing through the venous system. This is what is meant when we say that canaloplasty treats all pathways. Also, making a superficial flap and then removing the second, deeper flap to expose Schlemm canal creates a small scleral lake where fluid can gather; it also forms a window in Descemet's membrane to improve outflow from the anterior chamber.

Most of the MIGS devices that are currently FDA-approved do not address the trabecular meshwork. For example, the iStent (Glaukos Corporation) bypasses the trabecular meshwork between the aqueous and Schlemm canal. Additionally, the surgeon may or may not place it at the location of the diseased tissue—currently, there are no diagnostic devices to determine the location of obstruction for stent placement. Canaloplasty, on the other hand, addresses the entire drainage system, 360° around. There is no guessing about its placement.

Suprachoroidal and subconjunctival devices currently under FDA review, such as the CyPass (Transcend Medical) or XGel (AqueSys), bypass the eye's natural outflow system, rather than work with it. These devices mirror traditional trabeculectomy surgery in that they create an alternate pathway for fluid to escape the eye. Canaloplasty is the only technique that restores the natural outflow pathways for aqueous humor. In my mind, it should be the gold-standard procedure for controlling IOP.

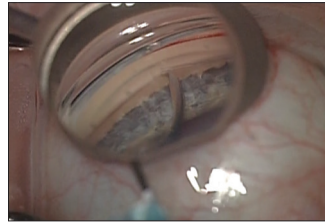


## ABiC TREATMENT PROTOCOL



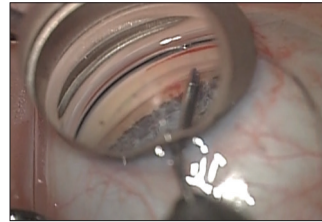
### STEP 1

After cataract surgery, I inject Miostat and a dispersive OVD into the AC. Through a sideport incision, I insert the iTrack micro-catheter approximately 1.5 clock hours away from the 3-o'clock (right eye) or 9-o'clock (left eye) position. I advance the iTrack into the AC.



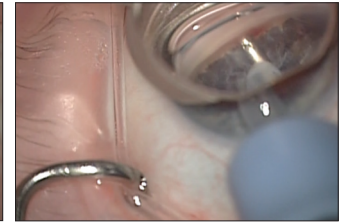### STEP 2

Entering at the temporal location, I create a small horizontal incision approximately 1-mm wide in the trabecular meshwork.



### STEP 3

Using MST retina forceps, I feed the iTrack into Schlemm canal and align it flush to the trabecular meshwork. I advance the tip of the iTrack 360° to the initial incision site and follow its progress by observing the position of the red light.



### STEP 4

I slowly withdraw the iTrack while I steadily inject viscoelastic. Once this step is complete, I remove all dispersive viscoelastic from the anterior chamber.

## THE INTRODUCTION OF ABiC

A recent study in which I participated examined two cohorts of patients who underwent canaloplasty alone and canaloplasty combined with cataract surgery; it showed good results after 2 years. (Note: my team and I are in the process of updating the poster we presented at the 2013 annual meeting of the American Academy of Ophthalmology to include the data from 2 to 3 years postoperatively.) Another cohort of patients ( $n = 30$ ) did not receive suture tensioning. Two years out, the IOP of these patients without suture was statistically significantly controlled. These results echo a review of 3-year data by Lewis et al that indicated that 360° viscodilation alone (canaloplasty without a suture) successfully lowered IOP.<sup>1</sup>

My own clinical experience with ABiC has confirmed the findings of Lewis et al in terms of the procedure's safety and efficacy. Of 106 patients treated in a recent case series (unpublished), there was a total average decrease of 27.2% in IOP and 100% in glaucoma medications at 6 months postoperatively compared to baseline. The initial baseline mean IOP for 106 patients was 19.5 mm Hg ( $\pm 6.6$  SD on two medications  $\pm 1$  SD). At 1 month, 100 patients recorded a mean IOP of 16.3 mm Hg ( $\pm 5.2$  SD on 0 medications  $\pm 0.6$  SD); at 3 months, 48 patients had a mean IOP of 15.2 mm Hg ( $\pm 4.5$  SD on zero medications  $\pm 1$  SD); whereas, at 6 months, 20 patients recorded a mean IOP of 14.2 mm Hg ( $\pm 2.7$  SD on zero medications  $\pm 1$  SD) (Table 1, pg. 6).

For those who underwent combined phacoemulsification and ABiC, the total average decrease in IOP was 27.6% at 6 months. There was also a 100% reduction in glaucoma medications, from two ( $\pm 1.0$  SD) to zero ( $\pm 0.0$  SD). For patients who were

not receiving glaucoma medication before surgery, there was a total average decrease of 28.4% in IOP after 6 months. For patients who had no previous glaucoma surgery, the total average decrease in IOP was 30.1% at 6 months and 100% in medications. The total decrease in IOP at 6 months was 25.4% for those who had undergone previous glaucoma surgery.

It is also worth noting that, although ABiC is designed as an adjunct to cataract surgery, the results of our case series review showed how well the procedure works without performing phacoemulsification—standalone ABiC, if you will. Our data showed that standalone ABiC successfully lowered IOP, without the addition of cataract surgery. Additionally, the patients in this subset represented all severities of glaucoma disease, thereby highlighting the maximum effectiveness of the ABiC procedure.

While we clearly need longer follow-up to confirm these initial results, I am confident that ABiC will build on canaloplasty's time-tested reputation as a minimally invasive and maximally effective procedure to treat mild-to-moderate POAG.

## AN AB INTERNO APPROACH TO CANALOPLASTY

ABiC offers a subtle but significant refinement of traditional ab externo canaloplasty. The primary advantage of ABiC is that we avoid manipulating the conjunctiva (*see ABiC Treatment Protocol*). We enter the eye through a small, temporal, clear corneal incision; there is no scleral flap. We access Schlemm canal via an ab interno approach. The probe has an illuminated tip, which is absolutely essential for following its progress within the canal. With it, we can see if we are inside the eye's drainage system, or if the probe's tip is veering off

into a collector channel or into the suprachoroidal space. The illuminated tip removes the guesswork from the procedure.

Once we have advanced the illuminated probe 360° around the eye, we pull it back out slowly, and simultaneously viscodilate the drainage system to balloon it open. Unlike with traditional canaloplasty, we do not place a suture in Schlemm canal during viscodilation. That is one of the key differences between ab interno and traditional canaloplasty. If we compare this procedure to cardiac angioplasty, it would be like ballooning open the clogged blood vessel without the placement of a stent.

IOP control does not get less invasive than ABiC. Again, there is no manipulation of the conjunctiva—we simply perform viscodilation through a small, 1.8-mm temporal clear corneal incision (there is no new technique to learn for angle based surgeons). The procedure is efficient and effective, as the data show.

PATIENT SELECTION FOR CANALOPLASTY

Canaloplasty has changed my treatment paradigm for glaucoma drastically; now, I evaluate each patient for this procedure. For recalcitrant cases, I consider adding trabeculectomy and/or a glaucoma drainage tube. Having canaloplasty, I have pushed the more aggressive, riskier procedures farther down my decision tree. With ABiC, I can now offer canaloplasty earlier in the treatment paradigm. Because ab interno and traditional canaloplasty do not involve a filtering bleb, they require a minimal follow-up protocol.

Contraindications for canaloplasty include: neovascular glaucoma, chronic angle-closure glaucoma, and any previous procedure that prevents the probe from advancing around the eye 360°.

There is a level-one FDA approved code for traditional canaloplasty (ie, canaloplasty with suture tensioning) and ABiC (canaloplasty without suture tensioning). So, not only are the procedures FDA approved, but both are already covered by insurance. Most notably, we can perform ab interno canaloplasty without having to combine it with cataract surgery. There is no other minimally invasive glaucoma surgery right now that has both FDA approval and independent labeling. Thus, I perform ABiC on many patients, either to lower their IOP without having to extract a cataract, or in those who are already pseudophakic.

TABLE 1. ABiC, ALL EYES			
	n	Mean IOP (mm Hg) ±SD	Mean Medications (n) ±SD
Exam Baseline	106	19.5 ±6.6	2.0 ±1.0
1 Month	100	16.3 ±5.2	0.2 ±0.6
3 Months	48	15.2 ±4.5	0.0 ±1.0
6 Months	20	14.2 ±2.7	0.0 ±1.0

OTOMY CREATION

By Mahmoud Khaimi, MD

To create the otomy, I use a 27-gauge needle on a 3-mL syringe. I start high in the anterior of the trabecular meshwork (TM) and pull down to approximately the middle of the TM, inserting the tip of the needle in the TM with the bevel facing toward the ceiling. When creating the otomy, heme reflux can occur, and it may be necessary to refill the anterior chamber with OVD for better visualization. A whitish scleral color should help to identify Schlemm canal.

It is important that the otomy be situated central to the anterior of the TM. If the otomoy is too posterior, it will be impossible to stent because of the close proximity to the sclera.

POSTOPERATIVE REGIMEN

The postoperative regimen for both traditional canaloplasty and ABiC is very similar to that for cataract surgery. I prescribe topical antibiotics and a low-dose topical steroid for 3 to 4 weeks and instruct patients not to engage in extreme lifting or bending—that is it. With trabeculectomy and glaucoma drainage implants, patients are usually prescribed drops for at least 2 months, and no physical exertion for up to 8 weeks. From a quality-of-life perspective, those are big differences.

CONCLUSIONS

In my opinion, ABiC is an innovative way of using a proven technique earlier in the disease process, and it can be performed during cataract surgery as well as on pseudophakic patients. I have performed thousands of traditional canaloplasty and ABiC procedures without a single case of endophthalmitis or prolonged hypotony. To me, any IOP-lowering procedure that addresses the entire drainage system as opposed to just part of it, in a minimally invasive approach, is definitely a procedure I want to offer my patients. ■

1. Lewis RA, von Wolff K, Tetz M, et al. Canaloplasty: three-year results of circumferential viscodilation and tensioning of Schlemm's canal using a microcatheter to treat open-angle glaucoma. *J Cataract Refract Surg.* 2011;37:682-690.

2. Bull H, von Wolff K, Korger N, Tetz M. Three-year canaloplasty outcomes for the treatment of open-angle glaucoma: European study results. *Graefes Arch Clin Exp Ophthalmol.* 2011;249:1537-1545.

3. Grieshaber MC, Fraenkl S, Schoetzau, et al. Circumferential viscocanalostomy and suture canal distension (canaloplasty) for whites with open-angle glaucoma. *J Glaucoma.* 2011;20:298-302.

4. Peckar CO, Körber N. Canaloplasty for open angle glaucoma: a three years critical evaluation and comparison with viscocanalostomy. *Spektrum der Augenheilkunde.* 2008;22(4):240-246.

5. Brüggemann A, Despouy JT, Wegent A, Müller M. Intraindividual comparison of Canaloplasty versus trabeculectomy with mitomycin C in a single-surgeon series. *J Glaucoma.* 2013;22(7):577-583.

6. Klink T, Sauer J, Körber NJ, et al. Quality of life following glaucoma surgery: canaloplasty versus trabeculectomy. *Clin Ophthalmol.* 2014;8:7-16.

**Mahmoud Khaimi, MD**  
■ clinical associate professor at the Dean McGee Eye Institute, University of Oklahoma, Oklahoma City  
■ paid consultant for Ellex and a clinical investigator for the ABiC procedure  
■ Mahmoud-Khaimi@dmei.org

# A COMPREHENSIVE APPROACH TO MIGS

Data from the ABiC Case Series.

BY MARK J. GALLARDO, MD



Canaloplasty has been clinically available to treat open-angle glaucoma for approximately 8 years. It has been an effective option for lowering IOP without the creation of a filtering bleb. Instead, it involves passing the iTrack microcatheter (Ellex) through Schlemm canal and applying viscodilation to reestablish outflow through the eye's natural drainage channels, from the trabecular meshwork, through the canal, and out via the collector channels to the venous plexus. Traditional (ab externo) canaloplasty additionally includes placing a 9–0 or 10–0 Prolene tensioning suture within Schlemm canal.

It was previously thought that placement of a tension suture was required for the dilation of Schlemm canal and IOP reduction in the long term. However, in some patients, complete catheterization of the iTrack is precluded by the presence of adhesions or structures within the canal. Without complete 360° catheterization, the placement of a tension suture is omitted in these cases, and the surgery is limited to partial or complete viscodilation of Schlemm canal.

In a 2012 multicenter trial by Lewis et al<sup>1</sup> that Dr. Khaimi details on page 4, the investigators encountered eyes with obstructive canal adhesions, which prohibited 360° catheterization. Yet, when they retrospectively reviewed the study's 3-year data, they found that these patients had the same drop in IOP as those who had received a tension suture. Additionally, a comparison mapping of viscodilation to suture tensioning revealed that viscodilation was more important in the control of IOP than the tightness of the tensioning suture.<sup>2</sup>

Based on these data, personal experience, as well as some prior clinical experience of Dr. Khaimi, combined with discussions with key individuals at Ellex, we decided to convert the procedure to an ab interno approach (dubbed ABiC) and evaluate it further.

## 6-MONTH CASE SERIES REVIEW

The subjects in the original canaloplasty multicenter trial who did not receive a suture demonstrated stable IOPs at 36 months postoperatively. Additionally, last year, I conducted a case series review of 122 eyes with primary open-angle glaucoma that underwent the ABiC procedure in conjunction with phacoemulsification or as a standalone procedure (unpublished).

In this series, the mean preoperative IOP was 18.6  $\pm$  6.4 mm Hg, and the mean number of medications was 2.0  $\pm$  1.0. At 6 months postoperatively ( $n = 32$ ), the mean IOP was reduced by 28.49% to 13.3  $\pm$  3.2 mm Hg, and the mean number of medications was reduced by 50% to 1.0  $\pm$  1.0. Of the 32 patients who reached 6 months, 17 had a mean IOP of 12.1  $\pm$  2.1 mm Hg and did not need medications. To summarize, more than half of the patients who reached 6 months achieved a reduction of IOP of 5.9 mm Hg (a 32.77% reduction) and were able to eliminate their glaucoma medication.

We also evaluated the efficacy of ABiC as a standalone procedure, and as a combined procedure performed in conjunction with cataract surgery (Figure 1). Of the 59 patients undergoing ABiC in combination with phacoemulsification, the mean preoperative IOP was 15.7  $\pm$  3.4 mm Hg, and the mean number of medications was 2.0  $\pm$  1.0. At 6 months ( $n=21$ ), the mean IOP reduced to 13.0  $\pm$  3.2 mm Hg. The mean number of medications also reduced to 1.0  $\pm$  1.0.

Importantly, our results showed that ABiC is highly effective outside of cataract surgery. Of the 15 phakic patients who underwent ABiC as a standalone procedure, the mean preoperative IOP was 21.1  $\pm$  7.1 mm Hg. The mean number of medications was 2.0  $\pm$  1.0. At 6 months ( $n=3$ ), the mean IOP reduced by 38.38% to reach 13.0  $\pm$  3.6 mm Hg. The mean number of medications was also reduced at 1.0  $\pm$  1.0. While the follow-up is short and more patient numbers are needed, these results are exciting; in ABiC, we have a minimally invasive procedure that has been shown to be highly effective without the need to be performed concurrently with cataract surgery.

A subgroup analysis of patients who were not on any glaucoma medications due to intolerance prior to receiving ABiC ( $n=78$ ) revealed that these individuals also experienced a reduction in mean IOP, from 18.0  $\pm$  6.8 mm Hg pre-treatment to 12.1  $\pm$  2.1 mm Hg at 6 months post-treatment.

## CLINICAL EXPERIENCE WITH ABIC

In the past 9 months, my team and I have treated approximately 200 patients with ABiC using the iTrack microcatheter, with great results. It has worked so effectively that I have since substituted ABiC for traditional canaloplasty. Our patients' IOP has remained stable, and they have not needed additional glaucoma medication.



Although the technique is indicated for mild-to-moderate glaucoma, my staff and I also use ABiC to treat patients with severe glaucoma to reduce their medication burden, and/or to avoid the need for filtration surgery. ABiC can also be used in patients who have undergone laser trabeculoplasty and even prior filtration surgery. We also used it as a primary treatment option in patients exhibiting either noncompliance with or intolerance to medications. Treatment with ABiC was not limited to primary open-angle glaucoma, but also included pseudoexfoliative glaucoma and pigmentary glaucoma. It can also be considered in patients who have experienced failed filtration procedures in the other eye. As the procedure relies on the restoration of the natural aqueous drainage plexus, ABiC is contraindicated in patients with forms of angle closure, including neovascular glaucoma and chronic angle closure.

In the rare eye that does not respond to ABiC, I typically follow with a filtration procedure. However, the nice thing about ABiC is that, because it spares the conjunctiva, it does not preclude a future procedure if one becomes necessary. In fact, a surgeon can still perform any type of angle or filtration surgery after ABiC, because it does not remove or permanently destroy any tissue. It simply involves catheterizing and viscodilating a canal that is already present in the eye.

### HOW ABiC COMPARES TO OTHER MIGS

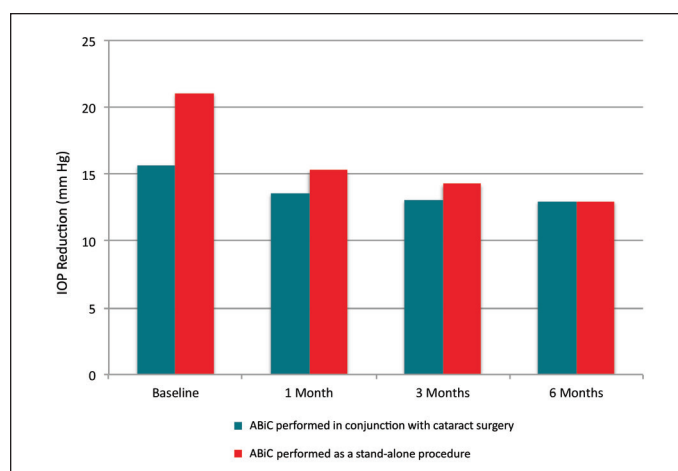
In comparing the preliminary data for ABiC against the published data for the various MIGS devices, ABiC appears to be comparable, if not more effective, than other MIGS procedures. The reason is that ABiC is the only MIGS procedure that addresses all aspects of the eye's outflow system, rather than just some aspects.

ABiC is a true microinvasive, blebless procedure that eliminates the implantation of a suture stent. It does not violate the conjunctiva; it is performed through a sideport incision made in the cornea (Figures 2 and 3). Because it removes the steps of creating (and closing) the surgical flaps and of suturing Schlemm canal, which are typically associated with traditional canaloplasty, ABiC considerably cuts down on the operative time. On average, the procedure can be performed within 5 minutes and is very well tolerated by patients.

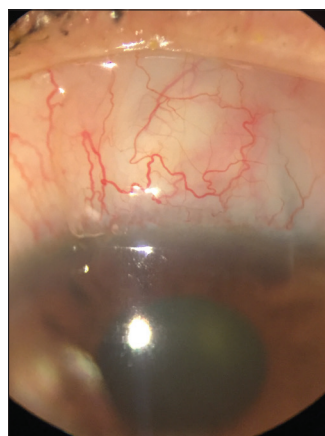
Postoperatively, patients present much in the same way as they do after cataract extraction. Unlike filtration procedures, ABiC patients are typically pain-free and have unhindered vision commensurate to their baseline disease. Some patients may present with a microhyphema, but these typically resolve within a week and do not obscure vision. Because of its microinvasive nature, recipients of ABiC have a rapid recovery.

### CONCLUSIONS

All glaucoma procedures have a rate of success and failure; the best we can do is offer a treatment that is effective and that which minimally interferes with the patient's quality of life. ABiC offers multiple advantages: being a true MIGS procedure; having an excellent safety profile; being fast and easy for surgeons to




**Figure 1.** IOP reduction, ABiC performed with and without cataract surgery.



Courtesy of Mark J. Gallardo, MD.

**Figure 2.** Incision Site: ABiC is performed via a self-sealing corneal incision.



Courtesy of Mark J. Gallardo, MD.

**Figure 3.** Gonioscopic view of nasal angle 1 month post-operatively. The drainage angle appears normal despite previous surgical manipulation.

perform; having a patient selection criteria similar to other MIGS procedures; and now, with these latest data, having proven efficacy. Additionally, ABiC (as well as traditional ab externo canaloplasty) is an on-label procedure (not an additional out-of-pocket expense for patients) and is covered by most insurance plans. Again, ABiC has worked so well to control my patients' IOP and reduce their medication load that it has become my "go-to" procedure for patients requiring surgical intervention. ■

1. Lewis RA, von Wolff K, Tetz M, et al. Canaloplasty: three-year results of circumferential viscodilation and tensioning of Schlemm's canal using a microcatheter to treat open angle glaucoma. *J Cataract Refract Surg.* 2011;(37):682-690.
2. Ellex iScience, Inc. Data on File.

#### Mark J. Gallardo, MD

- in private practice at El Paso Eye Surgeons, PA, in El Paso, Texas
- paid consultant for Ellex and a clinical investigator for the ABiC procedure
- gallardomark@hotmail.com