Supplement to

Sponsored by STAAR Surgical

Cataract & Refractive Surgery TODAY

July 2014

Addressing Regular and Irregular Astigmatism

With the STAAR Toric IOL

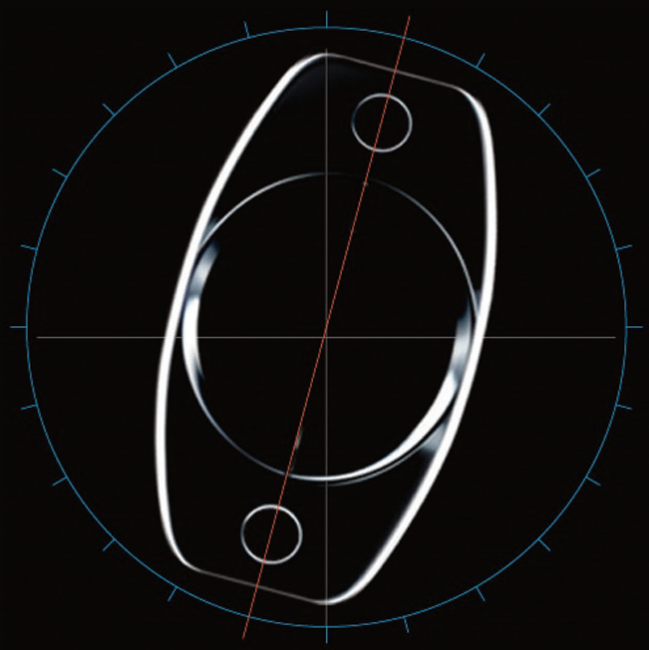

With more than a decade of successful experience and outcomes in the US market, the **STAAR Toric IOL** focuses on addressing rotational stability and predictable outcomes for a balanced astigmatic cataract solution and has an exceptional economic value.

STAAR | TORIC

Addressing Regular and Irregular Astigmatism With the STAAR Toric IOL

In April 2014, five renowned surgeons convened to discuss the STAAR Toric IOL and its many advantages. Their discussion highlights the IOL's ease of use, versatility, efficacy, and safety.

MODERATOR:

Robert Weinstock, MD, is the director of Cataract and Refractive Surgery at the Eye Institute of West Florida, in Largo, Florida. Dr. Weinstock states that he is a consultant to Alcon, Bausch + Lomb, STAAR Surgical, WaveTec Vision, and TrueVision. He may be reached at e-mail: rjweinstock@yahoo.com.

PARTICIPANTS:

Thomas Harvey, MD, is a cornea, refractive, and anterior segment surgeon in Eau Claire, Wisconsin. Dr. Harvey states that he has consulted with STAAR Surgical but has no direct financial interest in the products or companies mentioned herein. He may be reached at e-mail: tharvey@cv-eye.com.

Ahad Mahootchi, MD, is the medical director of The Eye Clinic of Florida, in Zephyrhills, Florida. Dr. Mahootchi states that he has consulted with STAAR Surgical but has no direct financial interest in the products or companies mentioned herein. He may be reached at e-mail: am@seebetterflorida.com.

Ken Maverick, MD, is the President of Focal Point Vision, in San Antonio, Texas. Dr. Maverick states that he has no financial interest in the products or companies mentioned herein. He may be reached at e-mail: maverick@focalpointvision.com.

Ehsan Sadri, MD, is the Director of Clinical Research, Atlantis Eyecare, in Newport Beach, California. Dr. Sadri is a paid consultant to STAAR Surgical. He may be reached at e-mail: esadri@icloud.com.

Robert Weinstock, MD: Refractive cataract surgery is a blossoming subspecialty that has been defined over the past couple of years. It developed out of LASIK, due to the desire to make our cataract patients see as well as possible after surgery and to reduce or eliminate their need for glasses.

One of the greatest tools we have today is the toric IOL. This is because the majority of our patients, roughly 70%, have enough astigmatism that needs to be corrected if they want to achieve spectacle independence.[1] Other strategies include manual incisions and laser correction; however, astigmatism correction can be achieved most precisely with toric IOLs.

Even though it seems like toric implants have not been around for that long, they actually have. The STAAR Toric lens (STAAR Surgical; Figure 1) is the grandfather—the original toric lens in cataract surgery—and it has been available since 1999. This IOL has a well-proven track record, and I have been using it for more than 10 years now, since I came out of training in 2001. How long has everyone else been working with the STAAR Toric lens?

Thomas Harvey, MD: I started using the STAAR Toric IOL in 2006, but I had previously used a hydrophobic acrylic toric lens before that time.

Ken Maverick, MD: I started in about 2005, right out of training. It was the first toric IOL I used, and I stuck with it.

Ehsan Sadri, MD: I have been practicing since 2004 and have used the STAAR Toric IOL from the beginning.

> "When I went back to the STAAR Toric platform, the patients' brightness right after surgery and on postoperative day 1 came back, and that was a crucial difference."
> – Ehsan Sadri, MD

Ahad Mahootchi, MD: Prior to incorporating this lens into my practice in January 1999, I worked with a regular plate-haptic lens for 6 months in order to understand my rate of surgically induced astigmatism (SIA) and hone my IOL power calculations. After I refined my outcomes with this lens, I implanted my first STAAR Toric IOL in January 1999. This patient is still alive, and, since that time, 20% of my patients receive the STAAR Toric IOL.

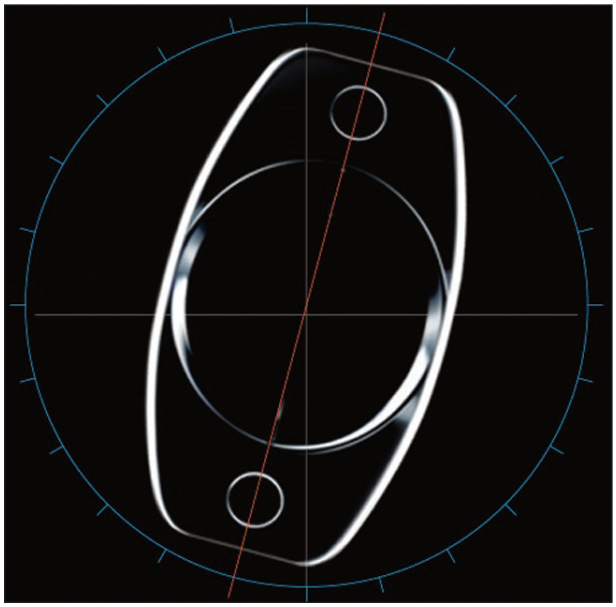

Figure 1. The STAAR Toric IOL.

Dr. Weinstock: A lot of technology has come to blossom over the past 5 or 6 years in relation to optics and lens designs, but I have stuck with the STAAR Toric IOL because, quite frankly, the clinical outcomes are so good and I have not found a good reason to change. The STAAR Toric IOL continues to provide outstanding outcomes to my patients. Additionally, it is an extremely easy lens to use and position in the eye, it provides reliable outcomes, and patients are extremely happy.

Dr. Sadri: Our collective experience shows that the STAAR Toric technology does work (Figures 2 and 3). It is consistent, and it provides the *wow* factor that patients are looking for. I briefly used the AcrySof IQ Toric IOL (Alcon), but that *wow* factor was not there. I felt it again when I went back to the STAAR Toric platform; the patients' brightness right after surgery and on postoperative day 1 came back, and that was a crucial difference.

The other thing that I really like about the STAAR Toric lens is that it has a large sweet spot, making it forgiving even during the learning curve.

Dr. Harvey: In our practice, patient acceptance of this lens is incredible; it is as high as with any other lens that I use, and I use a wide variety of lenses and materials. There may be some unrecognized benefit to the spherical optic. Patients who receive spherical IOLs, in my experience, have a good range of vision, greater depth of focus, and incredible acceptance of the lens. Additionally, astigmatic correction with the STAAR Toric IOL is easy, because the two available cylindrical powers can easily be selected, meaning that one does not have to run a calculator on every one of these patients.

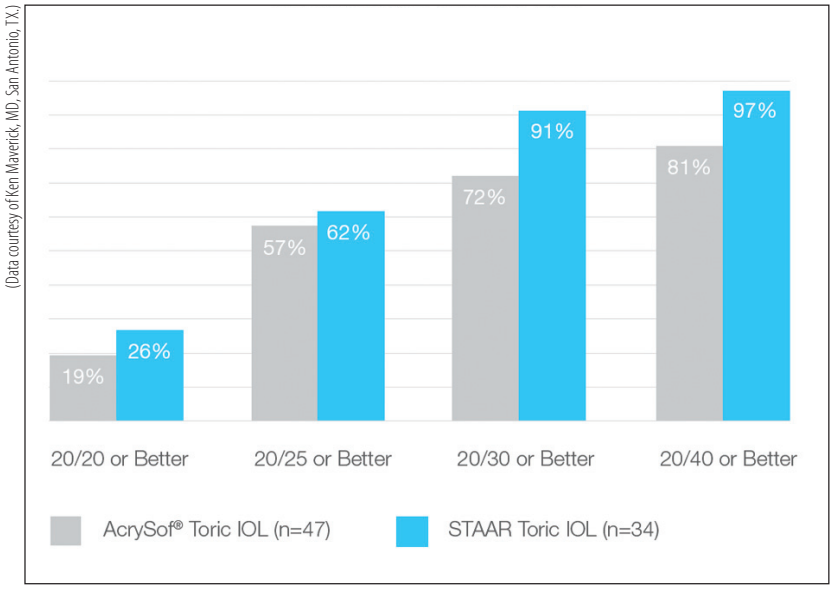

Figure 2. At 1 month postoperatively, the STAAR Toric IOL demonstrates comparable, if not greater, UCVA to other competitive toric IOLs. (UCVA is a cumulative percentage of eyes. Data on file, STAAR Surgical.[2])

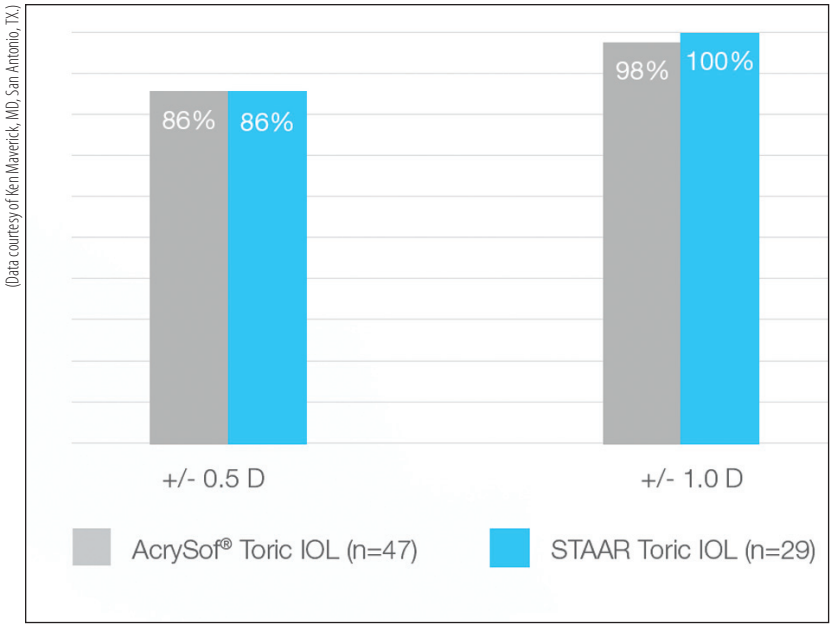

Figure 3. Like other toric IOLs, the STAAR Toric IOL has stable and predictable outcomes. This graph shows the percentage of eyes with postoperative manifest refraction cylinder within 0.50 D and 1.00 D of the intended target.[2]

For these reasons, the STAAR Toric IOL has been one of the biggest additions to my refractive cataract practice. I would put this technology up there with the introduction of multifocal and accommodating lenses.

Dr. Mahootchi: My goal as a cataract surgeon is to have as many patients as possible aspherically independent of glasses, and having a toric IOL in my armamentarium helps me to achieve this. The STAAR Toric IOL is priced so well that generally, only one person every year in my practice rejects it. I simply do not even have to sell it, other than telling the patient that he or she will spend more on glasses than on the IOL. However, it is important to tell the patient that, in the first 3 months, there will be some pseudoaccommodation.

Dr. Weinstock: In many ways, the STAAR Toric IOL is a traditional lens. First, it has a plate-haptic design and second, it uses spherical optics. I have implanted many spherical and aspheric implants—torics and monofocals—and clinically and anecdotally, I do not see any difference in the visual quality outcomes, whether patients have a spherical or an aspheric IOL.

I know you cannot judge everything in the exam room, but patients are overwhelmingly happy with this technology, and that makes me feel comfortable putting it in my patients' eyes.

Dr. Mahootchi: I challenge anybody to go to an aberrometer and change the pupil size by 0.2 mm and watch the spherical aberration go from minus to plus, or plus to minus. In the real world, people's pupils change size. You cannot take a preoperative measurement on a fixed pupil and compare it with your best pupil size afterward.

You have to trust your gut and listen to the patient, who is telling you that he or she is happy. You do not want to pay $1.00 more for something that does not make it $1.00 better, and the STAAR Toric IOL is a good way to improve patients' vision for the rest of their lives with accurate outcomes for the long term.

Dr. Harvey: Another element to that is corneal shape. We know that many corneas have natural asphericity that is greater than the norm. With a shape factor (ie, Q value) of -0.5 or above on corneal topography, there is virtually no pupil size that will give the patient excessive positive spherical aberration. In these situations, an aspheric IOL or a toric aspheric IOL is not doing the patient's visual systems any service, and it is better to implant a spherical optic to get the best

(Courtesy of Thomas Harvey, MD)

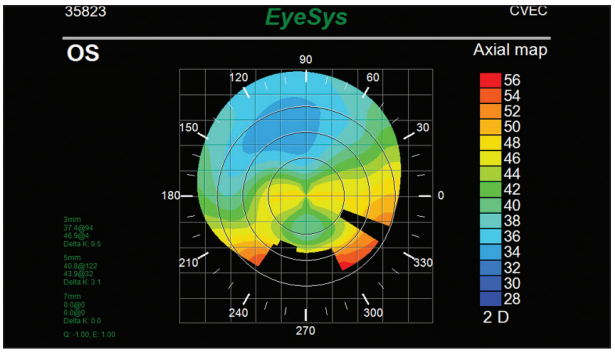

Figure 4. Asphericity concern: Post-LASIK ectasia.

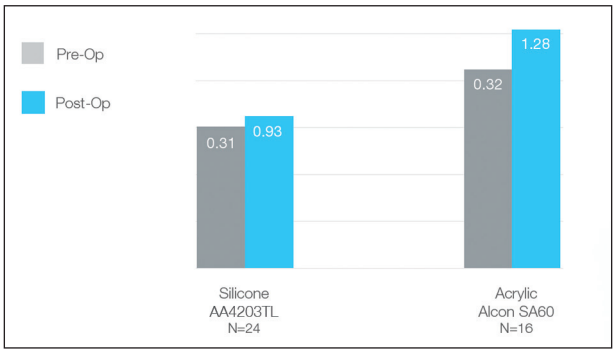

(Data courtesy of STAAR Surgical, Monrovia, CA.)

Figure 5. One study found that the silicone lens technology of the STAAR Toric IOL has a lower refractive index and produces fewer optical aberrations than an acrylic model.[4]



(Data courtesy of STAAR Surgical, Monrovia, CA.)

Figure 6. The low refractive index of the STAAR Toric IOL helps to minimize the incidence of halos, glare, and ghosting of images.[2]

functional vision under such challenging conditions (Figure 4).[3]

Dr. Sadri: The lower refractive index also helps in decreasing higher-order aberrations[4] (Figures 5 and 6).

Dr. Maverick: The bottom line is that we want patients to be 20/happy, and we can achieve this with the STAAR Toric IOL and a basic set of corneal measurements. Also, the ease of insertion is consistent, and, at the end of the day, we do not have to spend healthcare dollars or time re-rotating the lens.

My partner trained in Dallas, and he uses a different lens. Every year, we do an internal audit of outcomes and cost measures, and even though our rates of rotation are exactly the same, the healthcare dollars spent on the STAAR Toric lens are consistently less.

Dr. Weinstock: Many practitioners have concerns about rotational stability and being able to place a toric lens in the right axis. Personally, once I have calculated the astigmatism and picked the lens and power, I ask the patient to sit up, just before taking him or her back to the operating room, and look at a distance fixation target.

Using an axis marker with a pendulum on it to determine where the true vertical and horizontal meridians are located, the primary horizontal meridians are marked. In the OR, the laser is lined up with those marks, LRIs are performed, and the toric IOL is implanted. The marks are usually still visible; however, my staff and I do use interoperative aberrometry to refine the final position of the lens.

This lens is simple to manipulate. It can rotate in either direction, and the silicone material makes it easy to position on the final axis. Only small movements of the lens position (1º to 4º) are required to get it into the final position. Some other platforms, those with sticky materials, are harder to manipulate, and it is therefore easy to overshoot the final position.

MARKING THE EYE

Dr. Weinstock: Let's all share how we mark the eye for implantation.

Dr. Harvey: Marking is an important step in toric IOL implantation, and it is certainly one of the main things that can go wrong with surgery. In most cases of postoperative malpositioning, it was not the IOL that rotated, but rather, it was left in the wrong axis—it was marked inappropriately.

I try to mimic the office setting in my surgery center, so that patients have the exact steep axis as they did during the preoperative measurements. I look at the steep axis on the IOLMaster 500 (Carl Zeiss Meditec), automated keratometry, and topography. When these measurements match within a few degrees and have corresponding glasses cylinder in the same axis, this should be a slam-dunk situation. In the surgery center, the patient sits with his or her chin on the chin rest, both feet flat on the floor, and both hands on the side of the table so he or she is squared up, just like my technician did in the office for preoperative measurements. Then, with an undilated pupil, I have the patient fixate on the aiming beam and orient my slit-lamp beam on the Nd:YAG laser to the steep axis. With the finest gentian violet marker, I mark the steep axis on

the corresponding slit beam, and the patient is ready for surgery. There is no extra manipulation with degree markers intraoperatively, and it creates efficiency, so that my STAAR Toric IOL surgeries do not take any longer than a monofocal IOL surgery would.

Dr. Maverick: The technician must make sure that the patient's head is square to the machine during preoperative measurements and that he or she is measuring the eyes at a level position. At the surgery center, I have the patient sit up to mark the eye. I have compared a half dozen ways of marking—anything from laser markers to using a smartphone level app, to just good, old-fashioned hand-marking.

Another trick I use is to have the patient stand up and then sit down, just to make sure he or she is not slumped over, and then I use a marker to mark the horizontal meridian. I also have the patient look away and then look back in order to make sure he or she is looking square and level.

Dr. Sadri: Preoperative marking should be mandatory. Intraoperative aberrometry is a great tool to have, but the average surgeon does not have access to this technology, and it is certainly not mandatory. The STAAR Toric IOL is user-friendly, but you have to mark the eye to get precise results. For a surgeon who does not have access to intraoperative aberrometry or even a slit lamp, marking the 12- and 6-o'clock positions and making sure the patient's head is squared during marking is a good strategy. One must understand, however, that there will be cyclorotation of the eye. If the lens does rotate, one should still be able to follow those tools for the 12- and 6-o'clock positions.

Oftentimes after topical anesthetics are given, the markings fade. The simple solution is to have the patient sit up and re-mark. Finally, make sure at the end of the case that the markings line up. I actually check IOL alignment after I take the speculum out, because the anterior chamber can fluctuate with the movement, and I have seen the lens rotate right afterward. I rectify the movement by replacing the speculum and rotating the IOL back into place.

Those are my little pearls that might help the surgeon who is starting out with toric IOLs.

Dr. Maverick: I would add that, because your microscope is on high magnification to line up the lens, sometimes the patient's head can drift back and forth. Therefore, make sure that the iris plane is horizontal with the floor at the end of the case. This will avoid the chance for a parallaxes if you mark irregularly.

Dr. Mahootchi: My results are better when I mark as opposed to someone else. I use a level slit lamp on low magnification. Also, I mark in the up and down position now, because the two dots are almost always nasally displaced when I mark. Results are better when I look at that natural pupil and use two limbal marks.

> "I tell patients that [the STAAR Toric IOL] is the first adjustable lens. If they do not like the prescription, I can rotate it in the office and get it to where I want it to be. I cannot do that with competitor lenses; I have to take them back to the OR."
> – Ahad Mahootchi, MD

This toric lens works well with sophisticated technology, and it works well with almost no technology (Figure 7). I mark the cornea myself using the Dell Astigmatism Marker (Rhein Medical), and I get the IOL's alignment as close as I can in the OR. It is usually dead on. Every 1° of misalignment accrues a 3% decrease in the correction of astigmatism, but, in the real world, 3% of 1.00 D is 0.03 D. European studies show that the rotation can be off by as much as 7° without the patient noticing.

I tell patients that it is the first adjustable lens. If they do not like the prescription, I can rotate it in the office and get it to where I want it to be. I cannot do that with competitor lenses; I have to take them back to the operating room. With that said, I rarely have to rotate the STAAR Toric IOL postoperatively; my rotation rate is 1 in 17 eyes.

CYLINDER REDUCTION

Dr. Weinstock: You raise a good point about cylinder reduction. Everyone has his or her cutoff for a manual incision versus a toric IOL. At what cylinder value do you start to move from a limbal relaxing incision (LRI) to a toric IOL?

Dr. Maverick: Generally about 1.00 D. My staff and I use the LenSx Laser system (Alcon) to create LRIs for lower cylinder errors, but for anything between 1.00 and 3.00 D, depending on whether it is with-the-rule or against-the-rule astigmatism, I prefer the STAAR Toric lens platform, because it does not touch the cornea. I think a lot of surgeons would agree that a little residual refraction tends to make a happier patient, if we do have to alter the cornea.

Dr. Mahootchi: One must think in the long term. There is a natural against-the-rule drift over time, which must be incorporated into one's plans. I generally correct all against-the-rule astigmatism. For with-the-rule astigmatism, I generally try to leave the patient with 0.75 D or less. Overcorrecting these patients leads to subsequent adjustments later on.

Dr. Weinstock: What about topography and irregular astigmatism? Is there some regular threshold that anybody wants to share?

(Courtesy of Ahad Mahtoochi, MD)

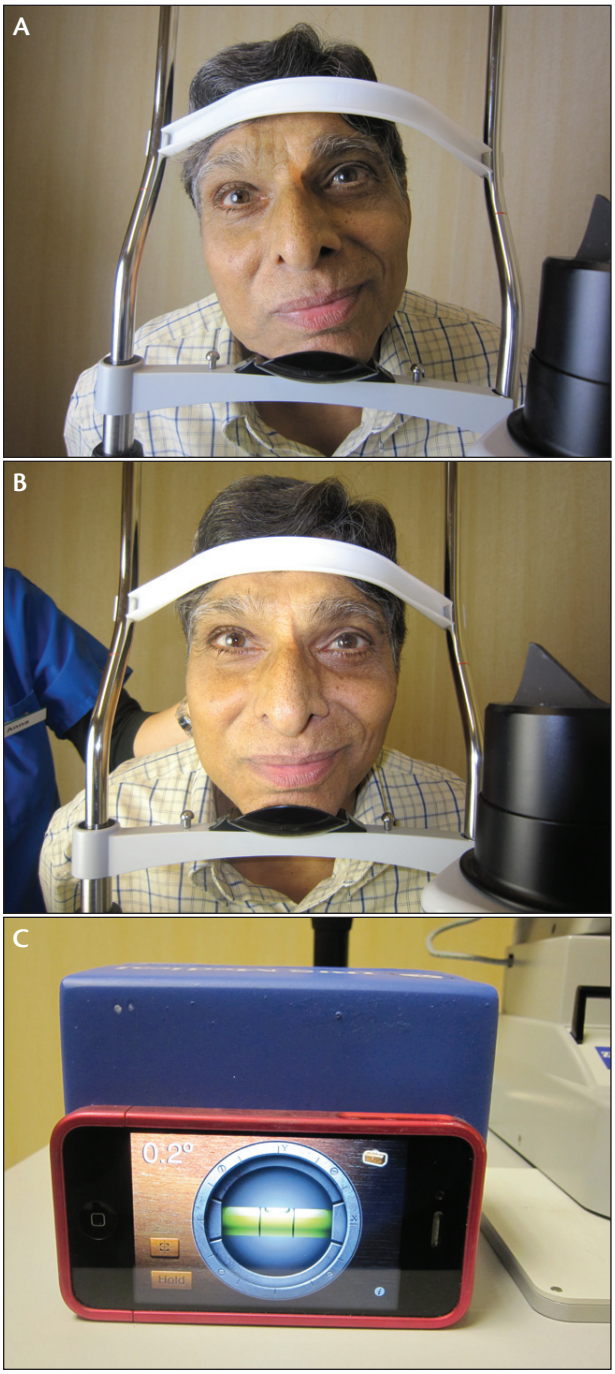

Figure 7. Example of poor (A) and proper (B) positioning of a patient at the slit lamp. A simple smartphone app can be used as a level (C).

Dr. Harvey: This lens is ideal for patients with mild keratoconus findings (stage 1 and 2 cones) and similar irregular, nonprogressive patterns. Also, patients who have previously undergone hyperopic LASIK will have irregular central steepening, and the STAAR Toric IOL is perfect for that, because you can compensate for the excessive asphericity that we were discussing earlier.

The real key in treating irregular astigmatism is that there is an element of regularity within the irregular astigmatism. If there is some type of a bow-tie pattern that can be consistently confirmed with other technologies besides the topographer or tomographer, then we know that the toric lens should work extremely well as long as the refraction matches those other devices.

The other challenge that we need to be aware of is this: Eyes that have steeper keratometry can trick our traditional biometry formulas. Having more robust formulas, like the SRK-T, are helpful. Some European studies that have used the SRK-T confirm that that is a good approach. Others have used the Holladay 2, and it also is a good approach; however, the steeper the cornea gets, the tougher it is to hit our target, regardless of the IOL (Figure 8). I think the future looks better for these patients when we have more methods to determine the true corneal power.

> "This lens is ideal for patients with mild keratoconus findings and similar irregular, nonprogressive patterns. Also, patients who have previously undergone hyperopic LASIK will have irregular central steepening, and the STAAR Toric IOL is perfect for that, because you can compensate for the excessive asphericity."
> – Thomas Harvey, MD

Dr. Mahootchi: There is no single device that you can use for reliable power and axis, and it is better to have multiple measuring devices. Most eyes are not irregular, but my advice is to pay attention specifically to the central 4 mm of corneal topography—try not to get distracted by all the pretty colors on the printout. Additionally, always measure the unapplinated cornea before applying drops.

Dr. Sadri: Something else we need to manage is dry eye. Sometimes in a busy, high-volume practice, we miss the dry eye diagnosis. However, it is important to treat ocular surface disease in conjunction with implanting any toric platform, because the topography is influenced by it. One must let the patient know that he or she has some instability and that their visual quality will rebound once it is under control. Remeasuring the cornea after initiating dry eye treatment helps the postoperative outcome.

(Courtesy of Thomas Harvey, MD)

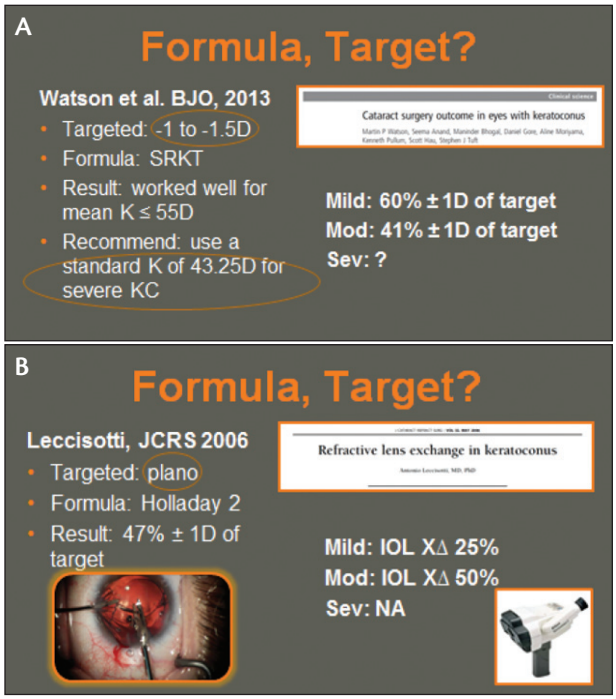

Figure 8. Surgical targets for eyes with keratoconus undergoing cataract surgery[5] (A) and refractive lens exchange[6] (B).

Dr. Weinstock: That is a good point. You do not want to jump to the conclusion that the lens was not put in at the right axis; it could be the dry eye status induced from the postoperative treatments that are being used and from healing. Also, wound-induced astigmatism plays a role. Sometimes it is better to err on the side of caution if you are close to the intended refraction by waiting and letting these patients heal and following them instead of jumping back in and rotating the lens. A lot of times, some of those initial 20/40s or 20/30s will drop down to 20/20s after a couple of weeks.

Dr. Mahootchi: For someone who is just starting with toric IOLs, it is crucial to know his or her rate of SIA. At a competitor's meeting, in a room of 300 doctors, someone asked, "How many of you track your postoperative outcomes?" Only two people, including myself, raised their hands. That is not the best way to start using toric IOLs. One of the benefits of the program was that I learned there was a threefold difference in my SIA with a 100-µm diamond blade and a 130-µm metal blade. Little things make a difference; you will not learn them all at once, but you should start the process at some point.

Dr. Weinstock: Fortunately, we have a lot of tools that take SIA into account when figuring out the optimum axis for implantation and IOL power are. Some tools are available as smartphone apps.

Dr. Maverick: Many good candidates for a toric IOL may have been in contact lenses recently, and I always like to have these patients avoid contact lens wear for 1 week prior to surgery, in order to give the cornea time to stabilize. I also like to obtain two different types of keratometry readings. If those two do not correlate, I will use a third method as a tie-breaker, usually the Pentacam (Oculus Optikgeräte), because sometimes there can be a lurking corneal pathology or more or less corneal astigmatism than one might have thought.

Dr. Weinstock: That is a good point. We use the STAAR Toric lens a lot for patients who have been wearing or have previously wore monovision contact lenses. These patients get comfortable with that lifestyle, and their refractive predictability is strong with this particular lens because it tends to sit in a nice posteriorly vaulted position.

I feel confident, especially in those monovision patients in whom I have to hit the target, that I will get one eye plano and the other eye -2.00 or -2.50 D, or whatever I am targeting. It is more than just cylinder correction—it is having confidence in the spherical outcome too, and that is a big help with the STAAR platform.

CAPSULOTOMY

Dr. Sadri: One common question with regard to toric IOLs is, "Can I perform a Nd:YAG capsulotomy if the lens is misbehaving?" My advice is to be conservative with Nd:YAG treatments. I am happy as long as the optical zone is clear.

> "It is more than just cylinder correction—it is having confidence in the spherical outcome too, and that is a big help with the STAAR platform."
> – Robert Weinstock, MD

Dr. Mahootchi: I usually wait at least 1 year before performing an Nd:YAG capsulotomy. I will also YAG the anterior capsule and the short axis first to avoid any posterior dislocation. Also, if the anterior capsule is still contracting and there is nothing in the posterior capsule, hyperopic drift can occur and affect the refractive stability of the lens. Performing an Nd:YAG capsulotomy on the anterior capsule, in tiny little cuts in a few different places, is a good strategy.

Dr. Harvey: I think that speaks to modern cataract surgery. We are doing different surgery now than we did even 5 to 10 years ago. We remove a lot more cortex, we address lens epithelial cells, and we make sure our capsulorhexis is

a predictable size. Some have argued that we must create a small capsulorhexis, but that is not the case with the STAAR Toric lens. A healthy, 5.5- to 6-mm capsulorhexis works, and it overlaps the optic, because it is a true 6-mm optic that will be predictably centered and will not lead to anterior capsular contraction or phimosis if all these steps are taken.

LENS STABILITY

We have learned a lot from other companies' lenses. Some of them misbehave greatly if pristine cataract surgery is not performed. On the other hand, I have been amazed at how stable the STAAR Toric IOL is over the years. Even those that I implanted nearly 9 years ago still continue to look great.

Dr. Mahootchi: This lens does not rotate after the first day or two, and therefore it is important to check patients the day after surgery, in order to devise a plan and not be disruptive if it needs to be rotated. There is a sweet spot to adjust this lens, and the sweet spot for me seems to be between postoperative days 6 and 10, to let the capsular bag get a little sticky. If you rotate too early, the lens may misbehave again.

I use a cycloplegic refraction, and I ask the patient to come into the clinic during the last appointment of the morning or the afternoon, so that they do not have to wait in the clinic if I think I might need to adjust the lens. I have a small microscope in the office and perform the adjustment through the paracentesis. I have never had one rotate after the first week—ever.

How thoroughly the capsule is cleaned makes a difference with some lenses, but the STAAR Toric IOL seems to behave well, even when I do not get too aggressive with removing lens epithelial cells, especially along where the plate axis is going to be. I take out the cortex and polish with a Shephard sweep, but I do not scrape. This seems to lead to a more stable lens.

Dr. Sadri: I think the average surgeon is leery of going back into the eye. Perhaps the bigger picture here is, if one is thinking of using any kind of premium IOLs, torics included, that he or she must have access to an excimer laser to perform an enhancement. Oftentimes, I think surgeons who do not have access to an excimer laser are scared. They implant a couple toric IOLs that do not work out the way they should, and they go back to monofocal IOLs. These surgeons must be reassured that there are simple ways to rotate the lens to improve postoperative outcomes.

Dr. Maverick: A misaligned STAAR Toric IOL is a rare event, but I think it is beneficial to keep in mind that sometimes the lens requires a bit of adjusting. When you inform patients of this ahead of time, there are no surprises, and they view it as more of a refinement than that the lens did not work.

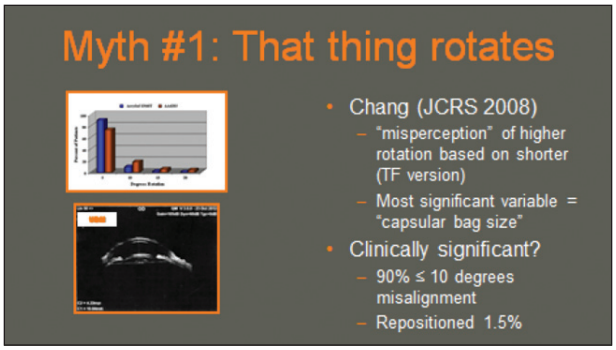

(Courtesy of Thomas Harvey, MD)

Figure 9. The incidence of clinically significant IOL rotation is low with the STAAR Toric IOL.[7] (Chart reprinted from: Chang DF. Comparative rotational stability of single-piece open-loop acrylic and plate-haptic silicone toric intraocular lenses. *J Cataract Refract Surg*. 2008;34(11):1842-1847 with permission from Elsevier. Ultrasound biomicroscopy image courtesy of Gerard Clarke, MD, Oshkosh, WI.)

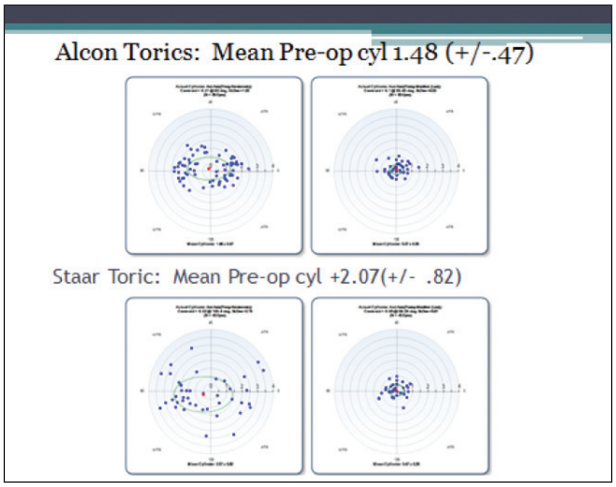

(Courtesy of William Wiley, MD, Cleveland, OH.)

Figure 10. The STAAR Toric IOL versus the AcrySof ReSTOR IOL (Alcon).

Dr. Harvey: Small rotations can happen with any toric IOL, and the most common reason is a mismatch between the size of the capsular bag and the implant. A larger bag increases the chance for rotation (Figures 9 and 10),[8,9] and fortunately, the STAAR Toric IOL has a new longer length of 11.2 mm, which reduces the chance for mismatch.

I still feel that many people have asymmetrically large capsular bags, and there may be an area in which it fits snugly and in which it is loose. A loose fit is the perfect opportunity to use an adjunct that will not only help with the effective lens position in the short term, but also in securing the lens with a capsular tension ring (CTR). I have great success with a preloaded PMMA capsular tension ring (Morcher), as it virtually eliminates any potential movement. Also, clinical experience at the Cleveland Eye Clinic show that the rotational stability of the STAAR Toric is aided by a CTR.[10] The preloaded

CTR is easier to implant than any IOL and is extremely helpful if any sector of the capsular bag is oversized.

Dr. Weinstock: In addition to CTRs, there are other tricks that can help to avoid rotation of the IOL. First, the ophthalmic viscosurgical device (OVD) must be completely removed, because it is a slippery material that can lead to IOL movement. Removing any OVD that is trapped behind the IOL can be helpful when the lens settles into its final position. Also, if the capsular bag is large and the eye is hyperinflated, it can blow the capsule wide open, creating a lot of space for movement and tilting. Sometimes it is good to not overinflate the eye at the end of a case if the lens is snug in the capsule, as it can prevent any movement postoperatively.

Dr. Maverick: The other thing I would emphasize is, in the rare case the IOL does rotate, to ask the patient if he or she has done something that is not allowed in the immediate postoperative period—whether it is kickboxing or running marathons. Only very low-impact exercise, like the elliptical machine, are okay in the first week while the lens settles into its final position.

Dr. Weinstock: One must check the axis, even if it is just to reference the intended placement. I always ask what my final axis is in the OR, and that goes into the medical records. The day after surgery, we pull those records up and match it to where I positioned the IOL in the OR to see if I am close. The 1- or 2-week visit is a great time to see the patient back. I would not recommend IOL repositioning under the slit lamp for surgeons just starting with toric IOLs, but there is no question that, in skilled hands, it is feasible.

We have spent a lot of time talking about rotation, but I cannot remember the last time I had to rotate a STAAR Toric lens. It is a fear that we naturally have, but in reality it is an extremely rare event.

Dr. Harvey: In Chang's study,[8] the repositioning rate with the STAAR Toric was only a 1.5%, so that is extremely predictable.

CENTRATION

Dr. Weinstock: Let's touch on the issue of centration. One thing that I am comforted by with the optic design and the optics of the STAAR Toric lens is that the lens is always stable in the eye, even if someone is prone to contraction. This is because the spherical optic is forgiving of slight decentration (0.5 to 1 mm). You cannot say the same for all other platforms. For example, one can run into real issues in an eye with an aspheric lens and induced spherical aberration, especially on the minus side.

Dr. Harvey: The concern I had heard about decentration has gone down significantly since I started implanting the STAAR Toric lens. I have always prided myself on trying to ensure that I had the cleanest possible capsular bag because, as we know from other platforms, peripheral fibrosis can cause significant change, not only in the effective lens position of the plate-haptic IOL, but enough bowing at a hinge to create an unpleasant and visually disabling situation. The STAAR Toric IOL does not have a hinge and will not buckle forward, even if there is excessive healing. The point is that this is premium care and far from a compromise for our astigmatic patients.

Dr. Mahootchi: Once implanted, the STAAR Toric IOL looks beautiful at day 1, week 1, year 1, year 5, year 10, and year 15. It is a beautiful lens that works for the rest of the patient's life.

Dr. Weinstock: Does one need to purchase a femtosecond laser to use this technology effectively?

Dr. Harvey: Two questions come to mind: What is the best means of astigmatism correction that we can offer patients and guarantee they are not overpaying? How can the facility benefit financially from this service? The sweet spot of this lens is in the range of low to moderate astigmatism (less than 2.50 D), and many surgeons think that they need to go out and purchase a femtosecond laser to compensate for the astigmatism issues that their patients have in that range. However, if the numbers are truly run and are looked at objectively, there is no way that a femtosecond laser can compare to the results obtained from astigmatism correction with a toric IOL. This is true clinically, because it is so predictable at correcting the cylinder, and also financially, because the IOL is so reasonably priced and it does not require a monthly service contract, a patient interface that costs several hundreds of dollars, or a good lender to purchase the device. Even though I believe the femtosecond laser continues to be the king of the cornea, it is not a necessary purchase to correct astigmatism in that range.

Dr. Weinstock: In today's economy, patients are looking for value. Luckily, we can offer patients multiple options or recommendations for them to achieve some spectacle independence at the time of cataract surgery. If we can find a way to make vision correction cost-effective for both the patient and ourselves, and we can consistently deliver a good outcome, that is the perfect balance. Perhaps patients will not achieve complete spectacle independence like they might with multifocal or accommodating lenses, but that does not always have to be the goal. A tremendous number of patients are satisfied with having great distance UCVA, and the STAAR Toric lens is an affordable option for patients who can live with the possibility of needing reading glasses in occasional situations.

> "More often than not, the simplest solution is the best one, and this technology is proof of that."
> – Ken Maverick, MD

If I were to perform a laser enhancement after multifocal IOL implantation, I would have to pass that cost to the patient. However, you do not always need a lot of fancy toys to deliver a great refractive outcome. A toric IOL implantation technique that uses basic biometry and marking of the cornea is cost-effective, and it provides good outcomes.

Dr. Mahootchi: The science behind IOLs confirms that lens-based surgery is a better way to correct astigmatism than the cornea, period, and the STAAR Toric is the most cost-effective option. In my hands, using no fancy equipment, 85% of patients achieve within ±0.50 D of plano.

This lens is priced so that almost 100% of people who qualify for it will convert to it and, when it is selected, everyone wins. The patient wins, and he or she will be raving for a long time about how good the result is; you win, because you delivered a great outcome and did so cost-effectively; and your office wins, because workflow will dramatically improve. There is no need for autorefraction on these patients. At $6 or $7 a minute that it costs to run the office, that adds up. You quickly find yourself not arguing about refraction fees, and you do not waste time with refraction, so everyone wins with this lens.

Dr. Maverick: More often than not, the simplest solution is the best one, and this technology is proof of that. The STAAR Toric IOL has been around for a while, and even today with all the lens options and machines that measure astigmatism, this lens is still the biggest bang for the patient's buck, as far as vision correction is concerned.

INDEX OF REFRACTION

Dr. Weinstock: What about dysphotopsias and index of refraction with this lens? I have seen no complaints of a positive or negative dysphotopsia in vision on day 1 or over the long-term. The same cannot be said for some of newer lenses, ones with big, square edges and different indexes of refractions and materials.

Dr. Sadri: We Southern Californians love to drive our cars, and many of my patients drive early in the morning and at dusk. When it comes to mesopic driving conditions, we have a good track record with the STAAR Toric platform. I do not remember one patient complaint about problematic driving or dysphotopsias. The reason is because this IOL is well designed.

Dr. Weinstock: What about the issue with the index of refraction? From a cosmetic standpoint, in a certain lighting condition with certain toric or monofocal lenses there is kind of extra sparkle in the implanted eyes. Have your patients noticed that with the STAAR Toric?

Dr. Harvey: No. It is a bonus that I do not have to council the patient about any dramatic Purkinje reflex. The external appearance of the implanted STAAR Toric IOL is so good that it is as if the patient never went under the knife.

The IOL is delivered through a small (2.75-mm) incision, it is stable, and it provides what I consider to be perfect vision that does not degrade over time. The material of a competitor's IOL has been shown to change over time and provide diminished optical performance.[11]

Interestingly, some surgeons continue to avoid using the STAAR Toric IOL because of its design, but there are now six plate-haptic toric IOLs on the market, so this is not voodoo. In fact, I prefer a plate-like design because it most closely matches our natural lens' coverage. The crystalline lens is not a round circle with arms hanging out; it has a more elongated, round appearance, and the plate-haptic design is as close as we can get to that at this time. The Europeans have known for quite some time that plate-haptic lenses correct astigmatism extremely well, and now the plate-haptic platform is being utilized in bifocal IOL designs because of its superior stability compared with the C-loop design.

Dr. Weinstock: The majority of lenses I use are not one- or three-piece C-loop traditional haptic lenses. My monofocal IOL of choice has a plate-style haptic, my toric IOL of choice is the STAAR plate-haptic lens, and my premium IOL of choice is an accommodating plate-haptic lens. If you look at the lenses that I am using, you are absolutely right, I am following the European trend of getting away from these older-style C-loop design lenses.

Thank you all for sharing your thoughts and wisdom on the STAAR Toric IOL. It is clear that we are collectively having great results with this implant, and it plays a vital role in our practice. It is nice to know that we have such a well-proven platform to count on for our patients who need astigmatism correction at the time of cataract surgery. ■

1. Hill W. Expected effects of surgically induced astigmatism on AcrySof toric intraocular lens results. *J Cataract Refract Surg*. 2008;34:364-367.
2. Toric IOL Physician Product Guide 2013. STAAR Surgical; Monrovia, CA.
3. Calossi A. Corneal asphericity and spherical aberration. *J Refract Surg*. 2007;23(5):505-514.
4. Martin RG, Sanders DR. A comparison of higher order aberrations following implantation of four foldable intraocular lensdesigns. *J Refract Surg*. 2005;21:716-721.
5. Watson MP, Anand S, Bhogal M, et al. Cataract surgery outcome in eyes with keratoconus. *Br J Ophthalmol*. 2014;98(3):361-364.
6. Leccisotti A. Refractive lens exchange in keratoconus. *J Cataract Refract Surg*. 2006;32(5):742-746.
7. Chang DF. Comparative rotational stability of single-piece open-loop acrylic and plate-haptic silicone toric intraocular lenses. *J Cataract Refract Surg*. 2008;34(11):1842-1847.
8. Chang DF. Early rotational stability of the longer STAAR Toric intraocular lens: Fifty consecutive cases. *J Cataract Refract Surg*. 2003;29:935-939.
9. Chang D. Comparing the STAAR and AcrySof Toric IOLs. *Cataract & Refractive Surgery Today*. May 2007.
10. Wiley WF. Combining a CTR with a plate-haptic toric IOL. *Cataract & Refractive Surgery Today*. May 2012.
11. Beiko GH. Effect of IOL selection on driving habits. Paper presented at the American Society of Cataract and Refractive Surgery; April 25-29, 2014; Boston.