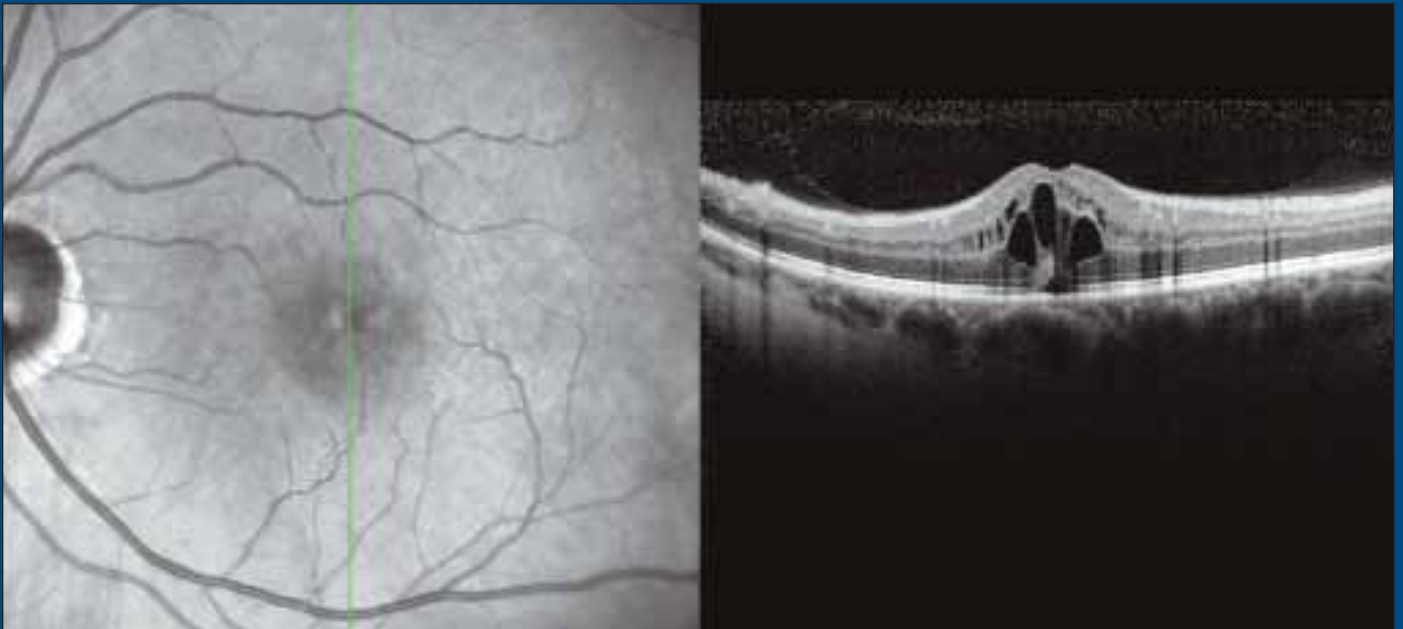


Cataract & Refractive Surgery TODAY

June 2008

A Multi-Disciplinary Approach to the Management of **Cystoid Macular Edema**



FEATURING:

Jeffrey S. Heier, MD • Eric D. Donnenfeld, MD • Allen C. Ho, MD
Michael B. Raizman, MD • Richard F. Spaide, MD • R. Bruce Wallace III, MD

A MULTI-DISCIPLINARY APPROACH TO THE MANAGEMENT OF CYSTOID MACULAR EDEMA

Jointly sponsored by The Dulaney Foundation and *Cataract & Refractive Surgery Today*.

Release date: June 2008. Expiration date: June 2009.

This continuing medical education activity is supported by an unrestricted educational grant from Allergan, Inc.

STATEMENT OF NEED

Cystoid macular edema (CME) is a condition characterized by swelling of the retina due to leakage from the small blood vessels within the fovea, the central part of the retina responsible for your detailed vision. It is a general condition caused by a very wide range of retinal diseases which may include:

- diabetic retinopathy
- wet age-related macular degeneration or other causes of bleeding under the retina
- retinal vein occlusions
- epiretinal membranes (or macular pucker)
- uveitis
- other causes of inflammation within the eye such as recent eye surgery (such as cataract surgery)

Because many factors can lead to CME, effective treatment will vary. Retinal inflammation is usually treated with anti-inflammatory medications. These are usually given as eye drops, though occasionally they must be administered as an injection or by mouth. Topical NSAIDs have been shown to be effective in reducing postoperative cells and flares in many cataract patients. A small but significant portion of patients, however, will not have complete control of postoperative inflammation with a topical nonsteroidal alone. Therefore, using a combination of topical corticosteroids and topical NSAIDs is often most effective in enduring excellent control of inflammatory responses.

Many studies have suggested that topical NSAIDs are effective at preventing CME. In some studies, topical NSAIDs appear to be more efficacious than corticosteroids at preventing macular edema. In light of increasing evidence for adequate, and sometimes improved, efficacy of NSAID monotherapy compared with corticosteroids, a postoperative regimen consisting solely of an NSAID may replace combination therapy as the primary regimen for CME prophylaxis.

1. Irvine SR. A newly defined vitreous syndrome following cataract surgery. *Am J Ophthalmol*. 1953;36(5):599-619.
2. Gass JDM, Norton, EWD. Follow-up study of cystoid macular edema following cataract extraction. *Trans Am Acad Ophthalmol Otolaryngol*. 1969;73:665.
3. Spaide RF, Yannuzzi LA, Sisco LJ. Chronic cystoid macular edema and predictors of visual acuity. *Ophthalmic Surg*. 1993;24:4:262-267.
4. McColgin AZ, Raizman MB. Efficacy of topical diclofenac in reducing the incidence of postoperative cystoid macular edema. *Invest Ophthalmol Vis Sci*. 1999;40:289.
5. Henderson BA, Kim JY, Ament CS, Ferrufino-Ponce ZK, Grabowska A, Cremers SL. Clinical pseudophakic cystoid macular edema. Risk factors for development and duration after treatment. *J Cataract Refract Surg*. 2007;33:9:1550-1558.

6. Donnenfeld ED, Perry HD, Wittpenn JR, Solomon R, Nattis A, Chou T. Preoperative ketorolac tromethamine 0.4% in phacoemulsification outcomes: pharmacokinetic-response curve. *J Cataract Refract Surg*. 2006;32:9:1474-1482.

7. Wittpenn J, Silverstein SM, Hunkeler JD, Kenyon K; ACME Study Group. Subclinical cystoid macular edema reduces contrast sensitivity and final visual acuity in low-risk cataract patients. Presented at: the Association for Research in Vision and Ophthalmology Meeting; May 10, 2007; Fort Lauderdale, FL.

8. Busbee BG, Heier JS, Waterbury D, et al. Comparison of vitreous PGE2 concentrations of ketorolac 0.4%, bromfenac 0.09%, and nepafenac 0.1% in patients undergoing vitrectomy. Poster presented at the Association for Research and Vision in Ophthalmology Annual Meeting, May 10, 2007; Fort Lauderdale, FL.

9. Picado P. COX-2 specific inhibitors in NSAID-intolerant patients. *Int J Immunopathol Pharmacol*. 2003;16:11-16.

10. Brune K. Safety of anti-inflammatory treatment—new ways of thinking. *Rheumatology (Oxford)*. 2004;43:16-20.

11. Spaide RF. Cystoid Macular Edema After Ocular Surgery. In: *Ophthalmic Surgery Complications. Prevention and Management*. Charlton J, Weinstein GW, M.D., eds. Philadelphia: J.B. Lippincott, 1995.

12. Arevalo JF, Garcia-Amaris, RA, Roca JA, et al; Pan-American Collaborative Retina Study Group. Primary intravitreal bevacizumab for the management of pseudophakic cystoid macular edema. Pilot study of the Pan-American Collaborative Retina Study Group. *J Cataract Refract Surg*. 2007;33:2098-2105.

13. Spitzer MS, Ziemssen F, Yoeruek E, Petermeier K, Aisenbrey S, Szurman P. Efficacy of intravitreal bevacizumab in treating postoperative pseudophakic cystoid macular edema. *J Cataract Refract Surg*. 2008;34:70-75.

TARGET AUDIENCE

This activity is designed for ophthalmologists who treat CME.

LEARNING OBJECTIVES

Upon successfully completing this learning program, participants should be able to:

- identify the currently available pharmaceutical agents used to treat CME
- discuss the mechanism of action of NSAIDs
- discuss the tolerability of steroids and NSAIDs

- discuss the data that support the treatment described in the cases presented.

METHOD OF INSTRUCTION

Participants should read the continuing medical education (CME) activity in its entirety. After reviewing the material, please complete the self-assessment test, which consists of a series of multiple-choice questions. To answer these questions online and receive real-time results, please visit <http://www.dulaneyfoundation.org> and click "Online Courses."

Upon completing the activity and achieving a passing score of over 70% on the self-assessment test, you may print out a CME credit letter awarding 1 *AMA PRA Category 1 Credit*.™ The estimated time to complete this activity is 1 hour.

ACCREDITATION AND DESIGNATION

This activity has been planned and implemented in accordance with the Essential Areas and policies of the Accreditation Council for Continuing Medical Education (ACCME) through the joint sponsorship of The Dulaney Foundation and Bryn Mawr Communications LLC, publisher of *Cataract & Refractive Surgery Today*. The Dulaney Foundation is accredited by the ACCME to provide continuing education for physicians. The Dulaney Foundation designates this educational activity for a maximum of 1 *AMA PRA Category 1 Credit*.™ Physicians should only claim credit commensurate with the extent of their participation in the activity.

DISCLOSURE

In accordance with the disclosure policies of The Dulaney Foundation and to conform with ACCME and FDA guidelines, anyone in a position to affect the content of a CME activity is required to disclose to the activity participants: (1) the existence of any financial interest or other relationships with the manufacturers of any commercial products/devices, or providers of commercial services; and (2) identification of a commercial product/device that is unlabeled for use or an investigational use of a product/device not yet approved.

CONTENT VALIDATION

In compliance with ACCME standards for commercial support and The Dulaney Foundation's policy and procedure for resolving conflicts of interest, this CME activity was peer reviewed for clinical content validity to ensure the activity's materials are fair, balanced and free of bias; the activity materials represent a standard of practice within the medical profession; and any studies cited in the materials upon which recommendations are based are scientifically objective and conform to research principles generally accepted by the scientific community.

FACULTY CREDENTIALS

Jeffrey S. Heier, MD, is a Clinical Ophthalmologist specializing in diseases of the retina and vitreous at Ophthalmic Consultants of Boston and a member of the *Retina Today* editorial board.

Eric D. Donnenfeld, MD, is clinical professor of ophthalmology at NYU and a trustee of Dartmouth Medical School in Hanover, New Hampshire, and is Partner in Ophthalmic Consultants of Long Island in Rockville Centre, New York. Dr. Donnenfeld is a member of the *Cataract & Refractive Surgery Today* editorial advisory board.

Allen C. Ho, MD, is a Professor of Ophthalmology at Thomas Jefferson University Retina Service and Wills Eye Hospital in Philadelphia. Dr. Ho is the Chief Medical Editor of *Retina Today*.

Michael B. Raizman, MD, is a Clinical Ophthalmologist specializing in cataract and refractive surgery at Ophthalmic Consultants of Boston.

Richard F. Spaide, MD, is in practice at the Vitreous-Retina-Macula Consultants of New York in New York City and a member of the *Retina Today* editorial board.

R. Bruce Wallace III, MD, is Medical Director of Wallace Eye Surgery in Alexandria, Louisiana, Clinical Professor of Ophthalmology at the LSU School of Medicine, and Assistant Clinical Professor of Ophthalmology at the Tulane School of Medicine in New Orleans. Dr. Wallace is a member of the *Cataract & Refractive Surgery Today* editorial advisory board.

FACULTY DISCLOSURE DECLARATIONS

Jeffrey S. Heier, MD, states that he receives research support from Allergan, Inc., and ISTA; and is on the scientific advisory board for Allergan, Inc., Genentech, and ISTA.

Eric D. Donnenfeld, MD, states that he is a consultant for Advanced Medical Optics, Inc., Alcon Laboratories, Inc., Allergan, Inc., Bausch & Lomb, and Eyemaginations, Inc.

Allen C. Ho, MD, states that he is a consultant for Alcon Laboratories, Inc., Eyeteq, Genentech, Novartis, Occulogix, and QLT; is on the speakers' bureau for Alcon Laboratories, Inc., Eyeteq, and Genentech; and receives research support from Alcon Laboratories, Inc., Eyeteq, Genentech, Novartis, Occulogix, and QLT.

Michael B. Raizman, MD, states that he is a consultant for, on the speakers' bureau of, and receives research support from Alcon Laboratories, Inc., Allergan, Inc., Bausch & Lomb, Inspire, ISTA, and Vistakon.

Richard F. Spaide, MD, states that he is a consultant for Topcon and Heidelberg Engineering; and receives research support from Genentech.

R. Bruce Wallace III, MD, states that he is a consultant for Advanced Medical Optics, Inc., Allergan, Inc., and Bausch and Lomb.

The editors, publisher, and peer reviewer state that they have no relationships to disclose.

A Multi-Disciplinary Approach to the Management of Cystoid Macular Edema

Jeffrey S. Heier, MD: Cystoid macular edema (CME) was first described in 1953 by Irvine¹ and has been recognized for over 50 years as the most common cause of poor visual outcome following cataract surgery. At that time, intracapsular surgery was the treatment of choice and frequently resulted in CME. Advances in surgical technique, instrumentation, and pharmacotherapy have led to dramatic improvements in visual outcomes; however, pseudophakic CME remains the most common cause of disappointing visual outcomes after cataract surgery.

EVOLVING DEFINITION OF CME

Heier: Cystoid macular edema has traditionally been defined as a characteristic leakage in the macula, often described angiographically as a petaloid leakage, and has been associated with visual acuity of 20/40 or worse. Dr. Wallace, does this represent the current definition of CME from the standpoint of anterior segment specialists?

R. Bruce Wallace, MD: As anterior segment surgeons become more involved with imaging studies, we may change our minds about how we define sub-clinical CME. Although a reliable diagnosis for CME has been elusive, pre- and postoperative optical coherence tomography (OCT) imaging could change how we approach prevention.

Although treatment is important, the key to success with CME lies in prevention. Once the horse is out of the stall, so to speak, there will be long-lasting effects to the macula that can affect visual function, even when patients resolve to 20/20.

Richard Spaide, MD: After CME was further elucidated by Gass in 1969, there was increased scrutiny regarding the incidence of CME following intracapsular cataract surgery. Gass² and colleagues determined that the rates of angiographically evident CME peaked at approximately 6 weeks postoperatively. Only a few of these cases, however, were documented as resulting in decreased vision. These findings led to a distinction between angiographic and clinically significant CME. There are a number of different terms for CME that causes decreased vision.

We have patients today who are accustomed to the idea that cataract surgery instantly restores vision; their next-door neighbor was 20/20 at day 1 and never had a problem. So perhaps patients we previously thought had angiographic CME with no visual effects really did have some form of clinically significant disease. Back in the day of intracapsular surgery, patients were not refracted for quite some time post-operatively. Thus, the actual effects of angiographic CME may not have been characterized.

Eric D. Donnenfeld, MD: In the past, we looked at CME as a problem causing a decrease in Snellen visual acuity, which was uncommon but devastating when it occurred. Today, the definition of visual acuity after cataract surgery has shifted more from quantity to quality of vision. When a patient develops even subtle macular thickening that by traditional definition is not considered CME, quality of vision is decreased. Increasingly and appropriately, patients are demanding better outcomes after cataract surgery—and are willing to pay extra for it in the form of premium IOLs that promise better quality of vision and higher contrast sensitivity. We now know that even the subtlest thickening of the retina will decrease quality of vision and affect contrast sensitivity, and that this loss may be permanent after CME has been successfully treated. Thus, CME prevention is paramount for the successful cataract surgeon.

Spaide: One thing that we have observed with the new spectral-domain (SD) OCT imaging is that edema may locate in different areas in the macula—not only in terms of lateral topography but also in terms of its thickness. Some patients have inner retinal edema that has little effect on the photoreceptor layer and resulting visual acuity. Other patients have edema in the outer layers of the retina, and on OCT we lose the ability to see the boundary between the inner and outer segments of the photoreceptors—these patients have changes in their visual acuity from relatively small amounts of edema.

In a study that my colleagues and I performed many years ago, we found that there is not much correlation between visual acuity and what we see

on fluorescein angiography (FA).³ I would think, however, that there is some way to look at the OCT to have an idea of how the edema would affect a patient's vision.

DISEASE INCIDENCE AND MECHANISMS

Heier: Dr. Raizman, what is the estimated incidence of CME with current cataract techniques?

Michael Raizman, MD: Depending on how CME is defined, as many as 12% of patients who have no preexisting risk factors develop some visual changes in association with swelling of the macula after routine cataract surgery.⁴ Obviously, the incidence will be higher for patients who have risk factors for CME.

Donnenfeld: Twelve percent sounds like a moderate number, but there are approximately 3 million cataract surgeries performed in the US per year, 12% of which would be more than 300,000 cases of postcataract CME.

When the US FDA evaluates a new IOL for approval, one of the factors they consider is whether the lens is associated with what they deem an acceptable rate of clinical CME (20/40 or worse visual acuity post surgery), which is set at less than 5%. With this in mind, one could determine that a 12% rate of CME after cataract surgery is a public health issue.

Heier: Recently, Henderson et al⁵ published a study that reviewed 1,659 cataract cases performed by residents over a 5-year period. The CME rate in that study was 2.4% using currently available nonsteroidal anti-inflammatory drugs (NSAIDs). There are many surgeons, however, who do not acknowledge a 2% rate of CME with uncomplicated cataract surgery. Dr. Wallace, what are your thoughts on this discrepancy?

Wallace: This is part of the whole issue of how our definition of CME is evolving. Now that we have better tools to measure macular function and anatomy and we have patients with higher expectations after cataract surgery, we are likely to see more cases of CME that previously went undetected.

Raizman: A diagnosis of CME can be missed if it appears at times other than routine postcataract follow-up. Macular edema can develop 4 to 6 weeks after cataract surgery or even longer, and many cataract surgeons are not seeing their patients at that point. With newer imaging studies, I am realizing that macular

edema at 1 week is fairly common. I used to think that it took longer to develop.

Spaide: Retina specialists typically will not see these patients until CME has persisted for some time and there is a significant effect on their visual acuity, so I have a question regarding this mild form of CME. When the lens is extracted, a shift in the volume must occur as the vitreous moves forward; is subtle vitreous traction playing a role in the incidence of CME?

Donnenfeld: Vitreous loss is much more an issue in CME than traction. In conventional cataract surgery with a posterior-chamber lens, the vitreous will come forward a little bit, but I do not think that we see a lot of traction in these patients. In my opinion, it is the release of prostaglandins from the surgery itself that causes CME.



“A diagnosis of CME can be missed if it appears at times other than routine postcataract follow-up.”

– Michael B. Raizman, MD

Dr. Heier: Dr. Ho, should we be looking at different potential mechanisms for CME after cataract surgery, and should these affect our approach to prophylaxis?

Allen C. Ho, MD: Yes. We should be looking at different mechanisms for CME, and I do think these will affect our approach. CME is a very nonspecific anatomic finding that responds to a variety of stimuli, including prostaglandin/thromboxane release from tissues and cell membrane damage, both of which can be driven by cytokines released after intraocular surgery or in retinal vascular disease. Other mechanisms of CME relate to mechanical issues such as forward movement of vitreous after cataract surgery and subsequent macular traction or epiretinal mechanical distortion as observed in macular pucker.

Heier: Two of the possible pathways for CME seem to be the mediator pathway, to which you refer, and the initially described Irvine-Gass pathway, where there is some adhesion between the vitreous and anterior segment structures. Do you think the approach should be different for these two pathways?

Ho: In a disease for which there are a number of potential routes to stimulate clinically significant CME, it would be reasonable to attempt prophylaxis or treatment along each pathway. For example, one might use corticosteroids to achieve a higher level of inhibition of prostaglandin, thromboxane, and leukotriene synthesis; or one might use an NSAID to specifically inhibit the cyclooxygenase enzymes.

Steroid prophylaxis may be ineffective for patients with mechanical issues such as epiretinal membrane or vitreofoveal traction, so alternative pharmacologic prophylaxis is worth investigating.

DIAGNOSIS

Heier: Dr. Spaide, when a patient has been referred to you from an anterior segment surgeon and the vision is less than expected after uncomplicated cataract surgery, what kind of diagnostics do you perform?

Spaide: Usually, I will start by just talking with a patient, and they will normally note a dark or blurry spot in the central field of vision. On initial inspection, the eye may look fine in terms of the anterior segment. When you look with either a contact lens or indirect ophthalmoscopy or biomicroscopy, however, often there is thickening of the macula and loss of the normal foveal contour. Cystoid spaces may be visible, particularly if you use retroillumination coming off the retinal pigment epithelial (RPE) layer.

We then perform FA, because a significant percentage of patients with CME following surgery actually have occult choroidal neovascularization (CNV), and this must be ruled out. In CME, capillary telangiectasis and dilation is commonly seen on FA. These capillaries start to leak early, and the dye leaves the blood vessels and accumulates in the cystoid spaces. These cystoid spaces are often arranged in a petaloid arrangement around the central fovea and may contain large central foveal cysts.

We often supplement FA with OCT, because the latter can document the presence of a cystoid space. Although it was unexpected, we found that patients who have more severe CME often have macular detachment that is visible on OCT. In advanced SD-OCT imaging, abnormalities in the photoreceptor layer will be visible even in mild cases of CME, as evidenced by the loss of our ability to see the normally found boundary between the inner and outer segments of photoreceptors.

Ho: We typically document the initial presentation

with FA. Although many retina specialists are moving away from FA in favor of OCT, I still think it is important to have FA to distinguish between the subtle exudative age-related macular degeneration (AMD) and true pseudophakic CME. One of the hallmarks of CME in a patient with an otherwise normal retina would be hyperfluorescence of the optic disc, which is not seen with exudative AMD. For patients who have diabetes and have had cataract surgery, FA can be helpful to distinguish diabetic retinal vascular leakage vs pseudophakic CME.



“One of the hallmarks of CME in a patient with an otherwise normal retina would be hyperfluorescence of the optic disc, which is not seen with exudative AMD”

– Allen C. Ho, MD

Wallace: Will SD-OCT imaging allow you to distinguish exudative AMD from subclinical CME?

Ho: Yes, but in some patients with simple pseudophakic CME there may be detachment of the macula with submacular fluid, which we would often expect with exudative AMD but not with pseudophakic CME. In such a case, FA would be helpful to distinguish between the two.

Heier: There is a real push to avoid angiography because it is invasive. In my clinic, we obtain angiograms for all initial diagnoses of CME. There are a couple of cases that, on initial presentation, I thought were classic CME, but turned out to be subtle occult CNVs or old BRVOs. The actual diagnosis only became apparent after FA.

Donnenfeld: When a patient walks into your office after cataract surgery with a BCVA of somewhere around 20/40, a clinical exam will usually detect CME. For the more subtle cases, however, such as when a patient sees the 20/20 line haltingly, I will order an OCT evaluation. OCT does not have to be referred out to a retina specialist, especially if the anterior segment surgeon has a preoperative OCT with which to compare. When I perform LASIK and a patient is not 20/20

1 or 2 days after the surgery, I want to know why. Cataract surgeons need to develop that same proactive mentality.

Heier: Dr. Raizman, when will you either perform more diagnostics for a patient or refer to a retina specialist?

Raizman: If a patient has excellent visual potential, and I cannot explain postoperative visual acuity of less than 20/20 at 4 weeks, I will do an OCT. For more severe visual loss that cannot be explained, I will do an OCT at 1 week.

Spaide: Suppose you perform a cataract operation on a 90-year-old patient. Postoperatively, her visual acuity is 20/40, she has some pigmentary change to the macula, and she is happy with her results. What would you do with this patient?

Donnenfeld: When pigmentary changes in the macula can explain the loss of vision, I have decreased expectations. What I would want to know is the preoperative visual acuity and whether the cataract surgery has improved vision. If, for example, I see a patient who is preoperatively 20/40, has some maculopathy, and postoperatively remains at 20/40, I will want to investigate further. Alternatively, if I see a patient who was 20/200 preoperatively and improves to 20/40 with the surgery, I will accept that the pigmentary changes in the macula are the cause of the loss of visual acuity, and therefore be less aggressive in my approach.

Ho: The disconnect for retina specialists is that we often cannot predict how subtle macular changes—pigmentary alterations, for example—will affect vision. For instance, what is the visual acuity potential for a patient with typical age-related pigmentary changes and uncomplicated cataract surgery? There are a variety of factors anterior segment surgeons use to determine whether to pull the trigger on more imaging, but for the retina specialist, it can be difficult to determine which patients should be seeing 20/20 versus 20/40 based on the appearance of the macula.

Donnenfeld: The reason is that every one of your patients is coming in with macular changes. For us, cataract surgery with preoperative maculopathy is a rare event. To answer your question, I determine the need for more imaging based on the following:

Did the cataract extraction create the improvement of visual acuity we expected? If the answer is yes, we are happy. If it is no, then we move on to studies.

Heier: As Dr. Ho said, retina specialists are seeing patients with AMD all the time. We may see a patient with extensive retinal pigment epithelial changes whose visual acuity we would guess to be 20/60 or 20/80 when, in fact, it is 20/20. Another patient with only subtle RPE changes might also surprise us because he is at 20/60.

Wallace: Are retina specialists doing away with the Amsler grid now that we have objective measuring devices for the posterior segment?

Heier: Amsler grids are notoriously unreliable—this becomes more apparent the more frequently we use them. Although the test might be helpful in some patients for monitoring their overall vision for changes, the brain is incredibly adaptive at being able to ignore mild, even moderate Amsler-grid changes. I do not use this test frequently in my practice, and rarely in patients with diseases other than AMD

Spaide: I still use the Amsler grid for all of my patients; however, it can be hard to interpret abnormalities such as drusen or epiretinal membranes.

Ho: There is still some utility to the Amsler grid for patients with AMD, but we typically do not use it for diagnosing CME. Compliance, interpretation, false positive, and false negative responses are limitations of the Amsler grid, but it may be helpful to detect early changes in the character of central vision. I still use it for dry AMD patients and those with macular epiretinal membranes.

PROPHYLAXIS FOR CME

Heier: Dr. Donnenfeld, how do you approach prophylaxis for CME?

Donnenfeld: My colleagues and I performed a study that evaluated various lead times for administering NSAIDs preoperatively to effectively reduce the risk for CME.⁶ We compared pretreatment with ketorolac tromethamine (Acular; Allergan, Inc., Irvine, CA) for 3 days, 1 day, or 1 hour before surgery versus a control of no NSAIDs preoperatively, and we analyzed a variety of responses including OCT, macular

thickening, quality of vision, surgical response, and pupil size. We found that there was a significant difference between using an NSAID for 3 days versus either using one for 1 hour preoperatively, which seemed to have no protective effect, or not using one at all. There was a significant improvement between dosing for 1 day and 1 hour, and between 1 day and 3 days preoperatively. Based on the results, it appears that pre-treating with ketorolac for 3 days, possibly 2, is optimal for CME prophylaxis.

There really is no information available on how long after surgery an NSAID should be used. Based on my clinical experience, I have extended NSAID treatment out to 6 weeks postoperatively, but this is clearly an area that requires more research.

The study that, in my opinion, is the current gold standard in NSAID prophylaxis for CME is by Wittpenn et al.⁷ This study showed the incidence of CME could be significantly reduced by pretreating for 3 days with an NSAID. Additionally, an association was shown between macular thickening and quality of vision based on contrast sensitivity following surgery.

The item currently up for discussion within this topic is whether the improvement in visual acuity that occurs with NSAIDs is a short- or long-term phenomenon, and whether it is just Snellen visual acuity or if it is also quality of vision and contrast sensitivity.

Spaide: What is the main objection posed against using NSAIDs for prophylaxis? Is there a potential detriment to the cornea?

Donnenfeld: The objection centers around cost and inconvenience to the patient. Most of the safety issues have been resolved with the currently available topical NSAIDs.

Wallace: Inconvenience is not as much a factor as it has been in the past, because more surgeons are using steroids for 1 month or so postoperatively, which makes the burden of steroids versus NSAIDs similar if not the same.

Spaide: Is there is a difference between the various different NSAIDs that are currently available?

Donnenfeld: Although I have extensive experience with all of the currently available NSAIDs, I have used ketorolac tromethamine for more than 10 years, and there is more peer review literature with ketorolac

tromethamine than with all of the other NSAIDs combined. The outcomes of the Wittpenn study⁷ showed zero incidence of active overt CME in the patients who were pretreated with ketorolac. I see no reason to change the NSAID that I am using until I see data from a study showing a better option. Currently, no such study exists.

Heier: There are good data to suggest that NSAIDs can provide benefits in CME prophylaxis. In addition to the study to which Dr. Donnenfeld refers, I recall that as early as 1999, Raizman and McColgin⁴ showed the CME rate without NSAID prophylaxis (pre- and post-operative) was 12%, and with NSAIDs the CME rate was 0. Dr. Spaide's question, however, about whether there is an advantage of one of the NSAIDs over another, is interesting. The comparative studies of which I am aware all tend to be small, and frequently have confounding factors.

Raizman: To my knowledge, we have no studies showing significant differences. I always emphasize, however, that surgeons should be using a NSAID in conjunction with cataract surgery.

Heier: I have seen studies that suggest that penetration of one NSAID is superior to another, and that aqueous and vitreous concentrations differ among the available agents. These studies can be difficult to interpret. For instance, concentrations in the eye may relate to numerous factors, including the concentration of the drug being administered, the ability of the drug to get to the different compartments of the eye, and frequency of administration. In my opinion, the more important factors for retinal disease involve prostaglandin levels and prostaglandin inhibition. We performed a study in which patients with various retinal pathologies, such as epiretinal membranes and macular holes, were treated preoperatively with various NSAIDs. Undiluted samples were taken immediately at the start of surgery.⁸ While we showed decreased prostaglandin levels in the ketorolac patients versus bromfenac and nepafenac, the underlying disease states differed, and the samples were removed prior to the onset of surgical trauma (and the expected release of prostaglandins). In addition, the numbers were relatively small, making it even more difficult to extrapolate much meaningful information from this. The study did, however, demonstrate that all three NSAIDs penetrated to the back of the eye.

Spaide: We know from the arachidonic acid cascade that if the NSAIDs block cyclooxygenase, the arachidonic acid is still sitting around, and there is a potential that this released arachidonic acid may go down the lipoygenase cascade to make leukotrienes.^{9,10} Are you administering steroid concurrently to block leukotriene production?

Raizman: I think most surgeons use a combination approach. Intraocular leukotriene production is an insignificant form of inflammation, but steroids will help.



“I see no reason to change the NSAID that I am using until I see data from a study showing a better option. Currently, no such study exists.”

– Eric D. Donnenfeld, MD

Spaide: Some leukotrienes are extremely potent, even if they are present in very small amounts.

Raizman: Yes, but the trauma of cataract surgery does not seem to generate a clinically significant production of leukotrienes.

Heier: Dr. Donnenfeld, what would you estimate as the percentage of anterior segment surgeons who use NSAIDs as prophylaxis?

Donnenfeld: This use of NSAIDs has increased logarithmically in the past 3 years. I would estimate that in 2007, 80% of cataract surgeons were using NSAIDs.

If we asked the same question 3 years ago, the percentage would have been 25% or 30%. The more significant advance in cataract surgery over the past 5 years has been the routine use of NSAIDs in cataract surgery.

Ho: That the use of NSAID prophylaxis in routine cataract surgery has increased over the past several years speaks to either highly effective pharmaceutical marketing and/or clinical efficacy data in preventing postoperative CME. It is important to keep in mind the natural history of the condition, which typically results in the resolution of edema and improvement in vision.

Treating or preventing a disease that typically resolves on its own is obviously not as impressive as treating an enduring disease. As a retinal specialist who cares for patients with recalcitrant CME, there clearly are patients who suffer long-term vision loss. There are some comparative studies on NSAID prophylaxis; however, no brand has demonstrated clinical superiority over another in my mind.

HIGH-RISK PATIENTS

Heier: We have discussed NSAID use for routine cataract surgery. We all see patients who would be considered high-risk. We performed an analysis on 93 consecutive patients who were referred to our retina service with CME.¹¹ We were impressed to find that a large majority of these patients were what we would term *high risk*: 31% had diabetes; almost 30% were hypertensive; 15% had undergone previous ocular surgery; 11% had epiretinal membranes; and 9% had experienced complicated cataract extractions. None of them had anything other than routine prophylaxis with NSAIDs pre- and postoperatively; however, none had NSAIDs past 4 weeks postoperatively.

The study by Henderson et al showed that the risk for CME was no greater for patients with diabetes or who had complicated cataract surgery than for patients who had routine cataract surgery when NSAIDs were used for 3 months postoperatively.⁵

At Ophthalmic Consultants of Boston, we advocate a similar approach. High-risk patients start NSAIDs 1 week preoperatively and continue topical NSAIDs for 2 to 3 months postoperatively. This is not based on any large study, but simply our clinical impression that because these patients are high risk, when they develop CME, it will tend to be more refractory to current therapies.

Spaide: There is a long history of this practice in patients with uveitis. For example, we will administer an extra sub-Tenon's injection or increase the medications a patient is taking over the preoperative and postoperative period of cataract surgery as extra insurance against CME.

Raizman: Although the mechanisms of corticosteroids and NSAIDs are different, and there is no hard evidence to prove that 7 days treatment is better than 3 days, the goal is total inhibition of cyclooxygenase in the eye. Because we know that NSAIDs are safe, there seems to be no harm in starting a few days earlier in higher-risk patients.

Spaide: Some time ago, Miyake et al intentionally injected prostaglandins into primate eyes and found that this alone could not create CME, which led to the idea that factors other than just prostaglandins contribute to the formation of CME.¹²

Donnenfeld: The pharmacology of NSAIDs is such that the agents work by inhibiting the production of prostaglandins, with no effect on preformed prostaglandins.

If you start treatment with NSAIDs after cell membrane damage has occurred and prostaglandins have already been formed, it is too late. To control pain, inflammation, and CME, preoperative treatment is imperative; in my opinion, it is the most crucial aspect of improving surgical results. Treating postoperatively is beneficial and should be part of the NSAID regimen, but it is the inhibition of preexisting prostaglandins that really provides good results.

Heier: When we talk about high-risk patients and CME, retina specialists are commonly asked where AMD fits in the high-risk profile. I am not aware of any studies that demonstrated that AMD puts these patients at any higher risk. Dr. Ho, what are your thoughts on AMD and the link to CME?



“When we talk about high-risk patients and CME, retina specialists are commonly asked where AMD fits in the high-risk profile.”

– Jeffrey S. Heier, MD

Ho: We have not observed that AMD is an independent risk factor and, as you suggest, neither does the literature. Naturally, as retina specialists, we have a selection bias for patients who are symptomatic, so we have seen postoperative CME coexist with AMD.

Spaide: In theory, CME forms because more fluid is coming into the macula than can be pumped out. One of the bigger sources of removing fluid, from the sub-retinal space at least, is the RPE. As we age, there can be a loss of various functions we ascribe to the RPE. Right

now, we have an absence of evidence about this potential risk factor; we do not have evidence of absence.

Heier: Although we have not found AMD to be an independent risk factor for CME in our patients, it certainly poses a diagnostic challenge, because patients have underlying disease that can be hard to differentiate from CME.

APPROACHES TO REFRACTORY CME

Heier: Many of the CME patients we see have had some initial therapy on the anterior segment side, and they come to us with what could be termed *refractory CME*. Most routine cases involve patients with relatively uncomplicated medical or ophthalmic histories. The patients who make it to the retina specialist's office, however, often have complicated medical or ophthalmic histories. From the anterior segment specialist's viewpoint, which cases will you continue to treat, and which patients are referred to the retina specialist for further intervention?

Raizman: I will treat the majority of cases of CME on my own. The exception would be a patient with significant diabetic macular disease preoperatively or a patient with retinal vascular disease. These conditions warrant more aggressive therapy and consultation with a retina specialist.

When treating a patient for CME, I typically use a combination of steroids and NSAIDs four times per day for 1 month and see the patient back in 1 month, repeating the OCT at that point. If I see no improvement or minimal improvement, then I would refer the patient to a retina specialist.

Donnenfeld: I have a similar approach. I make one differentiation, however, which is not documented in the literature. When I see a patient who has OCT-proven CME (macular thickening), I usually manage him. If I see frank cyst formation, other structural changes to the retinal architecture, or significant visual loss, I become a little bit more worried and will refer that patient to the retinal specialist.

I immediately refer patients with diabetes, venous occlusive disease, or those who are high-risk and will most likely not respond to typical therapy.

Wallace: I also have a similar approach to treating CME. I tend, however, to routinely use a sub-Tenon's subconjunctival steroid, such as triamcinolone ace-

tonide (Kenalog, Bristol-Myers Squibb), that lasts approximately 3 to 4 weeks. We have seen some benefit with steroid, especially if there is any kind of anterior chamber reaction.

I treat the majority of my patients with CME, particularly since we have an OCT. For refractory cases that show no improvement on OCT after 2 weeks, I may become concerned and refer these patients to our vitreoretinal specialist.

Donnenfeld: Although we typically refer based on physical findings, sometimes psychosocial issues color my determination to refer as well. For example, my opinion is that patients who have extraordinary expectations should be in the hands of a retina specialist as soon as possible.

Heier: Dr. Spaide, we have heard how anterior segment doctors approach CME; what is your approach?

Spaide: I think for the retinal practice, we can divide the patients into five groups. The first group is those who have had good cataract surgery but have edema. Invariably, these patients are already being treated with steroids and NSAIDs; I usually would add sub-Tenon's triamcinolone.

The second group is composed of patients who have had some difficulty during surgery and some anterior-segment changes that led to CME, such as vitreous incarceration or retained lens fragments. Some of these patients respond to more aggressive treatment. Again, they are invariably on some kind of topical steroid and NSAID, and I will try a sub-Tenon's triamcinolone injection. They may need further anterior segment surgery, however, to fix the problem.

The third group are high-risk patients who have CME on top of existing retinal vascular problems. These can be patients, for example, who have underlying diabetic retinopathy or veno-occlusive disease. They need to have corticosteroid injection along with the topical drops they are already using, plus some attention paid to their retinal vascular problem. Patients with diabetic retinopathy may need focal laser photocoagulation, for instance.

The fourth group includes patients who have previously undetected traction on the retina, such as vitreomacular traction syndrome or epiretinal membrane, all of which has been brought to light by the cataract surgery. These patients may require more aggressive retinal therapy.

Finally, the fifth group represents the patients who have CME, but also have concurrent CNV. For these patients, treatment that is directed against CME along with CNV is required. Curiously, many of these patients will respond to anti-VEGF treatment through more than one mechanism.

Heier: Two recent reports on bevacizumab for treatment of chronic CME actually differ.^{13,14} In one study, the researchers felt that the response was good, and the other study was interpreted to show a minimal response with recurrence.

With refractory patients, we try almost everything we can, starting with topical therapy. If I am referred a patient who has been on topical therapy for fewer than 2 consecutive months, we will put him back on topical drops. In many instances, patients will come in listed as refractory, and they only have 2 to 4 weeks of topical therapy behind them. I have seen these patients respond with a longer duration of therapy.

Our second line of treatment for these patients is intravitreal injection. I find that the pericocular or intravitreal route often works well, but in general, I have seen a high recurrence rate in those patients—as high as 50%—that will require multiple injections.

Spaide: My strategy for a patient with refractory CME is slightly different in that, by the time the patient comes to see me, he has already been on topical corticosteroids and NSAIDs for some time; I never extend this treatment unless it has been as brief as 1 week. We know that topical corticosteroids have a fairly high incidence of inducing IOP increases, and in my experience, patients with severe CME generally do not respond well to topical medications. I generally find that a sub-Tenon's injection is pretty effective, and I will stop the topical corticosteroids while continuing the topical NSAIDs.

Donnenfeld: What do you think the risk for CME is for patients who are on prostaglandin analogue therapy for glaucoma?

Spaide: If the patient's capsule is closed, I do not think he is at higher risk for CME. We tend to view an open capsule, however, as a risk factor.

Ho: Without knowing the integrity of the capsule, it is difficult to answer this question, but I think that the incidence of CME caused by prostaglandin analogues used as pressure-lowering agents is relatively uncommon.

Our approach to refractory CME is slightly different. It is important to perform a careful examination of the anterior segment to check for any physical abnormalities that may be present in uncomplicated cataract surgery. For example, irritation to the uvea can result from a haptic within the sulcus, undermining pharmacologic therapy. The patients I see are usually already taking NSAIDs and steroids. For them, I will ask if they have been adherent to their drug regimen. If yes, then I will typically switch to periocular steroid injections. We tend not to give many intravitreal steroids because of potential complications. We have, however, seen some response to intravitreal bevacizumab (Avastin; Genentech, Inc., South San Francisco, CA), which I believe speaks to the multiple pathways that can incite CME in the eye.

Finally, pars plana vitrectomy can resolve recalcitrant CME, as well as CME in patients with complicated anatomy, vitreous in the wound, uveal incarceration, and iris tuck.

Donnenfeld: When I see complex anterior segment complications associated with florid CME, in the past, I would often have performed anterior segment reconstruction and sutured a posterior-chamber IOL. I have recently begun to trend toward a more conservative approach. I will actually reconstruct the anterior segment and remove the offending IOL if I do not think it can be placed in a more comfortable anatomic location, such as the ciliary sulcus. In certain circumstances, I will leave the patient aphakic for 2 or 3 months and allow the CME to resolve. I will then go back and implant a secondary IOL at a later date as a staged procedure. With this approach, I have been pleased with my CME resolution rate.

Heier: One of the anterior segment abnormalities that we find in patients with chronic CME is the presence of small amounts of retained lens material tucked up behind the iris, which can be difficult to see.

Ho: I think it is difficult to attribute CME to retained cortical material, because it is such a common finding and most patients never develop CME. While we have discussed the role of posterior-segment OCT imaging, anterior ultrasound biomicroscopy allows us to analyze the architecture and identify subtle iris chafe on the lens or a haptic that is eroding into the ciliary body. Those are the things that we look for. I am a more dubious about retained cortical material, because I think that is pretty common.

Spaide: Does haptic fibrosis eventually stop the production of prostaglandins?

Ho: Any time you have cell membrane disruption, you can stimulate the cycle. Haptic fibrosis may change the position of the lens-haptic complex minimally, but typically not enough to eliminate mechanical iris chafe or ciliary body irritation, for example, that is associated with cell-membrane disruption and initiation of the prostaglandin cycle.

Heier: Ongoing inflammation in patients with refractory CME can be subtle. We used endoscopy for one of these patients and found that there was a small amount of lens material stuck anteriorly. The inflammation was resolved after we removed the material. So, while I agree that retained lens material is common, it is uncommon to see ongoing inflammation in those patients. Dr. Ho's point about lens placement and ongoing iris irritation is important and is something that we should all look for.

Let's say you have taken all these steps and nothing has worked. Do you then do as Dr. Donnenfeld suggests and take out the IOL, making sure than any capsular remnants are removed?

Ho: The differential diagnosis for chronic inflammation in an uncomplicated cataract surgery patient expands beyond what are thought to be the common causes of CME, such as IOL malposition and retained cataract material. For example, chronic and low-grade bacterial or, more rarely, fungal infection can cause inflammation leading to CME.

In these situations, we consider reconstruction. I like the idea of a staged procedure, starting first with IOL repositioning and removal of residual cataract material. If this does not solve the problem, then IOL explantation could be considered, typically leaving patients aphakic until they demonstrate CME resolution.

In cases with a suspicion of low-grade chronic infection, we have removed the capsular bag and lens material and IOL implant to attempt to quiet the eye as an initial surgical procedure.

Heier: Would you use autofluorescence to identify cases of irreversible photoreceptor damage? Is there anything that would temper your decision to go in surgically?

Ho: A variety of factors would temper my decision to operate. I do not know that there is evidence for autofluorescence to predict visual potential, so I would not use

that test. Factors that should be taken into consideration when doing major anterior segment reconstruction include the status of the fellow eye, patient expectations, and confounding diseases such as AMD or maculopathy.

Wallace: I would like to pose a question to the group: If you have a patient with a history of CME in one eye, how do you treat the fellow eye in a case of CME?

Heier: I would place these patients in the high-risk category, although there are no data to support this. I would use an NSAID for 7 days preoperatively and then both steroid and NSAID postoperatively for a longer-than-usual time period, at least 6 weeks. Much of my treatment decision would be based on the patient's response in the first eye. If the first eye was a case of mild CME that was quick to respond, I might treat with steroid and NSAID for 4 to 6 weeks. If the first eye was a severe case of CME, I might keep the fellow eye on treatment for 2 to 3 months.

Spaide: Sometimes, we use triamcinolone to identify the vitreous in surgery or the internal limiting membrane. Invariably, some residual triamcinolone is left in those patients' eyes, and the eyes look quiet with a minimal amount of drug remaining. Do you think that a small amount of intravitreal or anterior chamber triamcinolone might be an approach worth considering?

Wallace: Some surgeons, including James Gills, MD, of Tarpon Springs, Florida, use this approach routinely.

Donnenfeld: I have started using intracameral triamcinolone and nonpreserved dexamethasone for patients with known CME. I will commonly inject behind the IOL before the end of surgery.

Ho: We will often use intravitreal triamcinolone acetonide during our vitrectomies for recalcitrant CME.

CONCLUSION

Heier: I would like to elicit closing thoughts from the panel on what our current knowledge is regarding CME and how our strategies for prophylaxis have evolved.

Spaide: In the past, CME was often regarded as a complication of cataract procedures to which no surgeon wanted to admit. As a result, patients were often

referred to the retina specialist very late. As we have gained a better understanding, however, it appears that all of us recognize CME as a normal part of surgery—part of the natural wound healing process in many of our patients.

This discussion has offered a rare opportunity for retina specialists and anterior segment surgeons to interact on a meaningful level about a complication that we both work to avoid, and if not avoid, treat successfully. Future studies must have both anterior and posterior segment specialists involved, and based on our discussion, it is clear that these studies must include contrast sensitivity and other visual function tests as a “higher bar” in visual acuity evaluation, and we should correlate these functional results with FA and OCT.



“Future studies ... must include contrast sensitivity and other visual function tests as a “higher bar” in visual acuity evaluation.”

– Richard Spaide, MD

Wallace: In this discussion, it has been noted that we are in an important time in the evolution of our understanding of CME; ocular imaging has the potential to offer clues to prevent and effectively treat CME. I was unaware that under the old definition of CME, and without the benefit of pretreatment with topical NSAIDs and steroids, 70% of cases resolved in 1 year and 90% resolved in 2 years. This is important information to impart to patients.

Treatment with NSAIDs has changed the way we practice, but it is also important for anterior segment specialists to understand how retina specialists are managing the severe cases we refer. And, as Dr. Spaide noted, more research into CME prophylaxis and treatment is crucial to improving our outcomes.

Ho: It has been extremely worthwhile to convene specialists working on both sides of the eye. An example of the information that I will take away from this discussion is that, although CME has a good history of natural resolution, patients who have resolved can often have subtle residual visual disturbances. Retina specialists

often view CME after cataract surgery as fairly routine; however, because of the sheer volume of cataract surgeries that are performed worldwide, paired with increased patient expectations, this is a significant health issue.

Donnenfeld: Speaking on behalf of all anterior segment surgeons, I would suggest that CME is what keeps us humble. The most skilled surgeons who achieve the most extraordinary outcomes have cases of CME that come back and bite us. This discussion has reinforced that there are good data to support the routine use of NSAIDs as preoperative and postoperative treatment for all cataract surgeries. By doing so and reducing the frequency of CME, we can improve surgical outcomes and provide our patients with better quality of vision.



“It is also important for anterior segment specialists to understand how retina specialists are managing the severe cases we refer.”

– R. Bruce Wallace III, MD

If, by providing the information that was discussed during this roundtable, we can convince just a few anterior segment surgeons to convert to the routine use of NSAIDs, I consider that a success. I personally have benefited from this gathering by learning about the use of anti-VEGF agents as well as surgical intervention for resolving difficult CME. Working together, anterior and posterior segment surgeons can devise clear treatment guidelines that will improve our patients' outcomes.

The main take-home point that I have gained from this discussion is that there is so much left that we do not know; more research must be performed.

Raizman: The bottom line is that CME cannot be taken lightly—the visual effects can be significant to patients and it is not always an easy condition to treat.

By optimizing prevention with topical NSAIDs, we have come a long way, and we should continue to look at ways to make prevention more foolproof.

Heier: For retina surgeons, CME is relatively common in our patients—we see CME after retinal reattachment surgery, or after membrane stripping. Our patients, however, have expectations not nearly as high as those of patients who have cataract surgery. Additionally, many patients undergoing cataract surgery are paying out-of-pocket for premium IOLs, a factor that we do not encounter.

I hope that we have met the goal of shedding light on current theories and approaches to the frustrating entity of CME, and have done so in a manner that will allow surgeons to incorporate some of these recommendations into their daily routines. ■

1. Irvine SR. A newly defined vitreous syndrome following cataract surgery. *Am J Ophthalmol.* 1953;36:5:599–619.
2. Gass JDM, Norton, EWD. Follow-up study of cystoid macular edema following cataract extraction. *Trans Am Acad Ophthalmol Otolaryngol.* 1969;73:665.
3. Spaide RF, Yannuzzi LA, Sisco LJ. Chronic cystoid macular edema and predictors of visual acuity. *Ophthalmic Surg.* 1993;24:4:262–267.
4. McColgin AZ, Raizman MB. Efficacy of topical diclofenac in reducing the incidence of postoperative cystoid macular edema. *Invest Ophthalmol Vis Sci.* 1999;40:289.
5. Henderson BA, Kim JY, Ament CS, et al. Clinical pseudophakic cystoid macular edema. Risk factors for development and duration after treatment. *J Cataract Refract Surg.* 2007;33:9:1550–1558.
6. Donnenfeld ED, Perry HD, Wittpenn JR, et al. Preoperative ketorolac tromethamine 0.4% in phacoemulsification outcomes: pharmacokinetic-response curve. *J Cataract Refract Surg.* 2006;32:9:1474–1482.
7. Wittpenn J, Silverstein SM, Hunkeler JD, Kenyon K; ACME Study Group. Subclinical cystoid macular edema reduces contrast sensitivity and final visual acuity in low-risk cataract patients. Presented at: the Association for Research in Vision and Ophthalmology Meeting; May 10, 2007; Fort Lauderdale, FL.
8. Busbee BG, Heier JS, Waterbury D, et al. Comparison of vitreous PGE2 concentrations of ketorolac 0.4%, bromfenac 0.09%, and nepafenac 0.1% in patients undergoing vitrectomy. Poster presented at the Association for Research and Vision in Ophthalmology Annual Meeting. May 10, 2007; Fort Lauderdale, FL.
9. Picado P. COX-2 specific inhibitors in NSAID-intolerant patients. *Int J Immunopathol Pharmacol.* 2003;16:11–16.
10. Brune K. Safety of anti-inflammatory treatment—new ways of thinking. *Rheumatology (Oxford).* 2004;43:16–20.
11. Heier JS, Daniel P. Characteristics of patients with cystoid macular edema following phacoemulsification. Paper presented at: The Annual Meeting of the American Academy of Ophthalmology; November 2007; New Orleans, LA.
12. Spaide RF. Cystoid Macular Edema After Ocular Surgery. In: *Ophthalmic Surgery Complications. Prevention and Management.* Charlton J, Weinstein GW, eds. Philadelphia: J.B. Lippincott; 1995.
13. Arevalo JF, Garcia-Amaris, RA, Roca JA, et al; Pan-American Collaborative Retina Study Group. Primary intravitreal bevacizumab for the management of pseudophakic cystoid macular edema. Pilot study of the Pan-American Collaborative Retina Study Group. *J Cataract Refract Surg.* 2007;33:2098–2105.
14. Spitzer MS, Ziemssen F, Yoeruek E, et al. Efficacy of intravitreal bevacizumab in treating postoperative pseudophakic cystoid macular edema. *J Cataract Refract Surg.* 2008;34:70–75.

A MULTI-DISCIPLINARY APPROACH TO THE MANAGEMENT OF CYSTOID MACULAR EDEMA

INSTRUCTIONS FOR CME CREDIT

1 AMA PRA Category 1 Credit™

Expires June 2009

CME credit is available electronically via www.dulaneyfoundation.org.

To answer these questions online and receive real-time results, please visit www.dulaneyfoundation.org and click "Online Courses." If you are experiencing problems with the online test, please e-mail us at support@dulaneyfoundation.org and explain the details of any problems you encounter with the Web site. Alternatively, you can fax your exam to us at +1-610-771-4443. Indicate how you would like to receive your certificate below. Please type or print clearly or we will be unable to issue your certificate.

Name _____ MD participant non-MD participant

Phone (required) _____

I would like my certificate sent via fax _____

I would like my certificate sent via e-mail _____

CME QUESTIONS

- The traditional definition of cystoid macular edema (CME) includes:**
 - characteristic leakage in the macula
 - petaloid leakage seen on angiography
 - visual acuity \leq 20/40
 - all of the above
- The US Food and Drug Administration consider the following rate of CME to be acceptable after implantation with an IOL:**
 - 10%
 - 12%
 - 3%
 - 5%
- According to a study by Wittpenn et al, the incidence of CME can be significantly reduced after cataract surgery by pretreating with a nonsteroidal antiinflammatory drug (NSAID):**
 - 1 hour before cataract surgery
 - 3 days before cataract surgery
 - 1 day before cataract surgery
 - 1 week before cataract surgery
- Data have shown that patients who have diabetes or other complicating factors with cataract surgery have no higher risk for CME when dosed with NSAIDs for 3 months postoperatively.**
 - true
 - false
- A retrospective study performed on cataract cases performed by residents found that, when using the currently available NSAIDs, the CME rate was:**
 - 0.5%
 - 5%
 - 2.4%
 - 1.8%
- After cataract surgery, the window of time for when CME may develop can be as small as:**
 - 3 weeks
 - 4-6 weeks or longer
 - 1 week
 - none of the above
- In a 1999 study, Raizman and McColgin found that _____% of patients who had no preexisting risk factors for CME and who received only corticosteroids preoperatively developed significant CME.**
 - 5%
 - 10%
 - 2.5%
 - 12%
- For patients with diabetes, retinal vascular leakage can be distinguished from pseudophakic CME by:**
 - Amsler-grid testing
 - fluorescein angiography
 - Snellen acuity testing
 - none of the above
- In a study by Donnenfeld et al, in which they evaluated various lead times for administering NSAIDs preoperatively to effectively reduce the risk for CME, they found that:**
 - using an NSAID 1 hour preoperatively seemed to offer no protective effect
 - there was a significant improvement in CME when dosing with an NSAID for 1 day vs 1 hour preoperatively
 - pretreating with an NSAID for 3 days provided the best protection against CME
 - all of the above

