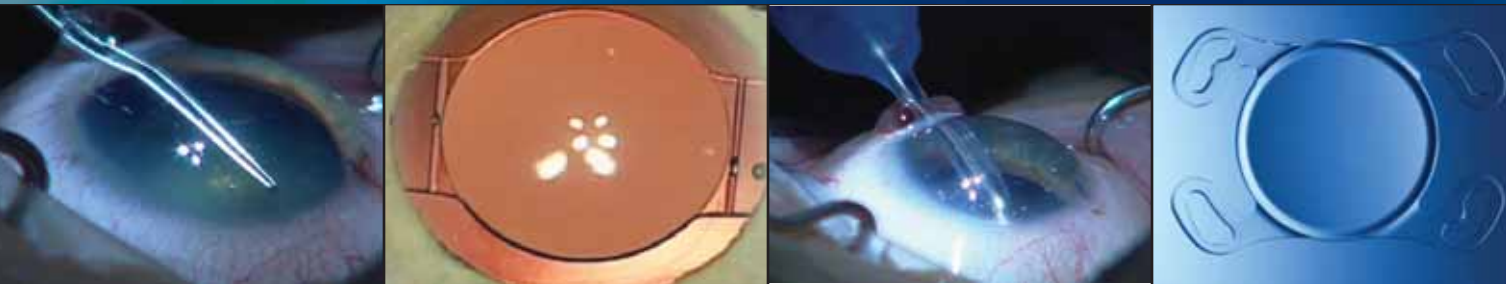


Cataract & Refractive Surgery TODAY

Microincisional Cataract Surgery With the 1.8-mm MICS Phacoemulsification System



Surgeon experience with the
Stellaris Vision Enhancement
System, the Crystalens HD,
and the Akreos AO IOL.

Microincisional Cataract Surgery With the 1.8-mm MICS Phacoemulsification System

Surgeon experience with the Stellaris Vision Enhancement System, Crystalens HD, and Akreos AO IOL.

INTRODUCTION

Cataract surgeons are increasingly adopting the use of microincisions because of substantial evidence of the greater surgical control, improved outcomes, and better postoperative sealing they provide compared with traditional 3-mm incisions.^{1,2} This trend necessitates a microsurgical phaco system that facilitates the transition to microincisional cataract surgery (MICS) and balances safety and surgical control with ease of use. Here, notable early adopters of the MICS technique discuss why they chose the Stellaris Vision Enhancement System (Bausch & Lomb, Aliso Viejo, CA) and how it has improved their cataract surgery, and why they enlarge the incision to implant a Crystalens HD and an Akreos AO IOL.

1. Paul T, Braga-Mele R. Bimanual microincisional phacoemulsification: the future of cataract surgery? *Curr Opin Ophthalmol*. 2005;16(1):2-7. Review.

2. Weikert MP. Update on bimanual microincisional cataract surgery. *Curr Opin Ophthalmol*. 2006;17(1):62-67. Review.



PANEL

Richard L. Lindstrom, MD (Moderator), is the founder and attending surgeon of Minnesota Eye Consultants, and he is adjunct professor emeritus at the University of Minnesota in Minneapolis. He is a paid consultant to Bausch & Lomb. Dr. Lindstrom may be reached at (952) 888-5800; rllindstrom@mneye.com.



John D. Hunkeler, MD, is a clinical professor and former chair of the Department of Ophthalmology at the University of Kansas School of Medicine in Kansas City. He acknowledged a financial interest in Thinoptx, and he is a paid consultant for Bausch & Lomb. Dr. Hunkeler may be reached at (816) 931-4733; jhunkeler@hunkeler.com.



Louis D. "Skip" Nichamin, MD, is the medical director of the Laurel Eye Clinic in Brookville, Pennsylvania. He is a paid consultant for Bausch & Lomb. Dr. Nichamin may be reached at (814) 849-8344; nichamin@laureleye.com.



Jay S. Pepose, MD, PhD, is a professor of clinical ophthalmology and visual sciences at the Washington University School of Medicine, and the director of Pepose Vision Institute in St. Louis. He is a paid consultant to Bausch & Lomb, and Visiogen. Dr. Pepose may be reached at (636) 728-0111; jpepose@peposevision.com.

EVOLUTION TOWARD SMALLER INCISION SIZE IN CATARACT SURGERY

Dr. Lindstrom: I first entered into practice as an anterior segment surgeon in 1977, and I was trained in intracapsular cataract extraction (ICCE). We cataract surgeons have come a long way in the subsequent 32 years. What are some of the changes that you have witnessed since you began practicing cataract surgery?

Dr. Hunkeler: I was also trained in ICCE, which I used for the first 3 years I was in practice. In 1975, however, I began training in phacoemulsification. Shortly thereafter, I converted to extracapsular cataract extraction (ECCE). I did not start using phacoemulsification regularly until 1986, because the IOLs available before this time were too large to implant through a phaco incision.

From a historical perspective, the main reason that Charles D. Kelman, MD, invented phacoemulsification was to permit a smaller incision that would facilitate faster visual rehabilitation. This would allow cataract patients to be fit with a contact lens earlier than with traditional ICCE surgery, as opposed to implanting an

“The driving forces behind the advent of phacoemulsification and smaller incisions were not only control and safety, but also refractive outcomes.”

—Richard L. Lindstrom, MD

IOL. Before phacoemulsification was widely used, surgeons were accustomed to seeing ocular trauma from large incisions and instruments. Eyes often required vitrectomies and suturing for corneal injury.

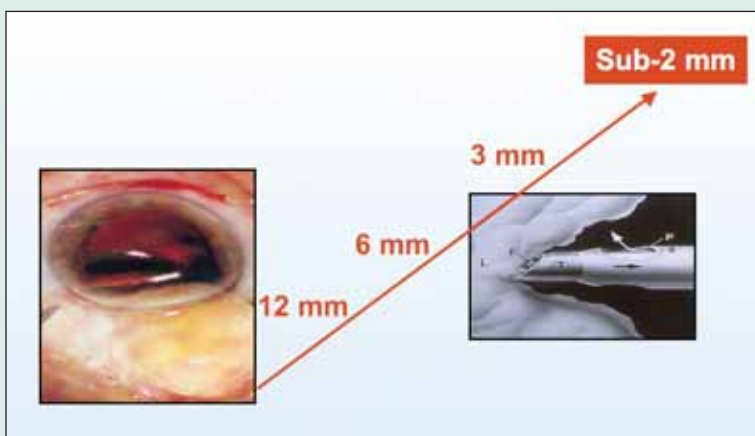
Dr. Nichamin: I trained in the mid-1980s in a progressive program at the Sinai Hospital of Detroit, where there were several early adopters of phacoemulsification. By the time of my graduation, phacoemulsification was my preferred method of cataract extraction. Early in my private practice career, a large

THE EVOLUTIONARY TREND TOWARD SMALLER CATARACT INCISIONS

The evolutionary trend for cataract surgery is using phacoemulsification techniques through continually smaller incisions (microincisional cataract surgery [MICS]).

Surgeons now prefer incisions of 2 mm or less for the least invasive method possible (incisions must be 2 mm or less to qualify as true microincisions).

Until recently the coaxial threshold was a 2.2-mm incision. New microincisional IOLs can pass through smaller injector lumens, maintain ocular stability and provide good postoperative outcomes. Such developments will continue to drive the market to sub-2-mm MICS. For example, the new Akreos AO Micro Incision Lens is intended to position Bausch & Lomb as the “1.8-mm company.”



percentage of my surgeries comprised vitreoretinal procedures, and I therefore became accustomed to the control of closed-chamber posterior-segment surgery. Because of this, I have never been comfortable with the large incisions used in ECCE procedures. Unfortunately, when I initially entered private practice in Pennsylvania in the mid-to-late 1980s, many of the hospitals did not yet have phaco machines, and I lost a good amount of sleep over having to perform ECCE, “open-eye” surgery. I consider it another major breakthrough when the watertight, self-sealing incision of approximately 2.6 mm was made possible in the mid-1990s. With that said, I believe that microincisional coaxial surgery (MICS) represents the next big breakthrough in phaco technology.

“The Stellaris gives me better control throughout the cataract procedure because of being able to use a smaller incision, and I am also better able to control astigmatism.”

—John D. Hunkeler, MD

Dr. Lindstrom: The driving forces behind the advent of phacoemulsification and smaller incisions were not only control and safety, but also refractive outcomes. Both ICCE and ECCE induced a significant amount of astigmatism—in my experience, approximately 90% to 95% of patients had 3.00 to 4.00 D of induced against-the-rule astigmatism postoperatively after the sutures were removed or absorbed. When I began implanting IOLs, we did not perform biometric calculations; we implanted the same IOL power in most patients. When biometry became available, we began targeting specific refractions and correcting astigmatism.

THE CASE FOR SMALLER INCISIONS

Dr. Lindstrom: What convinced you that phacoemulsification was the best procedure for cataract surgery?

Dr. Hunkeler: The risk of retinal detachment was much higher with ICCE, so I would say that safety was my number-one reason for converting to phacoemul-

sification. I do believe, however, that many surgeons did not appreciate the benefits of phacoemulsification until IOLs that could pass through smaller incisions became available.

My crossover point was when I became involved with the PhacoFlex SI30 (Allergan, Inc., Irvine, CA). Seeing that a silicone IOL could work as well as a PMMA lens and also could pass through a smaller incision convinced me that phacoemulsification with foldable IOLs was a better procedure.

Dr. Pepose: Safety was my primary reason for adopting phacoemulsification. Although smaller incisions and foldable IOLs improved the safety of cataract surgery, we cannot discount advances in phaco technology. The early phaco machines raised awareness among cataract surgeons regarding the use of ultrasound power and the stability of the anterior chamber, the latter of which has the most significant effect on avoiding complications such as capsular rupture.

Dr. Hunkeler: The homeostatic environment is extremely important for maintaining safety throughout the cataract procedure.

Dr. Lindstrom: As cataract surgery has evolved and incisions have become progressively smaller, these transitions have been gradual. However, the Stellaris Vision Enhancement System (Bausch & Lomb, Aliso Viejo, CA) features technology that has reduced phaco incisions from 3 mm to less than 2 mm, which is a significant change. Do you see a significant difference in your surgical safety and control with the Stellaris system?

Dr. Hunkeler: I was fortunate to be an early user of the Stellaris, and based on my positive experience, I have since purchased two of these systems. The Stellaris gives me better control throughout the cataract procedure because of being able to use a smaller incision, and I am also better able to control astigmatism. Overall, I find that patient satisfaction with this system is off the charts.

THE IMPORTANCE OF INCISION SIZE

Dr. Lindstrom: Most surgeons are using 3-mm incisions, and I would venture that if asked, most would report overall patient satisfaction. What would you say to fellow cataract surgeons as to why they should consider a sub-2-mm incision for phacoemulsification?

Dr. Pepose: Incisions smaller than 2 mm are astigmatically neutral. At 3 mm, most surgeons induce approximately 0.50 D of astigmatism.

When I converted to a sub-2-mm incision, the first thing I noticed was the incredible stability of the anterior chamber, especially in my patients at risk for intraoperative floppy iris syndrome (IFIS). The small incision decreased the amount of irrigation flow significantly, and it occurred to me that I had never realized how much fluid is required to keep the anterior chamber full with a 2.75- or 3-mm incision.

The new phaco machines have longer stroke lengths, faster on/off cycles, and more efficient wave modulations, which enable the surgeon to use less power and separate the phaco power from the irrigation flow. Additionally, the phaco tips are smaller and provide better visibility. All of these factors have increased the safety of cataract surgery.

Dr. Hunkeler: When I observed how much less fluid the Stellaris system used with sub-2-mm incisions, I was prompted to determine how much fluid I was actually using. Because no phaco machine is designed to measure flow rate, I hooked up a digital scale to the bottle of balanced salt solution. By resetting the digital scale before each stage of the procedure, I was able to measure the flow rate. I found that I was using twice the amount of fluid with the 2.2-mm incision made with the Infiniti Vision System with the Intrepid Fluidic Management System (Alcon Laboratories, Inc., Fort Worth, TX) than with the Stellaris system through a 1.8-mm incision (Figure 1). The decrease in fluid translated to less turbulence in the anterior chamber when I used the Stellaris.¹

“The decrease in fluid translated to less turbulence in the anterior chamber when using the Stellaris.”

—John D. Hunkeler, MD

Dr. Nichamin: From the surgeon's perspective, there is a true “wow” factor with the Stellaris Vision Enhancement System. First, the keratome for the incision that is used with the Stellaris system is so small that it looks like a paracentesis blade. Second, the

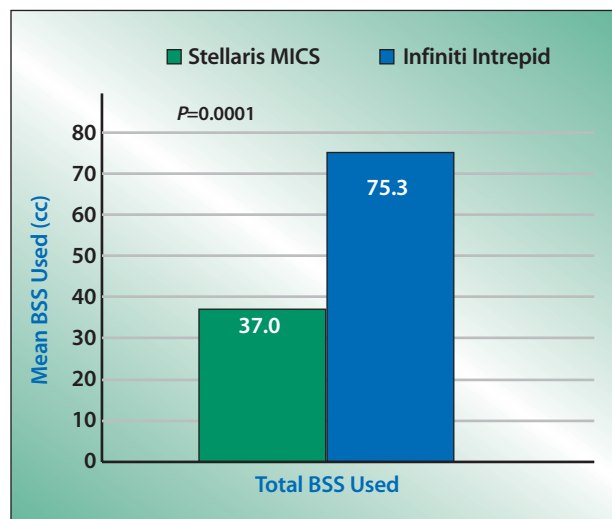


Figure 1. Twice the amount of balanced salt solution is used with a 2.0-mm incision made with the Infiniti Intrepid system compared with the 1.8-mm incision made with Stellaris MICS phacoemulsification.

phaco instrument is petite and elegant, so that if a surgeon reverts back to a conventional phaco instrument, he or she feels like a bull in a china shop inside the eye. As we all know, control is a requirement for complex cataract surgery.

Dr. Lindstrom: What are some of the additional reasons that incision size is important?

Dr. Nichamin: Based on the research of Paul Ernest, MD, of Michigan, we know that square wound construction is important in ensuring postoperative incisional stability,² and creating a square incision of 1.8 mm is rather simple. In my opinion, square microincisions maintain their integrity better than a larger incision, even if they must be enlarged to accommodate an implant. The tissue of the enlarged incision has not been previously stretched or traumatized.

Dr. Pepose: With a sub-2-mm incision, there is almost no egress of the ophthalmic viscosurgical device (OVD). The iris and all other ocular structures are completely stable, and the phaco fluidics function much like an additional surgical instrument that pushes the lens material into the phaco tip. Because I now use so little phaco power with the Stellaris, I find that I actually have to remind myself to depress the footpedal slightly to maintain the flow and keep the tip unoccluded.

Dr. Nichamin: As I mentioned, because I have a background in posterior vitrectomy, I have always favored a bimanual surgical technique, where the infusion is separated from the aspirating port. When I first began performing biaxial phacoemulsification, however, I found that I had difficulty getting it to work as efficiently as coaxial phacoemulsification. In my opinion, the integrity of the wound and the fluidics are not as good with a MICS biaxial technique.

“Using such low power on the Stellaris system has changed my phacoemulsification to a fluidics-based operation.”

—Louis D. “Skip” Nichamin, MD

Dr. Lindstrom and I were fortunate to be involved in the early design phases of the Stellaris system. Bausch & Lomb, asked us to come up with a wish list for a next-generation phaco machine. At the top of our list were safety and control, but also high on the list was the best possible fluidics and an incision size of less than 2 mm. Frankly, I am still a little surprised and quite impressed that the Stellaris system achieved all of these goals. (See Figures 2 and 3 for examples of a 1.8-mm capsulorhexis.)

PEARLS FOR ENLARGING AN MICS INCISION

Dr. Lindstrom: The recently FDA-approved Akreos MICS IOL (Bausch & Lomb), is the first lens to be implantable through a 1.8-mm incision. Now that we have this IOL available, we will be able to provide a complete MICS procedure to our patients. Prior to having this IOL that can be inserted through the 1.8-mm phaco incision, however, we have enlarged the incision to insert the IOL. This is especially true for multifocal or accommodating IOLs. How do you go about this task?

Dr. Nichamin: I operate temporally, and my goal in surgery is to make my entire procedure as reproducible as possible. I use a single-plane, temporal, 1.8-mm clear corneal incision. I also take considerable care in creating my paracentesis, because this step can significantly affect wound leakage. Many surgeons lose

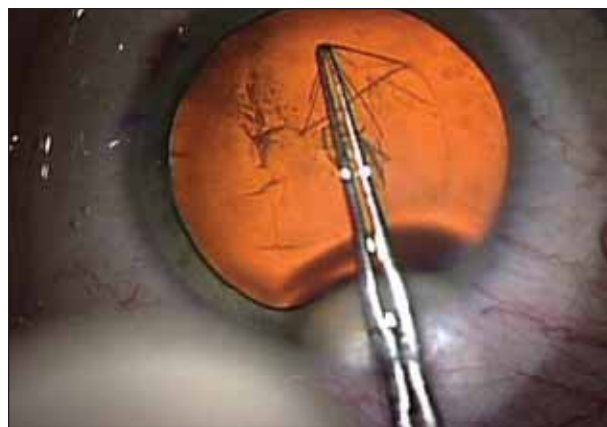


Figure 2. A microcam view of a 1.8-mm capsulorhexis created for phacoemulsification and implantation of the Crystalens HD. Live surgery by Jeffrey Whitman, MD, at the annual meeting of the American Society of Cataract and Refractive Surgery (ASCRS); April 3-8, 2009; San Francisco, CA.

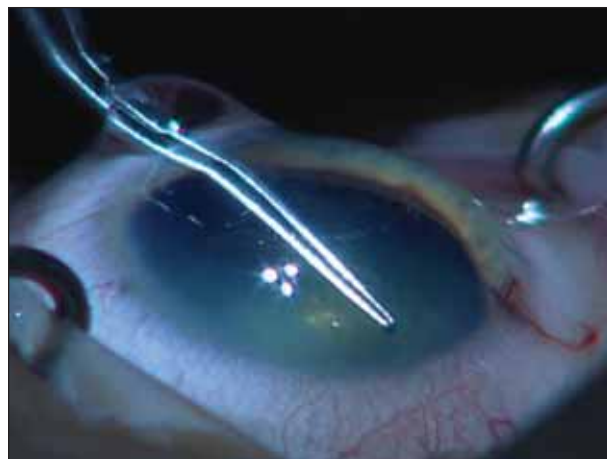


Figure 3. A sidecam view of a 1.8-mm capsulorhexis created for phacoemulsification and implantation of the Crystalens HD. Live surgery by Jeffrey Whitman, MD, at the annual meeting of the ASCRS; April 3-8, 2009; San Francisco, CA.

more fluid unintentionally through their sideport than they do through their main incision. I use a Fine Triamond blade (Mastel, Rapid City, SD) to create the sideport incision 90° away at either 6 or 12 o'clock, and then I instill lidocaine. I next make a temporal, single-plane, clear corneal incision using a 1.8-mm dedicated diamond blade (Bausch & Lomb). I do not instill an OVD prior to creating the incision. Unless I am worried about IFIS, I will use Amvisc Plus (Bausch & Lomb) instilled via a cystotome, with which I also initiate my capsulorhexis. I complete the capsu-

lorhexis with the microincision forceps.

I have found that the only step in my routine phaco procedure that involved a learning curve with the Stellaris system, and it was minimal at best, is performing the capsulorhexis through a 1.8-mm incision. One can simply use a cystotome or any one of many new dedicated microincisional capsulorhexis forceps. The microincision more effectively retains the OVD, which makes creating the capsulorhexis easier. However, it is important to decompress the anterior chamber a little bit to remove some OVD after completing the capsulorhexis and prior to hydrodissection in order to reduce stress on the capsule and avoid a possible hydrostatic blow-out. I do this by pressing on the posterior lip of the wound and "balloting" a bit of the OVD out. This is an important step, because otherwise, the chamber can become overinflated.

Next, I perform hydrodissection and hydrodelineation. My procedure is a combined vertical and traditional horizontal chop. I begin with vertical chopping, and as chopped segments form, I pull them centrally and chop horizontally to a smaller nuclear segment, which I then aspirate. Using extremely low phaco energy afforded by the advanced power modulations of the Stellaris system has changed my phacoemulsification procedure to a fluidics-based operation that is composed of bimanual disassembly and then almost entirely aspiration. I do hydrodelineate, because I find it easier to liberate and purchase the smaller endonuclear segments. After removing the remaining epinucleus, I perform I/A with a custom-made silicone-sleeved instrument that prevents incisional leakage and enhances cortical removal. When I enlarge the incision with my paracentesis diamond blade for IOL implantation, I try to stay in the original plane and enlarge it on just one side to keep the area as pristine as possible.

TIPS AND TECHNIQUES FOR MICS

Dr. Lindstrom: Do you make the walls of your incision parallel or trapezoidal?

Dr. Nichamin: I make them somewhat trapezoidal. I enlarge the incision to make it a bit wider on the outer margin—approximately 2.7 to 2.8 mm—to accommodate my injector. After I place the IOL, I use I/A to remove the OVD, but I switch to a thicker "conventional" silicone sleeve to maintain a watertight incision through the now enlarged wound. Finally, I hydrate both incisions in 100% of my cases to ensure proper sealing.

Dr. Lindstrom: I have heard some surgeons argue that regardless of technique, microincisions that must be enlarged do not seal as well as larger incisions that can accommodate phacoemulsification and IOL implantation.

"The Stellaris system's operating temperature is so cool that it does not damage tissue like other phaco systems' bare needles may."

—John D. Hunkeler, MD

Dr. Hunkeler: It depends on the phaco system you are using. The Stellaris' operating temperature is so cool that it does not damage tissue like other phaco systems' bare needles may.

Dr. Lindstrom: Dr. Pepose, among this panel, you transitioned to MICS using the Stellaris system most recently. What has your experience been with converting to MICS with this phaco system?

Dr. Pepose: During the past 8 weeks, I have converted to MICS in steps to ensure a smooth a transition. The biggest hurdle for me was making the smaller capsulorhexis; I was most worried about oarlocking. I found finer-tipped capsulorhexis forceps (Storz) that work well. Now, the only difference in my technique is that I grasp the edges of the smaller incision somewhat more frequently than I would with a 2.75-mm incision. Maintaining control of the capsulorhexis is particularly important if I am implanting a Crystalens HD Accommodating IOL (Bausch & Lomb), for which I mark the eye at 5.50 mm and cut just outside of that, at between 5.75 and 6.00 mm. If the incision is too large, it increases the risk of the lens' vaulting. I make my paracentesis first with a 1.5-mm blade, and I keep it small, because this is where most leakage occurs.

I use a single-plane incision, and then I stain it at the end of the case with a fluorescein strip to check for leakage.

Dr. Lindstrom: Do you use an OVD in your side-port incision?

Dr. Pepose: Yes, but I try not to overinflate the eye before I make my initial temporal incision. To achieve compression over the anterior capsule for making the capsulorhexis, I reinflate the eye beforehand.

Dr. Lindstrom: What is your favorite knife for making your incisions?

Dr. Pepose: Initially when I transitioned, I used a 2.2-mm steel blade for the external incision, and I decreased the diameter to 2.0 mm internally. I have worked toward a trapezoidal incision with an internal diameter of 1.8 mm. In my experience, an incision any tighter than this results in too much movement of the eye. I find that wetting the tubing of the phaco sleeve with balanced salt solution reduces resistance and the eye's rotation. To enlarge the incision for implanting the IOL, I use the same steel blade with which I created the temporal incision, and I enlarge it on both sides. I hydrate the incision to create downward compression and a watertight seal.

Dr. Lindstrom: Do you feel that the 1.8-mm incisions enlarged to 3.0 mm allow for enhanced control and safety compared to the 2.8-mm or 3.0-mm incisions?

Dr. Pepose: In terms of control and safety, I find these incisions to be comparable with one another during standard cases. I noticed more control, however, during challenging cases like eyes with IFIS or shallow anterior chambers. The difference is more subtle on standard cases, because the Stellaris system allows for so much more control of the entire procedure—the incision size is sort of the icing on the cake.

IOL IMPLANTATION WITH MICS

Dr. Lindstrom: What is your technique for IOL implantation following MICS phacoemulsification?

Dr. Hunkeler: I also use stainless steel knives, with the exception of my limbal relaxing incision knife. I begin by making a trapezoidal paracentesis just to the left of where my primary incision will be, because I am right-hand dominant. I prefer a bevel-up steel blade, so that I can achieve a sufficiently planar incision into the anterior chamber. I use a second blade to create the trapezoidal angle. Going in, I make the incision fairly square, widening it to approximately 2.5 mm and then narrowing the incision internally to approximately 1.7 mm. I do not use any OVD in the

anterior chamber when widening the incision; I prefer to instill it afterward. I use a bent 22-gauge needle to create a 5.5- to 6.0-mm capsulorhexis, and I keep it parallel to the pupil. Because most of my patients are elderly, I use hydrodissection alone, because effective hydrodelineation is a challenge with this age group.

For emulsification, I use a modified stop-and-chop technique: I make a groove and perform posterior polar exploration, cracking the nucleus in the middle into two heminuclei. Using a spatula, I pull off fragments, remove the sections, and perform I/A with a standard 1.8-mm irrigation sleeve. (See Figures 4 and 5 for examples of I/A with the Stellaris system.) Afterward, I polish the capsule. I then reinflate the anterior chamber, enlarge the incision to 3.0 mm, and insert the injector.

“The Stellaris system allows for so much more control of the entire procedure—the incision size is sort of the icing on the cake.”

—Jay S. Pepose, MD

After the IOL is implanted, I remove the OVD. The newer surgical microscopes, such as the Lumera (Carl Zeiss Meditec, Inc., Dublin, CA), show a significant amount of OVD behind the IOL that was not previously visible. I spend a considerable amount of time removing this excess OVD, because I believe it to be of critical importance to successful outcomes, especially with the Crystalens. I hydrate the incision 100% of the time, paying particular attention to the paracentesis. One must be careful, however, not to overhydrate and exceed the pressure of the central retinal artery. After I am sure the incisions are watertight, I release the balanced salt solution.

Dr. Pepose: I find that for my Crystalens patients, I must take special care when vacuuming the underside of the anterior capsule, a task that sub-2-mm incisions make even more difficult. I now use the 1.75-mm diameter, low-profile Shepard Capsule Polishing Curette (Katena Instruments, Denville, NJ). This instrument has enough of a curve that I can polish all of the subincisional epithelial cells off the underside of the anterior capsule for 360°.

Dr. Lindstrom: If necessary for the case, I will make a corneal relaxing incision prior to any other surgical maneuver, because I prefer to not have these affect my cataract incision. (See Figures 6-8 for examples of LRIs for a Crystalens HD case).

"I use several different IOLs depending on the situation, but my favorite IOL for correcting presbyopia is the Crystalens HD."

-Richard L. Lindstrom, MD

I use several different IOLs depending on the situation, but my favorite IOL for correcting presbyopia is the Crystalens HD. I prefer the Akreos AO IOL for achieving monofocal aspheric vision.

I make my paracentesis incision first. One trick I use is to coat the corneal surface with Ocucoat (Bausch & Lomb), which works particularly well to protect the cornea when implanting a premium IOL and thereby improves visual recovery on the first postoperative day. I use an Osher diamond-blade knife (Bausch & Lomb) to create the 0.8-mm sideport incision. I instill xylocaine as if I were hydrating the wound, and I place the needle against the stroma to allow the xylocaine to enter the eye. I find that this step enhances the sealing of the sideport incision. I used to make

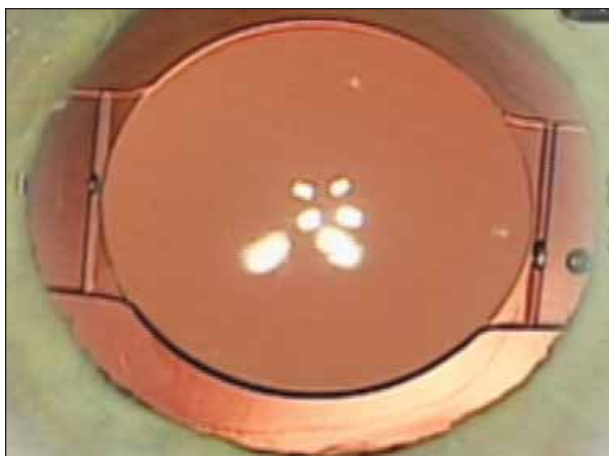


Figure 4. Microcam view of a centered Crystalens HD IOL implanted in the eye.

grooves for the primary incision, but I no longer do this, because the injector system can catch on them. I now make a straight paracentesis, and I think the evidence is fairly strong that these incisions can seal fairly well.³ I use a standard diamond knife, but I have developed a technique where I insert the blade just enough to have created a small Descemet's valve incision (stopping at 1.8 mm). I find this seals well. Like Dr. Hunkeler, I was trained in an era where we made the capsulorhexis with a cystotome, so I am more comfortable using a cystotome rather than microcapsulorhexis forceps.

I perform supracapsular phacoemulsification with some cracking and chopping. It is interesting that with the 1.8-mm Stellaris system, I am able to remove the nucleus exactly as I have previously with the 3.0-mm system on the Millennium (Bausch & Lomb) or Stellaris, so in that respect, the MICS system does not require much difference in technique. In fact, the only difference I have noticed is that the Stellaris Vision Enhancement System offers better stability and control of the anterior chamber, and that a small phaco needle makes the procedure feel easier. There are many small phaco needles available, and I believe preferences vary from surgeon to surgeon.

If I am implanting the Akreos AO, I do not enlarge my incision. Rather, I have found that there is enough elasticity in Descemet's membrane to allow me to perform wound assistance and inject the IOL into the trapezoidal wound. With the Crystalens HD (see Figure 9 for an example of Crystalens HD IOL implanted in the eye), however, I do enlarge the wound. I sim-

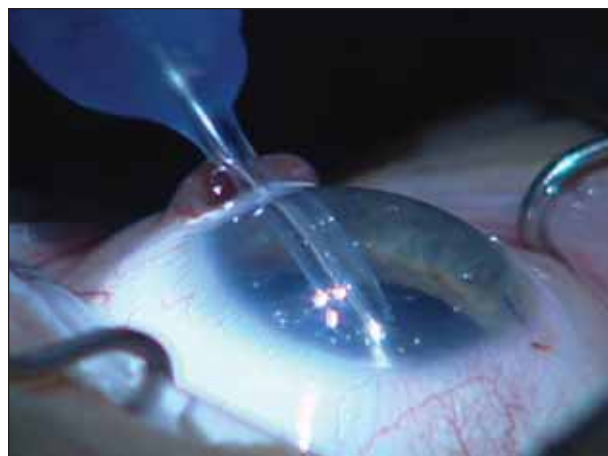

Figure 5. A sidecam view of I/A being performed behind a CrystaLens HD IOL. Live surgery by Jeffrey Whitman, MD, at the annual meeting of the ASCRS; April 3-8, 2009; San Francisco, CA.

ply use the same blade to enter straight and create a 2.5-, 2.8-, or 3.0-mm incision, depending on the knife I am using. Particularly with the Crystalens IOL, I find that hydrating the wound before removing the OVD enhances anterior chamber shallowing. I remove the OVD from behind the IOL, but instead of taking the phaco tip behind the lens, I use more of an Arshinoff rock-and-roll technique, which is to push the lens slightly off to one side, turn on the aspiration port in that direction, and push the OVD off to the other side.

“The Stellaris Vision Enhancement System offers better anterior chamber stability and control, and a small phaco needle makes the procedure feel easier.”

—Richard L. Lindstrom, MD

I hydrate the wound in 100% of my cases, and I perform a final hydration of the sideport incision with moxifloxacin (Vigamox; Alcon Laboratories, Inc.). My final step is to loosen the speculum (to soften the eye) and hydrate with 0.2 mL of moxifloxacin straight out of the bottle—approximately one half to one

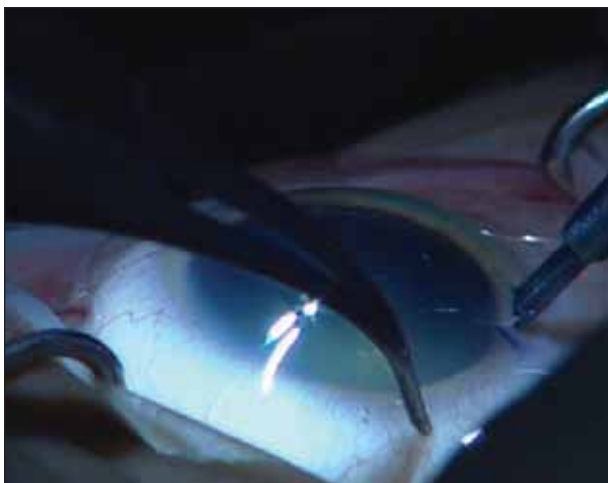

Figure 6. Sidecam view of limbal relaxing incision (LRI) blade used in a Crystalens HD IOL case. Live surgery by Jeffrey Whitman, MD, at the annual meeting of the ASCRS; April 3-8, 2009; San Francisco, CA.

third of the drug runs into the eye, and the other half or third goes into the stroma for endophthalmitis prophylaxis.

CONCLUSIONS

Dr. Lindstrom: In my experience, the learning curve for biaxial phacoemulsification was steep. I would buy new instruments every week and then end up calling colleagues to ask them why the biaxial technique was not working the way that I wanted it to. Transitioning to microcoaxial phacoemulsification with the Stellaris Vision Enhancement System, however, has been easy. Now that we have the MICS Akreos IOL (Figure 8) available, we can be on our way to improving refractive outcomes for our patients with this system.

Adjusting to the Stellaris system will not be a significant event for most cataract surgeons. The user will not have to adjust to many of the things that one normally faces when learning to use new phaco systems, such as broken capsules or cloudy corneas. In fact, he will probably experience fewer broken capsules and have clearer corneas. The higher level of control, especially when making the capsulorhexis, is apparent.

Dr. Pepose: Safety is of primary concern in any cataract surgical procedure. The Stellaris affords me the ability to use lower phaco power and to create microincisions that help stabilize the anterior chamber and significantly reduce flow in the eye.

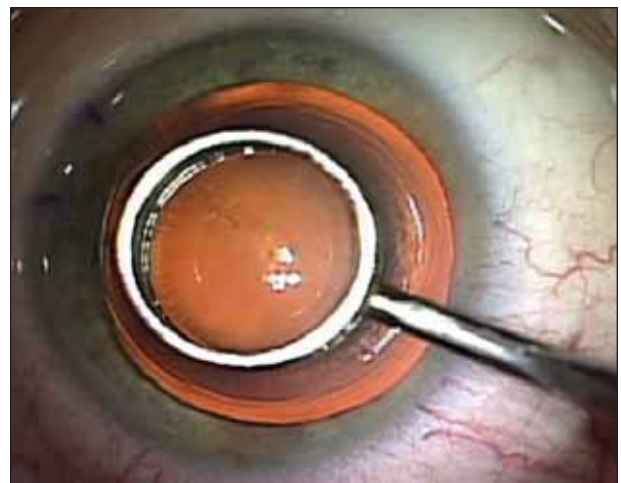


Figure 7. Microcam view of LRI marker. Live surgery by Jeffrey Whitman, MD, at the annual meeting of the ASCRS; April 3-8, 2009; San Francisco, CA.




Figure 8. The Akreos MICS IOL (A). The Akreos MICS IOL implanted and centered in the eye (B).

Additionally, the visual outcomes for my patients have been excellent with the Stellaris system and the Crystalens HD IOL. The availability of the MICS IOL will further enhance these results.

Dr. Nichamin: Not only is the transition easy, but the payoff is big with the Stellaris Vision Enhancement System, particularly because we have not lost any efficiency. This machine's fluidics are the closest I have experienced to those of vitrectomy. We all operate on

challenging eyes, such as the patient with -10.00 D of myopia and previous vitrectomy for macular hole. These cases exemplify the Stellaris' perfectly controlled environment. The smaller incisions and instrumentation makes the surgery positively elegant. ●

1. Hunkeler JD. Comparison of BSS usage in small incision and microincision cataract surgery. Paper presented at: The American Society of Cataract and Refractive Surgery; April 5, 2009; San Francisco, CA.
2. Ernest PH, Lavery KT, Kiessling LA. Relative strength of scleral corneal and clear corneal incisions constructed in cadaver eyes. *J Cataract Refract Surg*. 1994;20(6):626-629.
3. Fine IH, Hoffman RS, Packer M. Profile of clear corneal cataract incisions demonstrated by ocular coherence tomography. *J Cataract Refract Surg*. 33(1):94-97.

