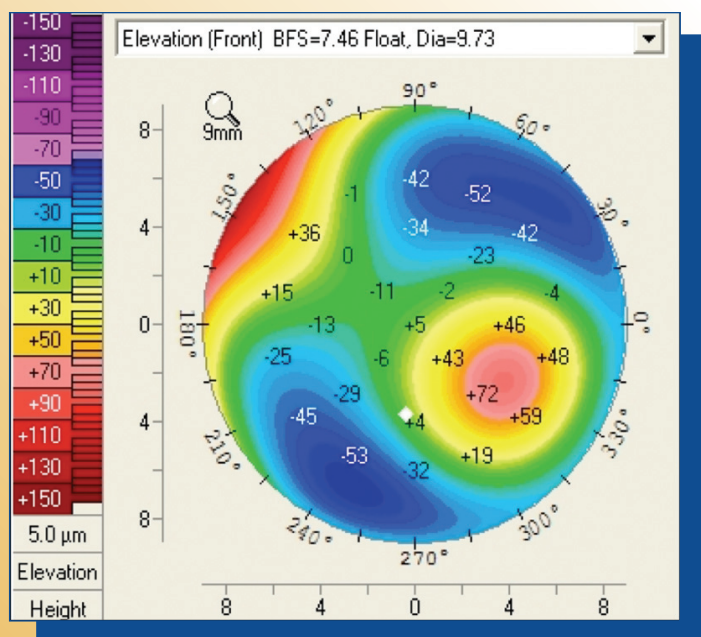


Cataract & Refractive Surgery

TODAY

The Pentacam



The gold standard in anterior segment tomography.

The Pentacam: An Impressive Technology for Anterior Segment Tomography



Ophthalmologists are under constant pressure to simultaneously improve the safety, efficiency, and quality of our outcomes. I believe the Pentacam Comprehensive Eye Scanner (Oculus Optikgeraete GmbH; Wetzlar, Germany) is one of the best devices we can invest in to achieve these goals. The Pentacam has proven its usefulness in years of clinical experience, and it continues to add value through new software packages. This monograph explains these new advancements and also reviews the many other clinical tools the Pentacam offers.

Jack Holladay, MD, MSEE, provides an overview and suggestions for using the Holladay Report for IOL calculations. Donald Nixon, MD, describes the Pentacam Nuclear Staging (PNS) software, which enables surgeons to preoperatively grade cataracts and then set their phaco parameters accordingly, thereby preventing intraoperative adjustments. This technology may add another level of customization to the premium cataract surgery channel.

Additionally, Renato Ambrosio Jr, MD, PhD, and I explain how to use the Belin/Ambrósio Display (BAD) II to screen refractive patients for ectasia.

My colleagues and I hope you will find these articles not only informative but useful for your practice.

—Michael Belin, MD



Figure 1. The Pentacam Comprehensive Eye Scanner (Oculus Optikgeraete GmbH, Wetzlar, Germany).

Contents

3 USING THE HOLLADAY REPORT IN CATARACT SURGERY

By Jack T. Holladay, MD, MSEE

5 CUSTOMIZING CATARACT SURGERY

By Donald R. Nixon, MD

7 THE BELIN/AMBRÓSIO DISPLAY (BAD) II FOR REFRACTIVE SCREENING

By Michael Belin, MD

9 ENHANCED SCREENING FOR ECTASIA

By Renato Ambrósio Jr, MD, PhD

Using the Holladay Report in Cataract Surgery

Tips for using the Holladay Report for IOL calculations.

BY JACK T. HOLLADAY, MD, MSEE



The Pentacam Comprehensive Eye Scanner (Oculus Optikgeraete GmbH, Wetzlar, Germany) offers an important advantage in anterior segment tomography versus prior slit-scanning systems such as the Orbscan topographer (Bausch + Lomb, Rochester, New York). Because the Pentacam's Scheimpflug camera rotates around a meridian point to capture and display thin "slices" of tissue, these slices have a common point, and any error caused by movement of the eye during the 1.5-second capturing process can be almost eliminated by registering the slices. Thus, the Pentacam's technology gives a very accurate picture of the anterior segment. This article describes how to use the Holladay Report (Holladay Consulting, Inc., Bellaire, Texas) on the Pentacam for accurate IOL calculations.

HOLLADAY MAPS AND TRUE CORNEAL POWER

The Holladay Report on the Pentacam includes standard topography complete with an axial power map. The tangential curvature map is slightly more sensitive regarding corneal curvature; it is really a local radius-of-curvature map, and it provides the best representation of the detail of the corneal surface. The third map gives

pachymetric information with corneal thickness, and there is also a relative pachymetry map.

Because the Pentacam measures both the front and back surfaces of the cornea, it calculates the cornea's true power, even for those that have an irregular surface. This is not possible with Placido disk imaging systems. Standard keratometers and topographers are inadequate for measuring the true power of corneas that have undergone refractive surgery because, while the surgery has changed the anterior corneal surface, the back surface radius remains unchanged. This discrepancy leaves an error in the measurement.^{1,2} However, because today's IOL calculations require keratometric values in the traditional format that keratometers and topographers have used, the Pentacam displays these values as an equivalent keratometry reading (EKR), which mirrors the traditional format. The Pentacam shows the EKR for the 1-mm to the 7-mm zone.

Figure 1 shows the EKR of a normal, healthy cornea, which reveals an increase of approximately 1.25 D in power toward the periphery. Corneas that have undergone myopic LASIK show a severe slope and increase in power toward the periphery, because the surgery has flattened their center and created a blend zone that makes the center much lower in power than it should be, while the periphery remains the same as it was preoperatively. Thus, the Pentacam helps surgeons determine the correct keratometric values to use in IOL power calculations for eyes that have undergone previous refractive surgery. With the baby boomer population aging, this demographic will continue to grow over the next several years.

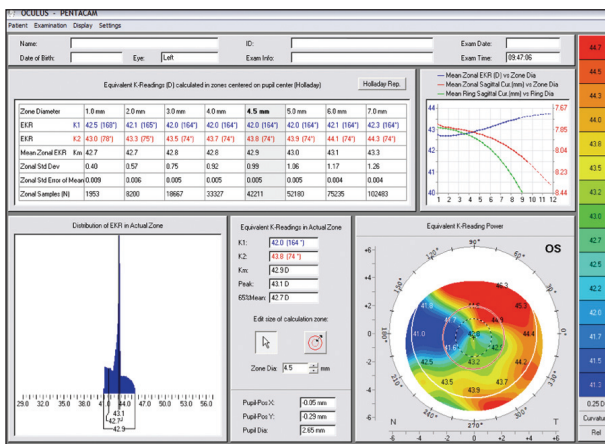


Figure 1. The EKR of a healthy cornea shows an increase of approximately 1.25 D in power toward the periphery.

TIPS FOR ACCURATE IOL CALCULATIONS

Astigmatism

A healthy cornea has a distribution of power over its surface, which is primarily a function of the amount of astigmatism. For example, an eye with 3.00 D of astigmatism will display a spread of power from approximately 41.00 to 44.00 D (Figure 2). In a LASIK eye, the spread of power (multifocality) is approximately 5.00 D, depending on the amount of surgery the eye received, how far out from surgery the eye is,

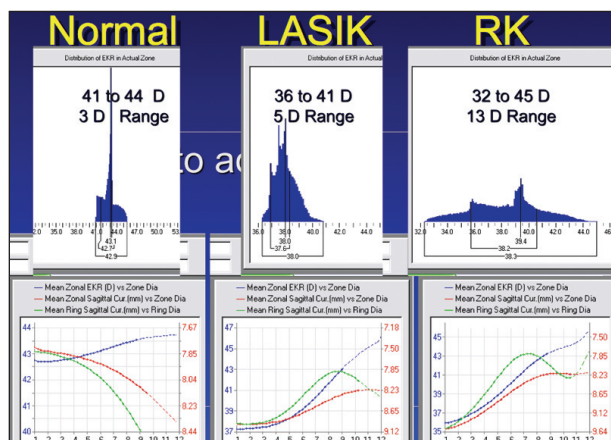


Figure 2. An eye with 3.00 D of astigmatism displays a spread of power from approximately 41.00 to 44.00 D.

and the size of its optical zone. In RK corneas, I typically see 10.00 to 13.00 D of multifocality. These are important considerations when we are trying to determine the power of the cornea within 0.25 D.

LINE OF SIGHT

It is critical to understand the line of sight when performing IOL calculations. Patients with significant multifocality, like those with keratoconus, have a bifocal cornea. When they are using distance vision, they look around the cone (through the paracentral 44.00 to 46.00 D). To view an object 10 cm in front of their eye, they will look through the cone, which will be from 55.00 to 60.00 D or higher, to use the magnification. Therefore, when you see a rapid change in the line of sight, you must examine two things. To determine the effect of this multifocality, you must first look at the pupil size. If the pupil is small, you can edge down from the recommended 4.5-mm zone to a slightly smaller zone (eg, 3 mm or less). Second, if you see a lot of multifocality, look at how flat the central 1 mm is, and then use a value that is 3 mm or less. The smaller the pupil and the greater the multifocality within the pupil, the smaller the zone that should be used from the table of EKR.

In a recent study, my colleagues and I determined that the standard deviation of the prediction error for IOL calculations was about 0.65 D for LASIK patients and about 0.94 D for RK patients. Therefore, approximately 95% of RK patients would be within ± 2.00 D. It also means that 5% of these individuals will be greater than ± 2.00 D, so we should target for slight myopia when implanting these eyes with IOLs.

READING THE PENTACAM MAPS

Healthy corneas will show no hot spots on the bottom row of the Holladay Report. Figure 3 shows the maps of an

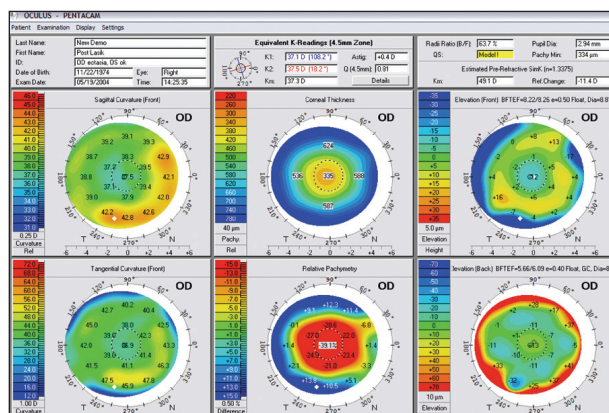


Figure 3. A post-LASIK eye shows no ectasia.

eye that has undergone corneal laser vision correction. Notice that there is an inferior yellow area on the tangential map. The cornea is 39% thinner in its center on the relative pachymetry map, and the values are negative on the posterior elevation map. Only a post-LASIK eye would be 39% thinner in its center, have no elevation or ectasia, and show K readings that are in the range of 40.00 D. A hot spot shows up on the relative pachymetry map simply because the central cornea is much thinner than it should be after the surgery. Because the posterior elevation is ≤ 5 μm in the center of the cornea, we know the eye has no ectasia. Therefore, by looking at the tangential map, the elevation map that uses the toric ellipsoid float, and the relative pachymetry map, we can quickly determine whether or not an eye is contraindicated for LASIK or PRK surgery.

SUMMARY

The Pentacam's Scheimpflug camera and analytic software take a lot of the guesswork out of ocular diagnostics and IOL calculations. The device provides exceptional detail of the anterior segment and produces reliable, user-friendly data. I feel the Pentacam is especially useful when planning surgery in eyes that have undergone previous procedures (a population that is growing as the baby boomers age) and in those suspected of certain pathologic conditions. ■

Jack T. Holladay, MD, MSEE, is a clinical professor of ophthalmology at Baylor College of Medicine in Houston, and he is Founder and Medical Director of the Holladay LASIK Institute in Bellaire, Texas. Dr. Holladay may be reached at +1 713-669-9153; holladay@docholladay.com; www.docholladay.com.

1. Huggier P, Kohnen T, La Rosa FA, Holladay JT, Koch DD. Comparison of changes in manifest refraction and corneal power following photorefractive keratectomy. *Am J Ophthalmol*. 2000;129:68-75.

2. Budak K, Khater TT, Friedman NJ, et al. Evaluation of relationships among refractive and topographic parameters. *J Cataract Refract Surg*. 1999;25:814-820.

Customizing Cataract Surgery

Enhancing power and precision with the Pentacam Nucleus Staging software.

BY DONALD R. NIXON, MD



Intraoperatively, cataract surgeons do their best to adapt the balance of phaco energy and fluidics to the grade of cataract in order to extract the nuclei with as little disturbance to the eye as possible. Phacoemulsification could be even faster and safer, however, if surgeons knew a cataract's density and what phaco parameters it would require before they entered the eye.

Scheimpflug imaging technology utilized in the Pentacam nuclear grading system (PNS) software on the Pentacam Comprehensive Eye Scanner (Oculus Optikgeraete GmbH, Wetzlar, Germany) can determine not only the density but also the volume of the nucleus prior to surgery. Physicians may then adjust their phaco parameters accordingly before entering the eye (rather than responsively once inside the eye) to increase the safety and efficiency of cataract surgery.

CLASSIFYING CATARACTS

Cataracts have variable densities, components, and volumes, which are difficult to identify within the limitations of two dimensions. The Pentacam's Scheimpflug camera offers 3D lens densitometry via the PNS software. The PNS

sampling technology allows surgeons to evaluate the individual components of the cataract in three dimensions and determine the relative density of the nucleus and epinucleus. They may then modify and set their preferred phaco settings linked to the cataract's grade. Ultimately, surgeons may be able to establish default phaco settings that they initiate at the start of surgery based on the PNS grade.

The PNS is user-friendly, reproducible, transferable, and it is based on the Pentacam's objective calibration system. After scanning an individual's cataract, the surgeon selects the Scheimpflug overlay and then picks the most centered cross-sections (Figure 1). Then, he or she clicks on the PNS nuclear grading tab, and a graph with a gradation number from zero to five will appear. This number is important, because it provides a comparison between what is visible at the slit lamp and the PNS' grading of the nucleus. The physician may then mark this number on the chart and use it in the OR for setting the phaco parameters. The result is a user-friendly nuclear grading system (Figure 2).

MATCHING NUCLEAR DENSITY AND PHACO ENERGY

Rabsilber et al sought to determine if a relationship existed between nuclear density as measured with the Pentacam's grading system and the amount of energy needed to remove a cataract using the INFINITI Vision

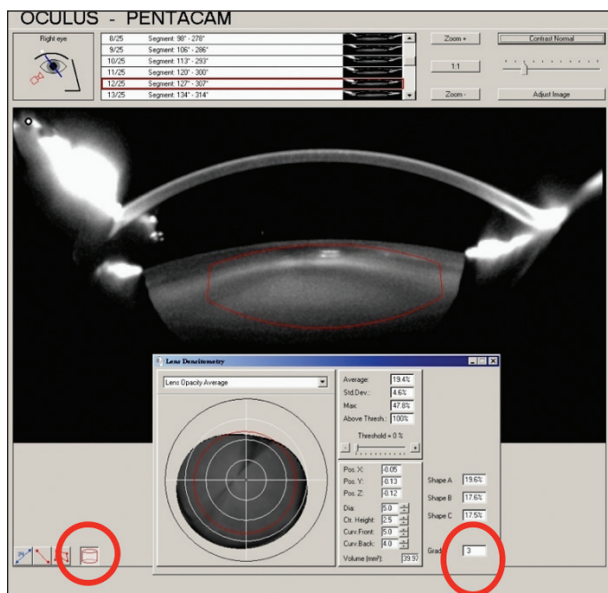


Figure 1. To use the PNS, the practitioner selects the Scheimpflug overlay, picks the most centered cross-sections, and clicks on the Pentacam nuclear grading tab.

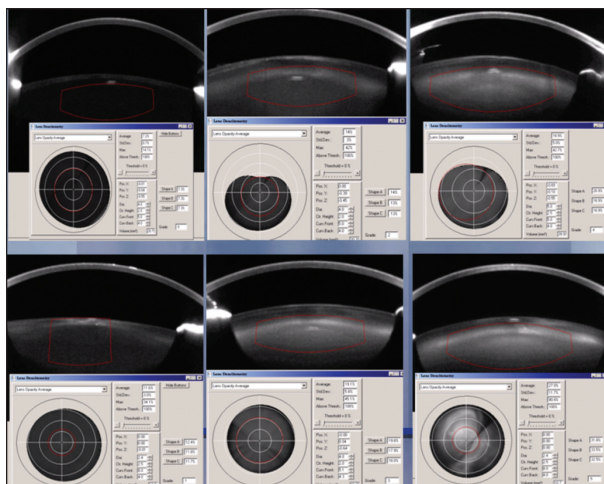


Figure 2. The full spectrum of PNS grades, from 0 to 5. Soft nuclei are graded from 0 to 1, medium are 2 to 3, and hard lenses are graded from 4 to 5.

System (Alcon Laboratories, Inc., Fort Worth, Texas).² The physicians studied 186 eyes that underwent cataract surgery by the same surgeon. They found a linear correlation between the amount of energy required to remove a cataract and its grade as measured by the PNS. Furthermore, 39% of the patients had cataracts of either grade 1 or grade 4 to 5, falling outside of the bell curve of grades 2 and 3. This supports the suggestion that a single phaco setting is not appropriate for the entire range of nuclear densities.

I conducted similar studies in 2008 and 2009 to test for a correlation between the Pentacam's grading system and the energy dispersion on two different phaco systems, the Sovereign with WhiteStar and the WhiteStar Signature (both manufactured by Abbott Medical Optics Inc., Santa Ana, California).³ The results were similar in that 37% of the patients (n = 200 consecutive eyes) fell outside of the grades 2 and 3 cataract range. I also found similar results using a Stellaris phaco system (Bausch + Lomb, Rochester, New York) (n = 50). With all three phaco machines, there was a positive linear correlation between the Pentacam's nucleus grading system and the amount of energy required to remove the cataract. Furthermore, out of 250 consecutive cases, more than 90% of the cataracts could be graded.

CLINICAL APPLICATIONS

Often, intraoperative surprises force us to readjust our phaco settings midsurgery, which delays the operation. The studies listed herein suggest that up to one-third of our patients would likely benefit from the use of different phaco settings at the beginning of surgery in the two extremes of cataract densities. Two solutions to this problem are (1) using an objective measurement to calculate the grade of the nucleus and (2) having the ability to incorporate the nuclear density into the phaco machine's power dispersion.

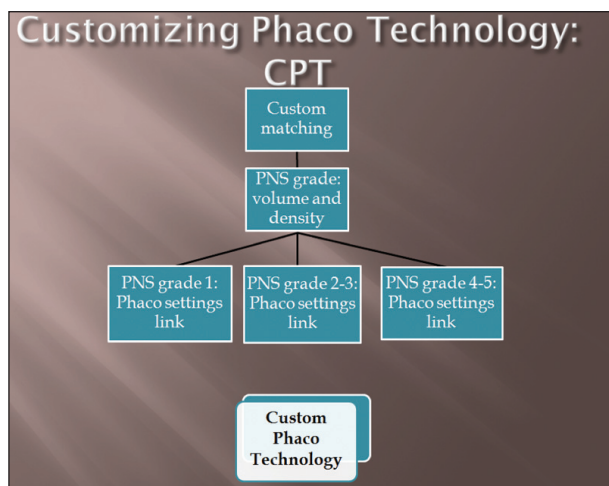


Figure 3. How surgeons may use the PNS to customize their phaco technology.

Phaco efficiency is best measured by looking at the amount of energy dispersed inside of the eye as well as the amount of balanced salt solution consumed. Additionally, we should consider how long the phaco needle is inside the eye. A study I published in the *Journal of Cataract and Refractive Surgery* sought to test the safety and efficiency of phacoemulsification when cataracts were graded preoperatively with the PNS.⁴ The study involved two groups of 200 patients each. The first group underwent surgery with one setting, 20% power and 20% duty cycle. In the second group, I adjusted the phaco parameters according to the grade of cataract. I reduced the phaco power by half for grade 1 cataracts and doubled it for grade 4 to 5 cataracts. The results showed that it is possible to link the phaco power to the grade of cataract (Figure 3) and improve overall phaco efficiency with reduction of overall power and balanced salt solution dispersed in the eye.¹ This customizing of phaco settings can (1) achieve statistically significant improvements in energy dispersion inside of the eye, (2) use less fluid during the surgical case, and (3) reduce the time the needle is in the eye.

IN THE OR

No single setting is appropriate for the entire cataract population, but using the PNS to adjust cataract settings will enhance surgical efficiency. For surgeons who already have a Pentacam and are screening their patients, I suggest keeping the cataract grading schematic posted on the front of your chart. If you already have settings to handle those three patient populations, then set the phaco parameters at the beginning of surgery, not midcase.

Ultimately, we want to maximize the efficiency of the individual phaco systems. It is imperative that we encourage phaco manufacturers to provide us with an objective, reproducible way of customizing settings so that the first screen will be for soft, medium, and hard cataracts. Then, we need the ability to adapt the phaco machine's parameters to our individual surgical preferences. Until then, we can customize phaco machines for ourselves as well by using the Pentacam and linking the PNS to our settings. In a high-volume cataract practice, the resulting improvement in efficiency may save 15 to 20 minutes per day (30 to 45 seconds per case). ■

Donald R. Nixon, MD, is senior staff ophthalmologist at Royal Victoria Hospital in Barrie, Ontario, Canada. He is a consultant for Oculus, Inc., and Abbott Medical Optics Inc. Dr. Nixon may be reached at +1 705-737-3737; trimedeyedoc@rogers.com.

1. Nixon DR. Preoperative cataract grading by Scheimpflug imaging and effect on operative fluids and phacoemulsification energy. *J Cataract Refract Surg*. 2010;36(2):242-246.

2. Rablilber TM, Hara S, Limberger JJ, et al. New 3-dimensional Scheimpflug analysis of cataract density. Poster presented at: The ASCRS/ASOA Annual Meeting; 2008; Chicago, IL.

3. Nixon DR. Custom phaco: Linkage of preoperative Pentacam grading with operative fluids and phaco energy on the Signature Phacoemulsification System. Paper presented at: The ASCRS/ASOA Annual Meeting; April 5, 2008; Chicago, IL.

4. Nixon DR. Preoperative cataract grading by Scheimpflug imaging and effect on operative fluids and phacoemulsification energy. *J Cataract Refract Surg*. 2010;36(2):242-246.

The Belin/Ambrósio Display (BAD) II for Refractive Screening

How to use the BAD II to identify patients at risk for ectasia.

BY MICHAEL BELIN, MD



The Belin/Ambrósio Enhanced Ectasia Screening II is a new software package available on the Pentacam Comprehensive Eye Scanner (Oculus Optikgeraete GmbH, Wetzlar, Germany). This software combines corneal pachymetric evaluation and elevation-based mapping in one display. This article explains how this new software assists clinicians in screening and identifying preoperative refractive surgical patients who may be susceptible to postoperative ectasia.

DISPLAYING TOPOGRAPHIC ELEVATION MAPS

When we use corneal topography to look for ectatic disease, the goal is not to fit the shape to corneal abnormalities, but to accentuate them. Renato Ambrósio Jr, MD, PhD, and I worked for a long time to choose an optimal shape for the topographic reference point that would be representative of the cornea as well as intuitive for the clinician. Although any reference surface can be used, the best surface is one that easily and understandably conveys clinically relevant information, such as astigmatism and areas of ectasia. Based on these criteria, we chose a best-fit sphere for the topographic reference

point. We currently use an 8-mm optical zone to compute the best-fit sphere, because this size blends the cornea's peripheral flattening and the central steepening to create an easy-to-visualize map in which normal corneas look normal and abnormal corneas stand out (Figure 1). The other justification for an 8-mm optical zone is that we usually limit our displays to 9 mm. We tell surgeons not to use maps with extrapolated data (either black dots or white areas, depending on the user setting). If we have a full map on the 9-mm display, then we know that the best-fit sphere data based on the central 8 mm will be based on valid data.

The Belin/Ambrósio Display (BAD) II software package features an enhanced reference surface that excludes the 3.5- to 4-mm area centered on the thinnest part of the cornea in order to eliminate the ectatic regions or "mountains" (Figure 2). Normal corneas do not have mountains, so they show very little change. The enhanced reference surface accentuates abnormal areas and converts suspicious looking areas, which were difficult to detect on previous software, to a much more obvious picture. Of course, it was equally important not to make normal corneas look abnormal, so the before and after pictures of normal eyes

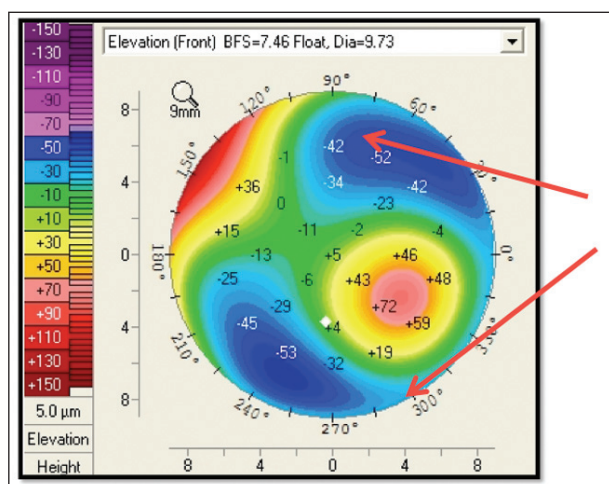


Figure 1. The regular best-fit sphere is calculated using all the corneal data within the defined optical zone.

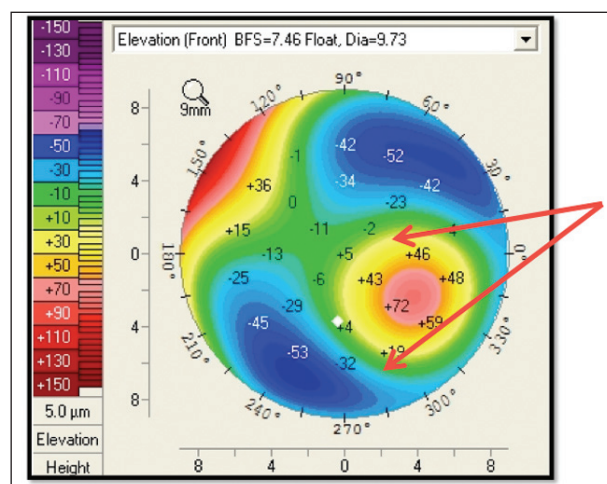


Figure 2. The enhanced reference surface only uses data outside of the cone.

will look the same. Normal eyes appear in green; the color represents the change from the standard to the enhanced image. Normal eyes undergo little change, whereas eyes with keratoconus undergo a lot of change (the mountains become higher). Combining that information with Dr. Ambrósio's pachymetric information produces the Belin/Ambrósio Enhanced Ectasia Display.

THE BELIN/AMBRÓSIO DISPLAY (BAD)

The BAD contains a series of parameters called "D" values (Table 1). Each topographic parameter is independently calculated based on the Pentacam's database for normal eyes. Then, the system reports them as a standard deviation from the mean, each independently calculated. They are color-coded to indicate when you reach certain gates. The display will turn yellow at 1.60 SD from the norm and red at 2.60 SD. A single red area does not indicate an abnormal eye; it simply indicates that you have reached a certain gate. Additionally, there is a large "D" that is not a parameter; it is a regression analysis using all of the parameters against a database of more than 1,200 eyes (Figure 3; these parameters are not equally weighted). It is a final, overall reading of the map. Although it is color-coded for easy reading, look at the numbers that signify the standard deviation.

Figure 4 shows the full BAD II display. Check that you have adequate coverage to allow a full 8-mm-diameter for the best-fit sphere computation. If there is less than 7.5 mm of coverage, the display will indicate that the data are insufficient, and you should repeat the image. The BAD's screen displays both pachymetric progression maps (CTSP and PTI). The progression index shows the average and the maximum pachymetric change, as well as maps of the cornea's thickness and its thinnest point. One of the other advantages of the BAD II is that all of the displays and scales are fixed, so it is reproducible and easy to read.

TABLE 1. BELIN/AMBRÓSIO DISPLAY D VALUES

DF	Anterior elevation change, which is the change in elevation from the standard to the enhanced image
DB	The posterior elevation on the back surface of the cornea
DP	Pachymetric progression
DT	The absolute thinnest point of the cornea
DY	Displacement of the thinnest point

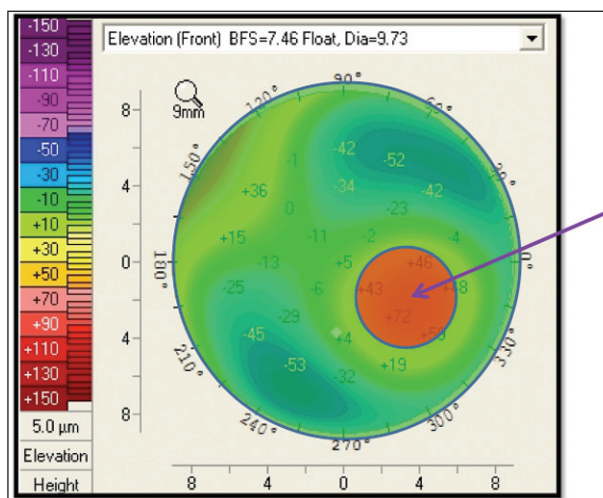


Figure 3. The actual exclusion zone (arrow) varies somewhat and is influenced by the magnitude of the astigmatism. The software does this automatically.

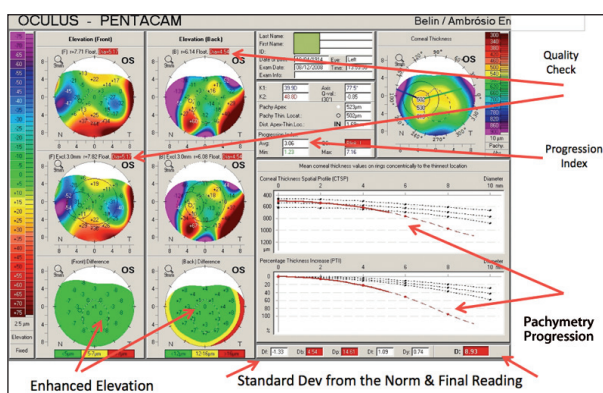


Figure 4. Features of the BAD II.

CONCLUSIONS

The BAD II is currently the only integrated display to incorporate anterior elevation, posterior elevation, and pachymetric analysis. It is based on a large database of normal and abnormal corneas and allows the practitioner to have a unified, effective refractive screening tool. The current display is based primarily on a myopic patient pool; future releases will also incorporate hyperopic data as well as international data to allow for a more customized approach. In my opinion, the BAD II further enhances one of the primary benefits of the Pentacam: the ability to identify patients that you otherwise would have missed. It may help you be comfortable performing surgery on eyes you otherwise would have turned away. ■

Michael W. Belin, MD, is Professor of Ophthalmology & Vision Science at the University of Arizona, Tucson, Arizona. He serves as a consultant to Oculus, Inc. Dr. Belin may be reached at mwbelin@aol.com.

Enhanced Screening for Ectasia

Proper tomographic evaluation of LASIK candidates is mandatory to avoiding postoperative complications such as ectasia.

BY RENATO AMBRÓSIO, JR, MD, PhD



I work in Rio de Janeiro with a group that studies corneal imaging and biomechanical analysis. This area of research is receiving a lot of attention because of its potential for improving the safety and efficacy of refractive surgery. This article describes why and how to use corneal imaging with the Pentacam Comprehensive Eye Scanner (Oculus Optikgeraete GmbH, Wetzlar, Germany) to identify the risk of ectasia among refractive candidates.

TOPOGRAPHY: NECESSARY, BUT LIMITED

To appreciate the advancements corneal imaging has achieved, we must understand its evolution over the past 25 years. The advent of corneal topography certainly improved our ability to identify early forms of ectasia.¹ For example, many patients present to our clinics with good corrected vision and normal biomicroscopy, but they may have early forms of ectasia such as mild keratoconus or pellucid marginal degeneration. In a study,² my colleagues and I found that these early forms of ectasia occur in half the ectatic patients who present as refractive candidates. The incidence of ectatic conditions among refractive candidates may vary from 1% to 6%.²⁻⁴

Figure 1 illustrates an interesting situation. The right eye has a distance BCVA of 20/20-2 ($-2.75 = -1.25 \times 27^\circ$); a normal, clear cornea at the slit lamp, and a central corneal thickness (CCT) of 511 μm as measured on ultrasound. The axial curvature from Placido disk-based topography provides enough sensitivity for detecting mild keratoconus (also commonly referred to as *forme fruste keratoconus*). Interestingly, the left eye of this patient had a distance BCVA of 20/15 ($-1.5 = -1.00 \times 20^\circ$), a normal biomicroscopic corneal exam, and CCT of 545 μm . Although the topography in this eye is unremarkably normal, considering the right eye's presentation, the left eye shows a good example of true forme fruste keratoconus. My colleagues and I refer to such an eye as "highly susceptible to ectasia." In this example, topography provided greater sensitivity to detect mild keratoconus in the left eye. However, the normal picture for the left eye illustrates that we need to enhance the sensitivity for detecting the risk of ectasia among refractive candidates. For example, imagine that this patient presented after a car accident in which the right eye was lost. The refractive

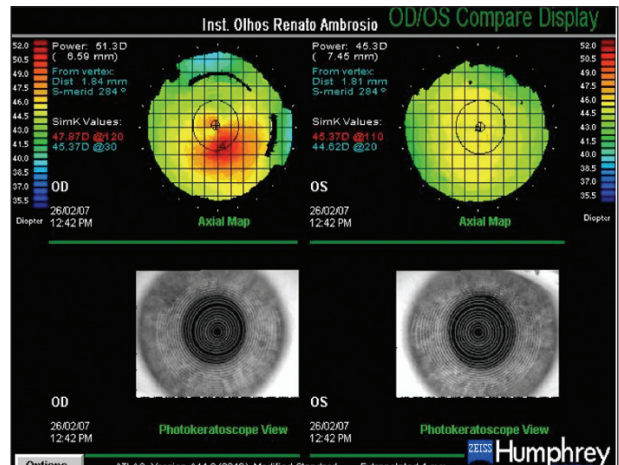


Figure 1. Placido (axial): absolute scale.

surgeon who would screen this patient only with topography and CCT would qualify this low myope as a perfect candidate for LASIK. Yet, the individual would be at high risk for post-LASIK ectasia progression.

The most important risk factor for post-LASIK ectasia is a preoperative ectatic condition. The presence of a mild form of ectasia with no topographical abnormality may be an indication of "unexplained" ectasia after LASIK. This is why we need to go beyond topography when screening for ectasia.

TOPOGRAPHY MAY LEAD TO FALSE POSITIVES

Some corneal conditions may lead to topographic presentations similar to keratoconus that do not represent true forms of ectasia. For example, corneal surface irregularities, such as those found in eyes that have anterior basement membrane dystrophy, produce a similar topographic pattern as keratoconus. In addition, other situations may be associated with progressive inferior steepening after refractive corneal procedures. Corneal haze and epithelial ingrowth, for example, do not represent true ectasia.

CORNEAL TOMOGRAPHY: DIFFERENCES BETWEEN TOPOGRAPHY AND INTERPRETATION GUIDELINES

The next step in the evolution of corneal imaging was tomography of the cornea and anterior segment. We need to use nomenclature properly to distinguish between

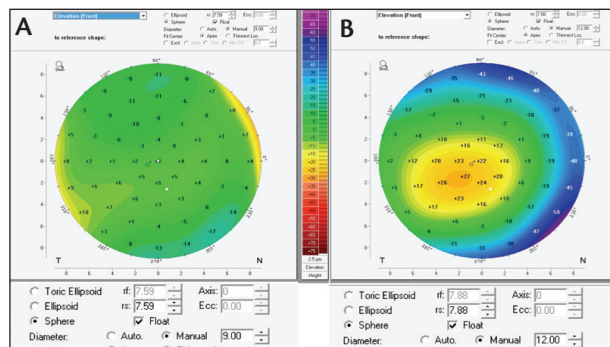


Figure 2. Reference-based subtraction maps: impact of the diameter of a 9-mm zone (A) and a 12-mm zone (B) on the same cornea.

topographic surface evaluation and three-dimensional (3D) architecture tomography for corneal imaging. The term *tomography* has already been used by speakers such as Jack Holladay, MD, of Bellaire, Texas. In a recent editorial in the *Journal of Refractive Surgery*, colleagues and I emphasized that the term should be used to describe 3D corneal tomography.⁵

Properly interpreting 3D tomographic imaging can be challenging. The Pentacam displays front and back corneal surfaces in maps that subtract the elevation from a reference surface. In order for practitioners to make accurate clinical decisions based on tomographic data, it is critical that they understand the impact of different geometric bodies and corneal areas when calculating the best-fit reference. The corneal zone that the practitioner chooses for calculating the best-fit surface will dramatically change the elevation maps. Large zones will include more of the corneal periphery, which is flatter in normal corneas and will lead to a higher radius for the best-fit reference. Thus, the system will allocate greater sensitivity to protruded areas that do not represent ectasia. Figure 2 shows the front elevation map for a normal cornea using the best-fit sphere with a 9-mm zone (A) and a 12-mm zone (B). Note that the larger zone shows an island pattern of protrusion that is not visible in the 9-mm best-fit sphere. Therefore, it is important to fix the best-fit sphere calculation zone to establish threshold values. I recommend using an 8-mm zone because it provides a clean map with no extrapolated data for most eyes. The reference body used may also vary between sphere, ellipsoid, and toric ellipsoid. Best-fit sphere elevation maps enable the surgeon to evaluate corneal toricity, and best-fit toric ellipsoid maps facilitate the identification of irregular astigmatism and other higher-order aberrations because it fits the regular astigmatic (second-order) terms.

A study my colleagues and I presented at the 2010 ASCRS meeting in Boston compared the sensitivity and specificity of the Pentacam's elevation maps referenced to the 8-mm best-fit sphere and best-fit toric ellipsoid to

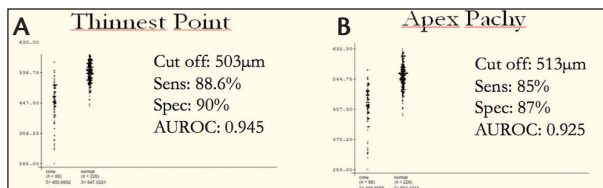


Figure 3. Pachymetry for a keratoconic (A) and normal eye (B).

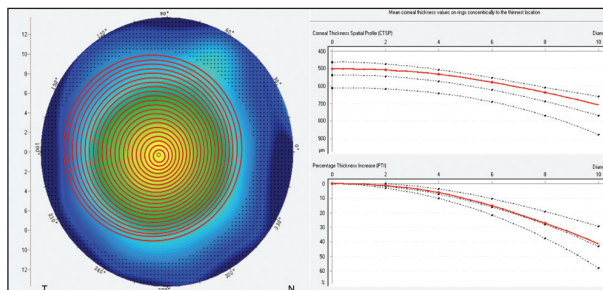


Figure 4. Tomographic pachymetric evaluation.

detect keratoconus. We analyzed 98 normal corneas from 49 patients and 56 keratoconic corneas from 28 patients. We considered the elevation at the thinnest point for the front and back surfaces (best-fit sphere and best-fit toric ellipsoid) as the best single-value parameters. The cut-off values for back-surface elevation at the thinnest point were 19 µm for the best-fit sphere and 12 µm for the best-fit toric ellipsoid. Interestingly, the receiver operating characteristic (ROC) curves found excellent and similar performances for the best-fit sphere and best-fit toric ellipsoid for diagnosing keratoconus.

Another innovative approach for mapping corneal elevation is the Pentacam's Belin enhanced elevation software. This software first calculates the standard best-fit sphere for an 8-mm corneal zone, and then it calculates a second "enhanced" best-fit sphere for the same 8-mm zone that excludes the 3.5-mm-diameter central zone at the thinnest point. It then generates a subtraction map

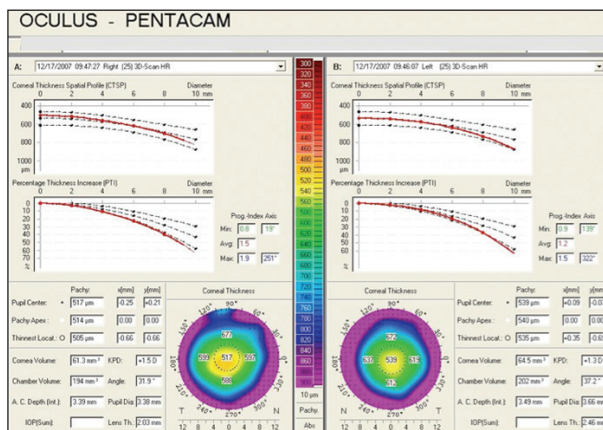


Figure 5. The pachymetric maps for the same case in Figure 1 show an abnormal thickness profile in both eyes.

from the standard and enhanced calculations that will exaggerate any differences (protrusions). More than 12 μm of difference for the front elevation and 20 μm difference for the back elevation are considered abnormal.

TOMOGRAPHIC THICKNESS EVALUATION

Corneal thickness maps are important for identifying the cornea's true thinnest point. An ROC curve is statistically better than the central thickness (apex) value for diagnosing ectasia in keratoconic versus normal eyes. However, the single pachymetric values have a huge overlap between keratoconic and normal eyes (Figure 3A and B).

Nevertheless, the tomographic evaluation of the thickness map should go beyond single-point metrics. The Pentacam displays the pachymetric distribution as graphs of the corneal thickness spatial profile (CTSP) and percentage thickness increase (PTI). It records the thinnest point as the starting value, then it displays the average of the thinnest values on imaginary concentric rings accordingly to the diameter in the CTSP. The PTI display shows the same data as the CTSP, but it considers the percentage of increase of the average at each ring from the thinnest value. Both the CTSP and PTI graphs are displayed in conjunction with the mean and two standard deviations from normality (Figure 4).

The rationale for the CTSP and PTI graphs is that normal corneas are thinner in the center and gradually thicken toward the periphery.⁶ Ectasia is defined as a progressive thinning disease. The pachymetric distribution in ectasia has a more abrupt thickening in the periphery, which is consistent with thinning, the hallmark of ectasia.

The software calculates a pachymetric progression index for each point over the entire map based on the normal thickness distribution. The pachymetric progression is averaged for each meridian 360°. The average of all meridians (PPI-Avg), as well as the minimum and maximum (PPI-Min and PPI-Max) are displayed. My colleagues and I introduced the concept of *relational thickness*, which is the thinnest point divided by the pachymetric progression index. The Ambrósio Relational Thickness (ART) is calculated for the average and maximal progression indices (ART-Ave and ART-Max). The ART metrics represent the best metrics for detecting eyes at risk for ectasia. The best cut-offs for the diagnosis of keratoconus, based on a study involving 226 normal corneas and 88 keratoconic corneas, are 339 and 427 μm for ART-Max and ART-Ave, respectively.

It is important to note that when screening for the risk of ectasia, clinicians are not just looking for keratoconus or related conditions. In fact, the sensitivity level should be raised to detect susceptibility to ectasia. I believe every cornea may develop ectasia if there is enough stimuli, such as aggressive eye rubbing or a deep enough cut. For detecting ectasia susceptibility, we use 391 μm and 512 μm for ART-Max and ART-Ave, respectively, based on our study examining

contralateral eyes with normal topography versus those with significantly asymmetric keratoconus (not unilateral).

Figure 5 shows the pachymetric map along with the CTSP and PTI graphs of the same case as in Figure 1. Note the abnormal distribution in both eyes despite the relatively normal CCT. The ART-Max was 266 μm OD and 357 μm OS. These indices will be incorporated into the Belin/Ambrósio Enhanced Ectasia Display (BAD) II in the near future.

THE BAD II

The BAD II combines the enhanced elevation maps for the front and back surfaces of the cornea and the CTSP and PTI graphs. The software computes the deviation from normal indices for the enhanced front and back elevations (df and db), for the thinnest value (dt), for the pachymetric distribution (dp), and for the deviation of the thinnest point at the vertical axis (dy). From these data, it generates a final deviation value (D) that combines all parameters.

At the recent AAO meeting in Chicago, my colleagues and I presented a poster on a study of 25 patients who had keratoconus in one eye based on topography and normal topography in the contralateral eye. Although some of the contralateral eyes showed a little bit of irregularity, these patients were classified in the Magellan Corneal Navigator (Nidek Technologies; Padua, Italy) topographic artificial intelligence system as not being suspected of having keratoconus. Using the combined approach, in 24 out of 25 eyes, we were able to combine the corneal thickness, elevation, and other information based on the tomographic data to identify corneal abnormalities. Such cases, along with other case studies of post-LASIK ectasia,⁷ provide evidence that tomography offers enhanced sensitivity for identifying a risk of ectasia among refractive candidates. In my opinion, proper tomographic evaluation such as the one performed by the Pentacam should be considered as part of routine preoperative screening for all refractive candidates. ■

Renato Ambrósio Jr, MD, PhD, is clinical director of cornea and refractive surgery at the Instituto de Olhos Renato Ambrosio, Visare Personal Laser and Refracta-RIO. He is also scientific coordinator of the Rio de Janeiro Corneal Tomography and Biomechanics Study Group. He is a consultant for Oculus Optikgeräte GmbH. Dr. Ambrosio may be reached at 55 21 22745694; renatoambrosiojr@terra.com.br.

1. Maeda N, Klyce SD, Tano Y. Detection and classification of mild irregular astigmatism in patients with good visual acuity. *Surv Ophthalmol*. 1998;43(1):53-58.
2. Ambrosio R Jr, Klyce SD, Wilson SE. Corneal topographic and pachymetric screening of keratoconic patients. *J Refract Surg*. 2003;19(1):24-29.
3. Nesburn AB, Bahri S, Salz J, Rabinowitz YS, Maguen E, Hofbauer J, et al. Keratoconus detected by videokeratography in candidates for photorefractive keratectomy. *J Refract Surg*. 1995;11(3):194-201.
4. Wilson SE, Klyce SD. Screening for corneal topographic abnormalities before refractive surgery. *Ophthalmology*. 1994;101(1):147-152.
5. Ambrosio R Jr, Belin MW. Imaging of the cornea: topography vs tomography. *J Refract Surg*. 2010;26(11):847-849.
6. Ambrosio R Jr, Alonso RS, Luz A, Coca Velarde LG. Corneal-thickness spatial profile and corneal-volume distribution: tomographic indices to detect keratoconus. *J Cataract Refract Surg*. 2006;32(11):1851-1859.
7. Ambrosio R Jr, Dawson DG, Salomao M, et al. Corneal ectasia after LASIK despite low preoperative risk: tomographic and biomechanical findings in the unoperated, stable, fellow eye. *J Refract Surg*. 2010;26(11):906-911.

Cataract & Refractive Surgery
TODAY

Cataract & Refractive Surgery
EUROPE TODAY