

Cataract & Refractive Surgery **TODAY**

February 2008

The Pentacam: Offering a Clearer View

Densitometry software for cataracts

Topography for premium-channel cataract surgery

Screening for refractive surgery

Power calculations after keratorefractive surgery

Detection of forme fruste keratoconus

The Pentacam: Offering a Clearer View

The Pentacam Comprehensive Eye Scanner (Oculus, Inc., Lynnwood, WA) continues to expand the field of ophthalmic diagnostics with new features and software, such as densitometry for cataracts. This and other key information on the Pentacam is presented in the following articles, which summarize presentations that were given at two breakfast symposia on November 10th and 11th in New Orleans.

CONTENTS




3 SURGICAL REFINEMENT

The role of corneal topography in premium-channel cataract surgery.
BY JOHN A. VUKICH, MD



5 PENTACAM-GUIDED PHACOEMULSIFICATION

A new approach to “custom” cataract surgery.
BY DONALD R. NIXON, MD



7 TRUE VALUE IN DIAGNOSTICS

Applications of the Pentacam in screening candidates for refractive surgery.
BY MARK G. SPEAKER, MD, PhD



9 ADVANCING DIAGNOSTICS

Interesting applications of the Pentacam in the anterior segment practice.
BY DAVID R. HARDTEN, MD



11 DETECTING FORME FRUSTE KERATOCONUS WITH THE PENTACAM

High-tech strategies simplify detection and treatment.
BY JACK T. HOLLADAY, MD, MSEE



13 IOL POWER CALCULATIONS AFTER KERATOREFRACTIVE SURGERY

How the Pentacam simplifies an increasingly important task.
BY WARREN E. HILL, MD

20/30, and 2.00 D of cylinder. The Pentacam showed an abnormal inferior/superior ratio, indicating an atypical anterior segment. This patient was contraindicated for a corneal relaxing incision and a multifocal IOL. Fortunately, the Pentacam provides insights for treating patients with limited options. Its algorithms help us tease out a patient's risk for surgical complications.

I decided to treat him with a toric IOL. Postoperatively, his manifest refraction was plano, and his UCVA was 20/25. Considering that his cornea was irregular preoperatively, this patient feels that his vision is much improved, and he is extremely happy. Although he requested a multifocal IOL when he presented, the Pentacam allowed me to select a more appropriate treatment for this patient.

IOL CALCULATION AND SELECTION WITH THE PENTACAM

We now have access to a variety of IOLs, including toric and aspheric aberration-adjusted lenses. In order to choose the best lenses for patients and provide optimal outcomes, we need to understand what causes corneal aberrations and how to prevent and treat them, if necessary. Positive and negative spherical aberration are derived from corneal topography. Therefore, cataract surgeons who plan to implant IOLs need to know the location of the corneal aberration they are trying to correct and which of the four available IOLs will produce the best result. I believe that intelligently selecting an IOL based on preexisting phenomena and other considerations amounts to customized cataract surgery. The Pentacam provides all of this information in its Holladay Report and elevation and pachymetry maps. In fact, the system's next software upgrade will match a patient's root mean square on the Zernike display and give the specific information.

Choosing an IOL for an eye that previously underwent LASIK, PRK, or RK requires special consideration. We cannot rely on standard keratometry to calculate the proper IOL power, because our corneal model assumes that the positive anterior surface and negative posterior surface occurs in a fixed ratio. Because LASIK alters this relationship, we cannot plug keratometric measurements taken from post-LASIK corneas into standard IOL formulas without performing additional recalculations. Increasingly, we require a tool to accurately predict a patient's net corneal power (effective corneal power), which will allow us to predict an implant's power.

I use the Holladay Report available on the Pentacam to more accurately calculate IOL power for my postrefractive patients. I think the algorithm is outstanding, and it has changed the way we approach these IOL calculations. The report calculates the cornea's front-to-back ratio power using true power calculations before generating the net

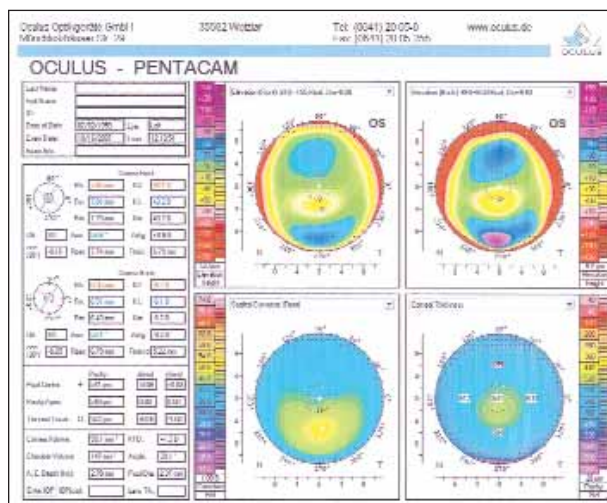


Figure 2. The abnormal inferior/superior ratio seen here disqualified this cataract patient for a multifocal IOL and a corneal relaxing incision.

effective power based on the anterior and posterior surfaces. These K readings reflect the true optical power of the cornea following refractive surgery and can be used with any of the standard IOL power calculation formulas.

The Holladay Report also calculates relative pachymetry. Jack Holladay, MD, MSEE, studied a database of over 1,000 normal corneas and determined their average thickness. The Pentacam calculates the degree to which the cornea being measured deviates from this average over the entire surface of the cornea. Deviations of 10 µm or greater in any area tend to indicate an abnormality and help identify suspicious patterns that can indicate a potential problem.

CONCLUSIONS

All corneal and cataract surgery must be performed on stable corneas, and I believe that the Pentacam is an important tool to help surgeons identify corneal abnormalities and thus improve our services. The system's ease of use and reliability have increased my efficiency. I no longer spend hours looking at topography; the Pentacam's printouts allow me to make a surgical decision quickly and accurately. It has improved my outcomes by helping me identify the best surgical treatments for my patients. ■

John A. Vukich, MD, is Surgical Director of the Davis Duehr Dean Center for Refractive Surgery in Madison, Wisconsin. He is not a paid consultant for Oculus, Inc., and acknowledges no financial interest in the company or its products. Dr. Vukich may be reached at (608) 282-2000; javukich@hotmail.com.

1. Grabow HB, Martin RG. STAAR AA-4203 one-piece plate-haptic silicone IOL. In: Martin RG, Gills JP, Sanders DR, eds. *Foldable Intraocular Lens*. Thorofare, NJ: Slack, Inc.; 1993: 237-250.

Pentacam-Guided Phacoemulsification

A new approach to “custom” cataract surgery.

BY DONALD R. NIXON, MD

Having performed more than 25,000 cataract procedures, I am now trying to approach surgery from a more objective point of view. How can I grade a cataract objectively? If such evaluation is possible, are there ways to apply this information to my next case? Can I improve my outcomes on the basis of such information?

I applied my idea of cataract quantification to the Pentacam Comprehensive Eye Scanner (Oculus, Inc., Lynnwood, WA) to see if the system could generate an objective, reproducible method of grading cataracts compared to the existing Lens Opacification Classification System (LOCS) III. Then, I prospectively sought to establish whether a relationship existed between an individual cataract’s grade and the amount of energy required to remove it. Ultimately, I am using this information to develop a customized approach to cataract surgery.

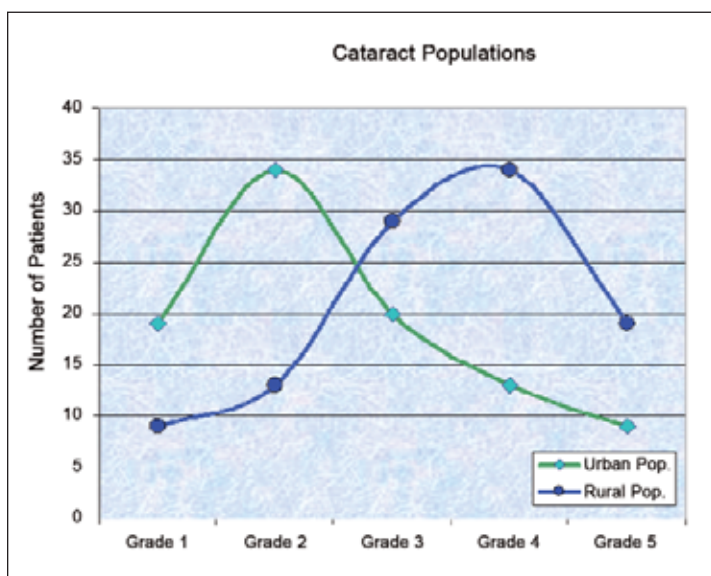


Figure 1. Comparative population cataract grades for rural versus urban settings.

“The densitometry software provides an objective record of a cataract’s grade prior to surgery.”

NEW DENSITOMETRY SOFTWARE

In cooperation with Oculus, Inc., I developed a new densitometry software template (patent-pending) for the Pentacam that evaluates volume and optical density in three dimensions and can assess the nucleus in more than 91% of cataracts through a dilated pupil. The software will use the data from a full scan to reconstruct the lens, which it then evaluates using a series of 3-D shapes to assess the mean optical density of the sampled volumes.

The software next compares the density against a developed nomogram and assigns the cataract a grade from zero to five. The Pentacam will produce an image of the lens, similar to an optical CAT scan reconstruction, that may be viewed from either the anterior or posterior surfaces of the human lens. Human cadaver and animal studies have shown that if a system can provide data from both the anterior and posterior surfaces of the lens as well as internal parameters, it can calculate the lens’ total volume.^{1,2} Thus, the densitometry software provides an objective record of a cataract’s grade prior to surgery.

PUTTING THE INFORMATION TO USE

Once the densitometry software determines an individual cataract’s grade, the information may be used in various applications. For example, the surgeon may objectively and reproducibly compare his own phaco settings, technique,

energy used, and other parameters involved in removing each grade of cataract. He may also evaluate how changing his technique or settings affects phaco efficiency on the same cataract grade. Most importantly, the surgeon can share his customized settings and techniques, based on this objective and valid assessment of cataract grades, with colleagues around the world.

“Comparison studies with the LOCS III system have shown that the Pentacam better predicts the amount of phaco energy needed to remove various grades of cataract.”

The Pentacam's new densitometry software is not without limitations. A poorly dilated pupil interferes with the device's sampling technology, and so eyes with pseudoexfoliation, trauma, and intraoperative floppy iris syndrome, for example, are problematic. Also, white cataracts block the system's ability to sample the central nucleus. Nevertheless, comparison studies with the LOCS III system have shown that the Pentacam better predicts the amount of phaco energy needed to remove various grades of cataract.³

PHACODYNAMICS: CUSTOMIZING THE SURGICAL APPROACH

The ability to preoperatively assess a sampling of the density and volume of the nuclear component of the cataract allows for customization in cataract surgery. Such information may influence how a surgeon programs his phaco settings, which needle he selects, and his choice of phaco energy dispersion. Many cataract surgeons routinely use standard phaco settings with which they are comfortable for the majority of their patient populations. However, they should critically evaluate their surgical approaches and find the outliers in their patient populations in order to customize their phaco settings and improve their surgical efficiency. The Pentacam is an excellent tool for such analysis.

I have a fairly high-volume surgical practice in two urban areas as well as a rural patient population. My Pentacam screenings revealed that my rural population has a tendency toward higher-grade cataracts, and my urban population trends toward the lower grades (Figure 1). Obviously, I need different phaco settings to effectively treat these two populations. I use the Sovereign phaco system with WhiteStar ICE software (Advanced Medical Optics, Inc., Santa Ana, CA). I conducted a study on my urban patients to determine if preoperatively adjusting my phaco settings based on the Pentacam's grading would generate any improvement in my phaco efficiency parameters. In the first group of

patients, I used my standard settings but recorded the Pentacam's grade for each case as well as the effective phaco time, total phaco time, and amount of balanced salt solution (BSS; Alcon Laboratories, Inc., Fort Worth, TX) I used. I extracted from my data set the grade 2 and 3 cataracts, which responded best to my standard phaco settings, and I only considered grades 1, 4, and 5. In the second group, I preoperatively adjusted my phaco settings for the grades 1, 4, and 5. In the grade 1 cataracts, I reduced the Sovereign's duty cycle by 20% and halved the maximum amount of power. For my cataracts of grades 4 and 5, I increased the duty cycle by 20% and doubled the maximum power. Then, I compared these two populations to see if preoperatively adjusting the phaco parameters had any effect on my overall phaco efficiency.

For the grade 1 cataracts, I found a statistically significant advantage in effective phaco time and total phaco time when I adjusted my settings based on the Pentacam-generated cataract grades. With the grades 4 and 5 cataracts, all my parameters were statistically lower in the Pentacam-adjusted phaco settings.

CONCLUSIONS

The Pentacam's new densitometry software simplifies cataract grading into a single, elegant test that provides a reliable, reproducible way of sampling the volume and density of the nuclear cataract and objectively classifying it from grade zero up to a grade 5. Information sharing can provide help in evaluating new phaco systems as well as changes in surgical technique. It can also standardize cataract grading for the sharing of information between colleagues in the future. I have also found that the densitometry software is an excellent teaching tool for cataract patients preoperatively, and it may have applications in the future as part of the staging information for insurance purposes. Most exciting of all the applications is that having this grading knowledge preoperatively allows surgeons to preprogram their phaco systems to handle the specific density of cataract efficiently. ■

Donald R. Nixon, MD, is Senior Staff Ophthalmologist at Royal Victoria Hospital in Barrie, Ontario, Canada. He is a paid consultant for Oculus, Inc., and Advanced Medical Optics, Inc., but acknowledged no financial interest in the products or companies mentioned herein. Dr. Nixon may be reached at (705) 737-3737; trimedeyedoc@rogers.com.

1. Vilupuru AS, Glasser A. Optical and biometric relationships of the isolated pig and crystalline lens. *Ophthalmol Physiol.* 2001;21:4:296-311.
2. Glasser A, Campbell MCW. Biometric, optical and physical changes in the isolated human crystalline lens with age in relation to presbyopia. *Vision Res.* 1999;39:11:1991-2015.
3. Nixon DR. Redefining cataract grading to enhance transferability and reproducibility for future phaco programming. Paper presented at: The Annual Meeting of the ASCRS; April 30, 2007; San Diego, CA.

True Value in Diagnostics

Applications of the Pentacam in screening candidates for refractive surgery.

BY MARK G. SPEAKER, MD, PhD

As a refractive surgeon, I spend a lot of time looking at corneal topography. More than 10 years ago, I tested the Orbscan corneal topographer (Bausch & Lomb, Rochester, NY). It was a rather slow and cumbersome instrument that seemed of academic interest but did not offer much practical value. When I saw my first case of ectasia several years ago, I realized that corneal topography would be a critical technology for ophthalmologists and that I had better learn more about it. I came to consider the Orbscan an important diagnostic advance. A few years ago, however, I started using the Pentacam Comprehensive Eye Scanner (Oculus, Inc., Lynnwood, WA) and found it to be a vastly superior instrument. This article describes this device's importance in my practice.

COMPARING SYSTEMS

The goal of preoperative screening is to exclude high-risk eyes, but assigning risk to individual eyes is not as simple as we would like it to be. Despite the hundreds of hours I have spent staring at topographical maps, I am still often confused by Placido-disk topography. This technique is often indeterminate and can result in false-

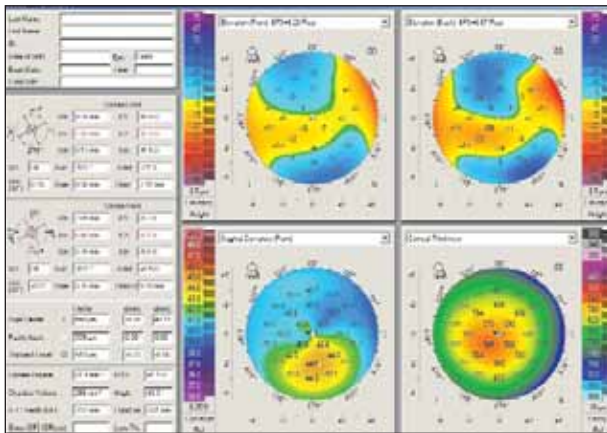


Figure 1. In this patient with an asymmetric bowtie, the Pentacam shows abnormal values for the anterior and posterior apices and displacement of the apices inferotemporally and of the thinnest point on the pachymetry map. This patient can be clearly identified as a keratoconus suspect.

TABLE 1. COMPARISON OF ANTERIOR AND POSTERIOR APEX ELEVATION WITH THE ORBSCAN II AND PENTACAM IN NORMAL EYES

	Anterior	Posterior
Pentacam	6.5 (+/-4.6)	9.8 (+/-4.9)
Orbscan	10.3 (+/-3.5)	30.3 (+/-10.0)

positive or false-negative diagnoses of keratoconus.

The Pentacam's maps are easy to read and display key data that I routinely review. I first check the magnitude of the elevation of the anterior and posterior apices above the best-fit sphere and look for any displacement (especially if the apices are displaced in the same direction). Second, I note the value of the thinnest spot on pachymetry to get an idea of the data's validity. Next, I evaluate corneal curvature and elevation: Ideally, the curvature map should be symmetric, and the elevation map should have nicely centered anterior and posterior apices with minimal elevation above the best-fit sphere. Also, the pachymetric profile should be centered.

In order to compare the data from the Pentacam to that obtained with the Orbscan II and the Humphrey Atlas Placido topographer, my colleagues and I performed a study in which we examined 46 parameters in symmetric and asymmetric corneas.¹ In this study, one of the first issues we examined was mean elevation values using the Pentacam and the Orbscan II. For the anterior apex in symmetric eyes, the mean elevation above the best-fit sphere was 6.5 μm on the Pentacam and 10.3 μm on the Orbscan II. On the posterior surface, the mean was 9.8 μm on the Pentacam and 30.3 μm on the Orbscan II (Table 1).

DIAGNOSTIC EXAMPLES

The following cases illustrate the Pentacam's value in various clinical presentations.

Figure 1 shows a patient with an asymmetric curvature

(Courtesy of Michael Belin, MD.)

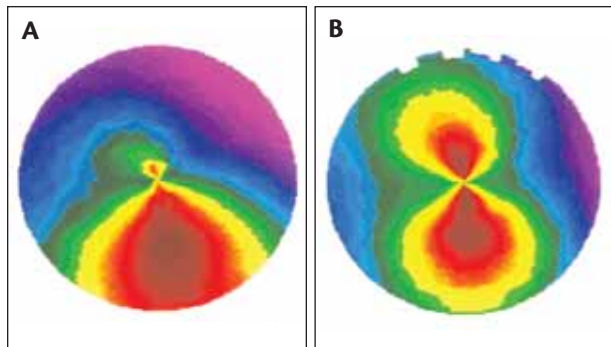


Figure 2. Simply altering the fixation on a Placido map can dramatically alter its appearance, as shown in this comparison of images from the same eye looking up (A) and straight ahead (B).

map. The Pentacam identified an abnormal amount of elevation at the anterior and posterior apex above the best-fit sphere, with an inferotemporal displacement of those apices in concert. The thinnest point on the pachymetric map was also displaced. Thus, the Pentacam clearly identified this patient as a keratoconus suspect. The Pentacam's data are reproducible, so we can follow the progress of these affected eyes over time, provide the information to the patients, and ascertain when and what type of treatment is appropriate.

Not every asymmetric cornea is a keratoconus suspect, however. Michael Belin, MD, taught me that Placido-disk topography is quite sensitive to the eye's alignment with the instrument. By simply asking the patient to look upward, you can convert a normal symmetric bowtie into an abnormal-looking asymmetric one. If the anterior apex of the cornea is not centered on the geometric center of the cornea, it can create a significant amount of asymmetry. This clinical concept is illustrated nicely by

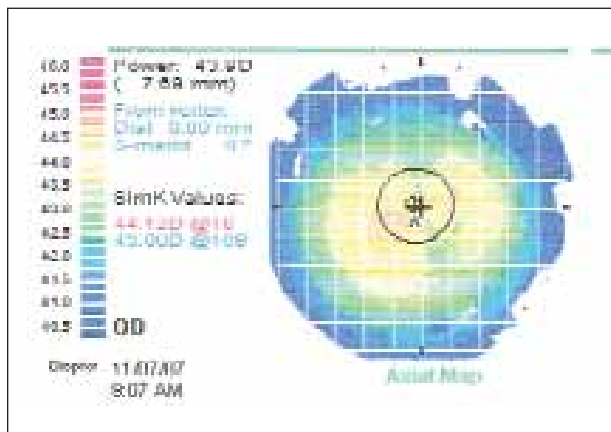


Figure 4. Some corneas that appear normal on Placido maps, such as the one above, are clearly abnormal when analyzed with the Pentacam.

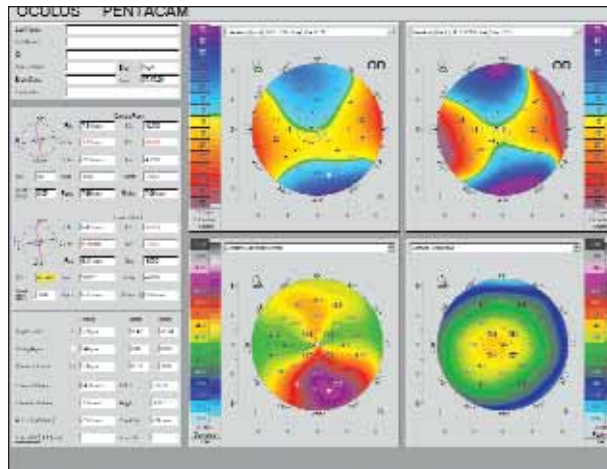


Figure 3. This is a normal cornea with a displaced anterior apex and a false-positive reading on Placido mapping.

the curvature map shown in Figure 2. The surface of the cornea is significantly asymmetric, but its posterior surface looks normal on the Pentacam map (Figure 3), suggesting that this patient does not have keratoconus. Placido-disk topography commonly shows asymmetry when there is a displaced anterior apex. When the posterior surface is normal, with a displaced anterior apex, we see an asymmetric Placido map, which may be normal. So, a displaced anterior apex can produce a false-positive Placido-disk reading on a normal cornea. Approximately 10% of my patients who present for refractive surgery screening generate an asymmetric Placido-disk map with a normal posterior elevation on the Pentacam images, a configuration we describe as a *displaced anterior apex*.

I have seen excellent results of LASIK on eyes with a displaced anterior apex and a normal posterior surface

(Continued on page 10)

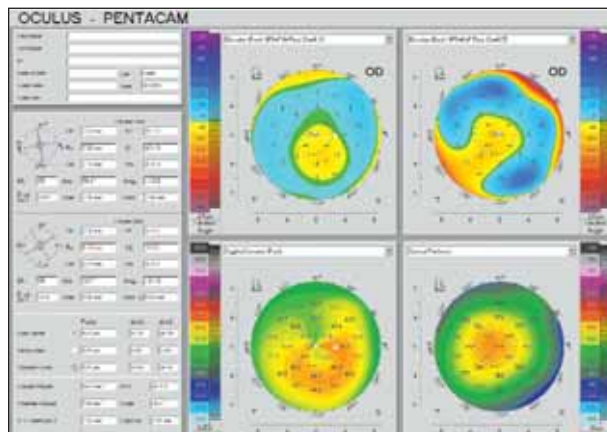


Figure 5. The Pentacam identified the false-negative reading on Placido topography (Figure 4) and thus may have spared this patient from ectasia.

Advancing Diagnostics

Interesting applications of the Pentacam in the anterior segment practice.

BY DAVID R. HARDTEN, MD

Users of the Pentacam Comprehensive Eye Scanner (Oculus, Inc., Lynnwood, WA) know that the device's value is not only in corneal topographical and tomographical elevation and thickness data, but also in its imaging of the anterior segment. In my practice, 95% of my use of the device is for detecting keratoconus in refractive surgery screening or in postsurgical eyes that need a secondary enhancement with laser vision correction. I also use the Pentacam to fit contact lenses on eyes that have significant amounts of irregular astigmatism, as well as to plan treatments with Intacs (Addition Technology, Inc., Des Plaines, IL) and conductive keratoplasty (CK; Refractive, Inc., Irvine, CA) for eyes with ectasia or keratoconus (Figure 1). The Pentacam allows me to view the apex of the elevated corneal area where I center the Intacs segment and around which I apply the conductive keratoplasty treatment for the combined procedure.

APPLICATIONS

Corneal

When evaluating eyes with slight abnormalities for corneal refractive surgery, I use a few favorite Pentacam maps. My primary four are the most familiar to surgeons: anterior elevation; posterior elevation; sagittal curvature; and corneal thickness.

As I stated previously, I also frequently use the keratoconus detection program for patients who are scheduled for or have undergone refractive or cataract surgery and for eyes that will have penetrating or lamellar keratoplasty for keratoconus in the case of a corneal transplant. The device's information helps me decide what size optical zone I need to replace, and it also shows any peripheral thinning of the cornea so I can decide how large to make the graft.

When treating corneal ectasia after LASIK, the Pentacam's curvature, elevation, and thickness maps reveal the cornea's postoperative status. Also, the device's Scheimpflug images let me evaluate my placement of Intacs segments so that I may critique my surgical technique and, if necessary, modify it in the future.

I have also used the Pentacam to image and document corneal pathology. Figure 2 shows a patient with Fuchs' corneal dystrophy that developed 10 years after he

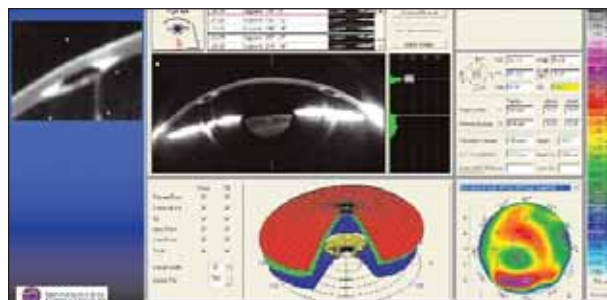


Figure 1. This figure shows a Pentacam image of an eye after it underwent treatment with Intacs and conductive keratoplasty. It shows a relative deep placement of the Intacs segment but significant improvement in irregular astigmatism compared with before the treatment for ectasia.

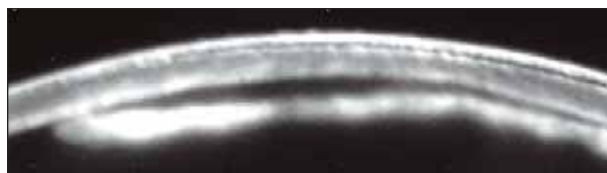


Figure 2. The Pentacam revealed a Descemet's stripping endothelial keratoplasty lenticule that detached 10 years after LASIK surgery. Note the amount of fluid present in the LASIK interface.

underwent LASIK. His Descemet's stripping endothelial keratoplasty lenticule detached, which this image shows. In addition, the Pentacam imaged a significant amount of fluid in the LASIK interface, which is still a potential space for fluid collection, even 10 years later.

Lenticular

The Pentacam helps me to plan phakic IOL implantations by imaging and calculating the dimensions of the anterior chamber for adequate space. The only caveat is that it cannot penetrate into the sulcus for exact planning of the implantation of a Visian Implantable Collamer Lens (STAAR Surgical Company, Monrovia, CA), although the imaging of the white-to-white is often useful.

For the postoperative analysis of IOL implantations, I take

a Pentacam picture at approximately 1 month to evaluate the vault between the implant and the crystalline lens. The device's measuring tools easily calculate and document the vault, which I can then track over time. I also perform specular microscopy in these patients at their annual postoperative visits. I can also use the Pentacam to image the wound, and I use the device's lens densitometry function to see the opacity of the lens, which can also be followed progressively. Thus, the Pentacam is an excellent educational tool for the patient.

Refractive

For refractive surgery, the Pentacam will image LASIK flap interfaces and measure the thickness of the flap. Another interesting application is following patients with corneal haze after PRK to track their responses to drug therapy and monitor their corneal density on an objective scale.

CONCLUSION

Although I mostly use the Pentacam for routine screenings, it also has some interesting and useful applications for challenging cases. I appreciate the device's imaging, measuring, and documentary capabilities for the anterior segment that have allowed me to treat certain patients more accurately than I could have otherwise. I consider the Pentacam a very versatile instrument, and my staff and I are certainly glad we added it to our practice. ■

David R. Hardten, MD, is Director of Refractive Surgery for Minnesota Eye Consultants in Minneapolis. He has received speaking honoraria from Oculus, Inc., but acknowledged no direct financial interest in the products or companies mentioned herein. Dr. Hardten may be reached at (612) 813-3632; drhardten@mneyc.com.

(Continued from page 8)

for a number of years, and I have not seen any cases of ectasia. Therefore, the Pentacam has been extremely valuable in allowing me to accurately counsel patients about their risk of ectasia and their refractive surgical options.

Possibly even more important are the false-negatives seen on Placido-disk topography. The Placido-disk image in Figure 4 shows an eye with apparently normal topography. Images from the same eye obtained with the Pentacam, however, show abnormalities in its posterior and anterior corneal surfaces that are consistent with pellucid-marginal degeneration (Figure 5). In this example, the Pentacam identified a risk factor for ectasia that was not detected by Placido-disk topography, and thus may have helped prevent a poor outcome.

I have also seen Orbscan images that show a dramatic elevation of the posterior apex over the best-fit sphere and severe thinning on the pachymetric map, suggesting keratoconus. On the corresponding Pentacam map, however, the eye will look totally normal. Thus, a slight increase in the density of the corneal stroma may lead to a false-positive diagnosis on the Orbscan, which is a typical difference between the Orbscan and the Pentacam when evaluating a patient after LASIK. The flap interface will often give a fictitious result on the posterior elevation and pachymetric maps on the Orbscan. The only instrument of value in evaluating a patient for a refractive enhancement, in my opinion, is the Pentacam.

I now use the Pentacam instead of the Orbscan to screen all refractive surgical candidates. I have found that the Orbscan is not as reliable as the Pentacam, because the accuracy of its images depends on precise ocular fixation and the skill of the technician performing the evaluation. Furthermore, the accuracy of the Orbscan's posterior-elevation pachymetric maps is very dependent on focus and will produce different readings from technician to technician and exam to exam. Other factors that influence the utility of the Orbscan include its sensitivity to opacities and reflections created by the interface between the corneal flap and stroma in post-LASIK eyes.

CONCLUSION

I think the Pentacam offers the state of the art in topographic screening and provides more information about corneal anatomy than Placido-disk topography. The device gives me a lot more confidence when I evaluate refractive surgery candidates. I see many patients who have received conflicting advice from other surgeons about whether they are candidates for LASIK. The Pentacam allows me to identify conditions that could cause postoperative problems and decide whether a patient is a good candidate for refractive surgery. It certainly reduces the number of false readings and gives accurate data in post-LASIK eyes, and I think it will allow even more detailed analysis in the future. ■

Mark G. Speaker, MD, PhD, is the founder of Laser & Corneal Associates, PC, in New York City, Medical Director at the Manhattan TLC Laser Eye Centers, a member of the cornea service at the New York Eye and Ear Infirmary, and Clinical Associate Professor at the New York Medical College. He acknowledged no financial interest in the companies or products mentioned herein. Dr. Speaker may be reached at (212) 832-2020; lasikspeak@aol.com.

1. Nilforoushan MR, Speaker MG. Univariate and multivariate regression analysis of 46 parameters. *J Cataract Refract Surg.* In press.

Detecting Forme Fruste Keratoconus With the Pentacam

High-tech strategies simplify detection and treatment.

BY JACK T. HOLLADAY, MD, MSEE

It is important for refractive surgeons to detect forme fruste keratoconus and other corneal thinning disorders before performing refractive surgery. Scheimpflug photography with the Pentacam Comprehensive Eye Scanner (Oculus, Inc., Lynnwood, WA) provides information about the front and back surfaces of the cornea, thus aiding the surgeon in preoperative screening.

THE HOLLADAY REPORT

Demographic and K Readings

Most clinicians do not have time to sit at an instrument and view several corneal maps and then make a surgical determination. They need the information to be provided in a simple and comprehensive report that can be placed in the patient's chart and is available during

"Physicians need information to be provided in a simple and comprehensive report that can be placed in the patient's chart and is available during the examination."

the examination. This is the intent of the Holladay Report (Figure 1). In the upper left-hand corner of this report is the patient's demographic information. The top center box shows the equivalent K readings that may be used for IOL calculations. In the upper right-hand corner is where the program calculates what the Ks would have been before refractive surgery. (In this image, because there has been no surgery, the values are almost identical to the equivalent K reading values.)

Standard Maps

Below the first row of demographic and quantitative information on the Holladay Report are two more rows of maps (six maps total). The middle row includes the sagittal front, pachymetric, and front-elevation maps. The sagittal front or axial power map is the most common map used in topography and represents the axial power of the cornea at all points. The pachymetric map shows the thickness of the cornea at all points and is especially helpful for viewing its central thickness. The front-elevation map shows the height of the anterior cornea relative to the best-fit toric ellipsoid. Although a sphere may be used for the fit, a toric ellipsoid is nearer the shape of the normal cornea (Figure 2). Because the cornea is normally ellipsoid, if a best-fit sphere is used, the center is always above the

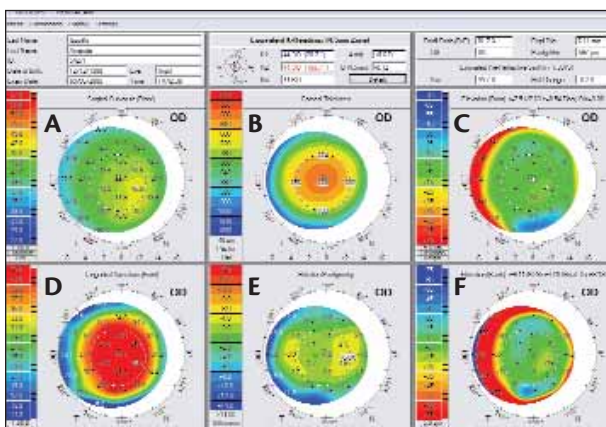


Figure 1. The Holladay Report on the Pentacam presents maps for sagittal front curvature (A), pachymetry (B), and front elevation (C), tangential curvature (D), relative pachymetry (E), and back elevation (F).

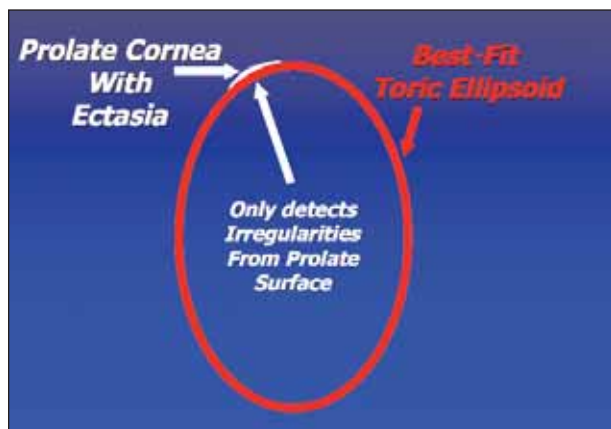

Figure 2. A toric ellipsoid more closely resembles the shape of the naturally prolate cornea.

sphere and the periphery is always below (Figure 3). This makes it difficult to get normal values, because the calculations depend on the shape of the cornea. Also, if astigmatism is present, a “band” will appear across the center of the map, because the steeper meridian will be below the reference sphere and the flatter meridian above it. When a toric ellipsoid is used, the band disappears, because the reference surface is toric, and the central vaulting above the reference surface has less variation.

Tangential, Relative Pachymetry, and Back-Elevation Maps

The bottom row of maps includes the tangential (local radius of curvature), relative pachymetry, and back elevation maps. The tangential map is the most sensitive for determining the geometry of the cornea. Unlike the sagittal map, the tangential map curvatures are relative to the surface, not the axial center of the surface. A simple analogy would be to consider the Earth a sphere with a radius of 8,000 miles and a hemisphere on the surface that is 6 miles high (Mount Everest). On the sagittal map, the Earth’s radius would measure 8,000 miles, and the hemisphere’s radius would be 8,006 miles—because the center of the Earth is the reference, almost no difference is detected. On the tangential map, the Earth would measure 8,000 miles, but the hemisphere’s radius would be 6 miles—a large difference. Thus, the tangential map is always the most sensitive measure of the geometric surface. Because of this property, the tangential map shows the exact location of the “nipple” of the cone. Notice that the steepest part is at 330°, approximately 2 mm from the center (the white diamond in Figure 1D).

The relative pachymetry map gives the thickness of the cornea at a given point relative to the normal thickness at that point as a percentage. A normal map would be 0% at all points. Although the cornea becomes thicker toward the

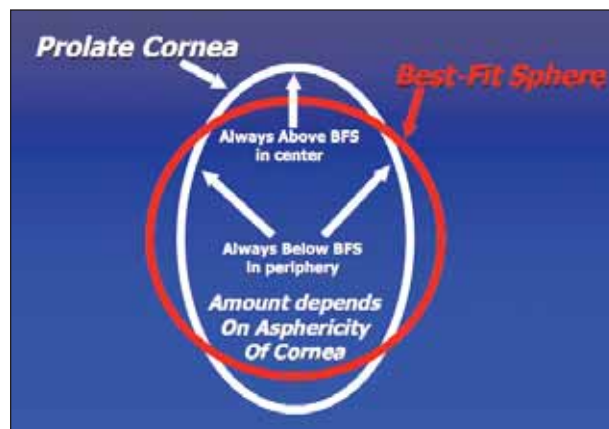


Figure 3. Fitting a prolate cornea to a best-fit sphere will generate inaccurate values.

periphery, if this thickness increases normally, the map still appears green (0.0%). Figure 1E shows that the relative thinnest point is -5.0% thinner than it should be at that point. Note that this point is at the same location as the nipple on the tangential map.

Finally, the back-elevation map, which uses the best-fit toric ellipsoid, has a yellow spot that is +16 μm above the reference toric ellipsoid (Figure 1F), also at the same “hot spot” as on the tangential and relative pachymetry maps. Note that this point does not show up on the normal pachymetry map, because the cornea is still thinnest centrally, so the relative thickness is obscured. It is of interest to note that the epithelium of the corneal anterior surface thins over the nipple, reducing the sensitivity of the diagnosis from the front surface alone. In this example, the anterior surface is only 10 μm above the reference surface (not 16 μm , as on the back-elevation map). Normal epithelial cells are 6 to 8 μm thick, and there are usually six to eight layers of epithelial cells. The epithelium is approximately one epithelial cell thinner over the nipple.

SUMMARY

When the hot spot on the tangential map, relative pachymetry map, and back-elevation map using the toric ellipsoid are all at the same point, the diagnosis of forme fruste keratoconus is confirmed. In my experience, relative pachymetry measurements that exceed -3.0% are significant, as are elevations of more than 15 μm above the toric ellipsoid on the back-elevation map. ■

Jack T. Holladay, MD, MSEE, is Clinical Professor of Ophthalmology at Baylor College of Medicine in Houston, and is Founder and Medical Director of the Holladay LASIK Institute in Bellaire, Texas. He is a paid consultant to Oculus, Inc. Dr. Holladay may be reached by fax at (713) 669-9153;

IOL Power Calculations After Keratorefractive Surgery

How the Pentacam simplifies an increasingly important task.

BY WARREN E. HILL, MD

Performing IOL power calculations for eyes with prior RK and LASIK is becoming more and more of a problem for ophthalmologists; in fact, it is something of a tsunami that will wash over many practices. In the US alone, millions of patients have undergone RK and LASIK since these procedures were first introduced, and a significant portion of these individuals are nearing the age at which cataract surgery is becoming commonplace. More than ever, ophthalmologists now need a workable strategy for easily and successfully handling IOL power calculations following all forms of keratorefractive surgery.

A TWO-PART PROCESS

Calculating the IOL power for the postkeratorefractive surgery patient is a two-part process. First, we must estimate

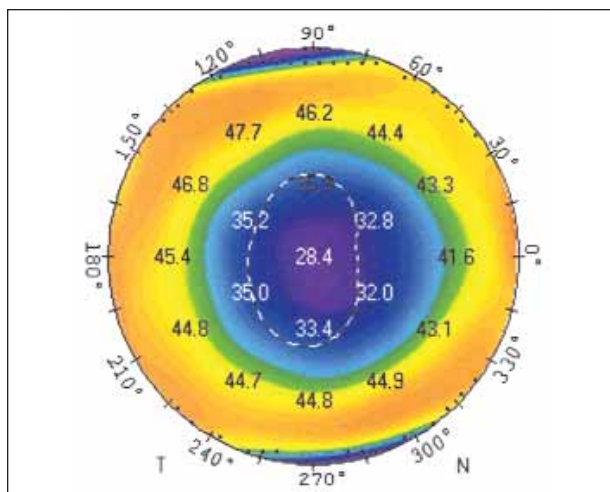


Figure 1. This image is of a Pentacam front refractive power map of an eye with prior eight-incision RK.

“Calculating the IOL power for the postkeratorefractive surgery patient is a two-part process.”

the central corneal power as best as we can. The problem with using standard equipment is that keratometers are completely blind to the central cornea, measuring instead an intermediate zone and extrapolating a central value. Standard topographers, which generate simulated K readings, suffer from a similar problem in that they do not see the very center of the cornea and are, in essence, a topographer trying to be a keratometer. For patients who have undergone prior myopic keratorefractive procedures, this problem may lead to a significant overestimation of the central corneal power. This is especially true for eyes that have undergone prior RK.

For example, if the device measures a power of 34.00 D, but the very center of the cornea is 28.00 D, we may get an unpleasant hyperopic surprise postoperatively. Although some topographers try to average the power of the central cornea, they are still blind to this area, which happens to be the flattest point in RK eyes as well as for eyes that have undergone myopic LASIK.

The benefit of using a Scheimpflug camera is that it rotates around the center of the cornea, successfully capturing a measurement of that area so it is included in the power measurement. This is why the Pentacam Comprehensive Eye Scanner (Oculus, Inc., Lynnwood, WA) is such an important advance in corneal mapping technology.

Second, the artifact of a very flat or very steep cornea's

central power can lead standard third-generation, two-variable formulas to incorrectly estimate the effective lens position when carrying out the IOL power calculation. This is because several popular two-variable formulas, such as SRK/T, in part tie the effective lens position to the central corneal power. If a central corneal power of 34.00 D is entered into one of these formulas, it may incorrectly assume that the anterior segment is very shallow and call for less IOL power than is actually required. This is a second and often overlooked cause of unanticipated postoperative hyperopia following myopic keratorefractive surgery.

The problem can be overcome by performing a “double-K” method of calculation, as is done by the Holladay 2 formula (Holladay Consulting, Inc., Bellaire, TX), or by performing a double-K method correction to two-variable formulas as outlined in the literature.^{1,2}

IOL calculations after refractive surgery must take both of these aspects into consideration: (1) the correct estimation of central corneal power and (2) have some methodology for removing the artifact of a very flat or very steep central corneal power from the effective lens position part of the IOL power calculation.

READING THE DATA

Eyes With No History or Previous RK

Another notable feature of the Pentacam is its ability to give basic information about eyes for which there are no available records. Most surgeons at some time have encountered a patient who underwent previous refractive surgery but for various reasons cannot provide his records. The Pentacam allows us to have a very good idea as to whether the patient had myopic or hyperopic LASIK or RK, simply by noting some important differences in the numbers.

The ratio between the posterior and anterior corneal radii of a normal, unoperated eye is approximately 82.5%. Eyes that have undergone RK typically have a very flat central cornea, and the ratio between the posterior and anterior portions of the cornea is very high, typically above 90% (Figure 1). This is the signature of an eye with prior RK.

For measuring eyes with prior RK, the Pentacam uses a 5-mm equivalent K reading. However, one caveat is that RK corneas are often highly multifocal, so even the Pentacam’s measurement can be imprecise. The multifocal nature of these corneas can lead to wide variability in the estimation of central corneal power. On a typical front-surface-power map, an RK cornea may show an 8.00 D range of power across a 2-mm area.

In 2007, Jack Holladay, MD, and I conducted a study in which we measured post-RK eyes using the Pentacam. This research showed a fairly good correlation between the equivalent K reading for a 5-mm zone and the back-

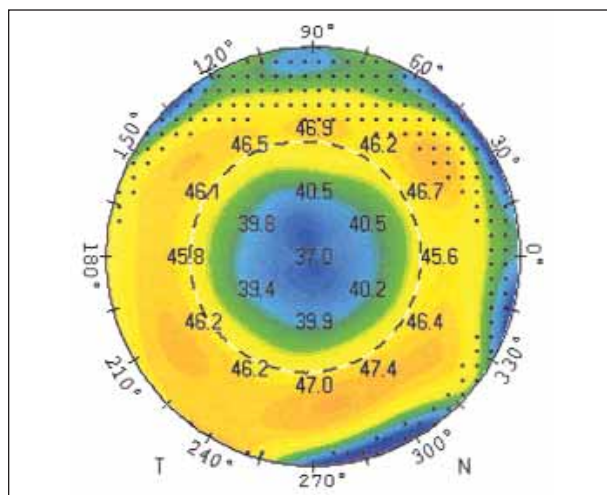


Figure 2. This image shows a Pentacam front refractive power map of an eye with prior myopic LASIK.

calculated central corneal power using the Holladay 2 formula. As would be expected, the correlation was not as tight as we saw for the post-LASIK eye, due to the highly multifocal nature of these post-RK eyes.

In performing IOL power calculations for eyes that have previously undergone RK, it is helpful to keep in mind that very often, RK is the gift that keeps on giving. By this statement, we mean that some degree of hyperopic drift may continue through a patient’s lifetime. It is a very common story that many patients who had a good initial refractive outcome have since shifted toward significant hyperopia. Because this effect may continue throughout their lives, it is generally wise to err on the myopic side when doing a post-RK calculation. This strategy is a good idea for two reasons: (1) hyperopic errors are more common than myopic errors and (2) as the years pass, these patients are more likely to have their refraction shift toward more favorable vision, rather than away from what they want. Instead of plano, I prefer to target -0.50 to -1.00 D for the post-RK patient, so that 5 years following their surgery they are not hyperopic.

Rule of Twos

When performing cataract surgery on patients who have had prior RK, expect some degree of hyperopia during the first postoperative week. In fact, I like to see approximately +1.00 D of hyperopia for an eye with eight incisions in the immediate postoperative period, especially if there is a small optical zone. If an unstable refractive outcome worries you, use what we call the *rule of twos*—two refractions on two consecutive visits, approximately 2 months after surgery—before making plans for a lens exchange or secondary piggyback implantation. This gives

the cornea enough time to shift back to its presurgical configuration.

Myopic LASIK

In contrast to the RK eye, eyes that have undergone prior myopic LASIK or PRK are somewhat steeper in the central cornea and have a lower-than-normal ratio between the posterior and anterior cornea, typically less than 70% (Figure 2). So, if the Pentacam shows a flat central cornea and a low ratio, then the eye has undergone myopic LASIK or PRK.

In estimating the central corneal power for the eye that has undergone prior myopic LASIK or PRK, the equivalent K reading for the 4.5-mm zone will often give a good estimation of the central corneal power. However, depending on the type of ablation, sometimes a smaller equivalent K reading may work better.

Hyperopic LASIK

The hallmark of hyperopic LASIK is, of course, a steep central corneal power as well as an increased ratio between the posterior and anterior corneal radii (Figure 3). It does not increase as much as with RK, but it increases nonetheless. This effect would seem counterintuitive, because one procedure is myopic incisional and the other is hyperopic ablative, but they both have the same effect on the measured ratios. So, if you are unsure whether an eye has undergone hyperopic or myopic LASIK, look at the central corneal power and the ratio between the posterior and anterior corneal radii as a place from which to begin.

CALCULATIONS

The next critical step is performing the IOL power calculation. In our practice, we use the Holladay IOL Consultant Software and Holladay 2 formula (both by Holladay

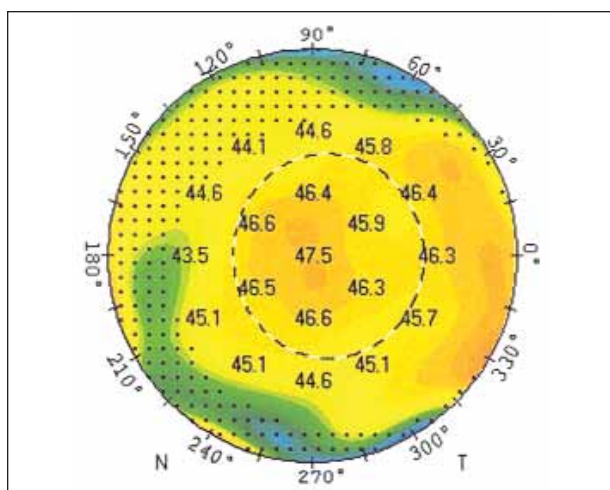


Figure 3. This image is of a Pentacam front refractive power map of an eye with prior hyperopic LASIK.

Consulting, Inc.), which was the first formula to incorporate a double-K method. Check the box on the preoperative data screen that says “previous RK, ALK, LASIK” to remove the artifact of the iatrogenically altered central corneal power. Then, input the Surgeon-Entered Value for the central corneal power.

“In the Pentacam, we now have another useful tool in performing IOL power calculations for the postkeratorefractive eye.”

Some surgeons have found it helpful to compare several IOL power calculation methodologies side by side. Doing this work by hand used to be quite cumbersome and time consuming and was frequently prone to errors. But, thanks to the generosity of luminaries in the field such as Jack Holladay, MD; Wolfgang Haigis, PhD; Douglas Koch, MD; and Li Wang, MD, PhD, a free online postkeratorefractive calculator is now available that allows for the input of data from several different instruments, including the Pentacam. This tool is very helpful and saves a tremendous amount of time. You may view the calculator online at <http://www.iol.ascrs.org>.

SUMMARY

Remember that IOL power calculations following all forms of keratorefractive surgery are a two-part process. First, we must estimate the central corneal power. Depending on the degree of multifocality of the cornea, this estimation can be easy or very challenging. Next, the IOL power must be calculated employing some form of a “double-K” method to remove the artifact of an iatrogenically changed central corneal power. The Holladay 2 formula is becoming the standard for this type of calculation, but other methods may also be employed using more common third-generation, two-variable formulas. In the Pentacam, we now have another useful tool in performing IOL power calculations for the postkeratorefractive eye. ■

Warren E. Hill, MD, is Medical Director of East Valley Ophthalmology in Mesa, Arizona. He is a consultant for Oculus, Inc., but acknowledged no direct financial interest in the company or its products. Dr. Hill may be reached at (480) 981-6130; hill@doctor-hill.com.

1. Aramberri J. Intraocular lens power calculation after corneal refractive surgery: Double K method. *J Cataract Refract Surg.* 2003;29:2063–2068.
2. Koch D, Wang I. Calculating IOL power in eyes that have had refractive surgery. *J Cataract Refract Surg.* 2003 29:11:2039-2042.

