

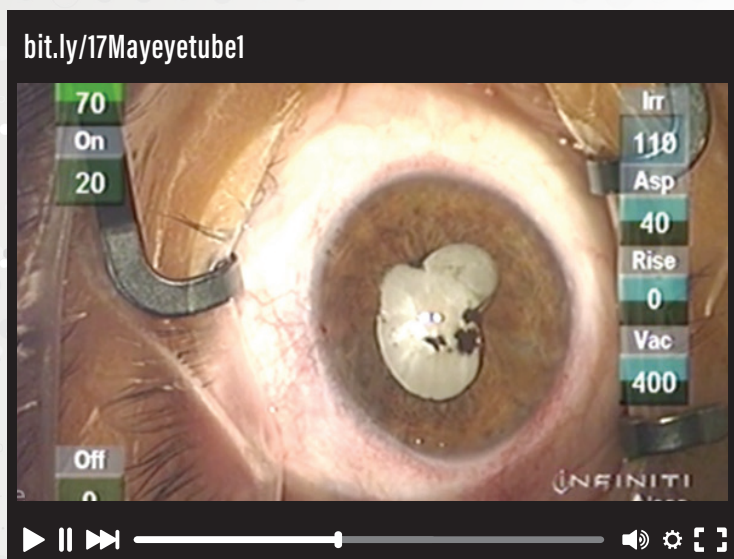


This Month on **eyetube**SM

www.eyetube.net

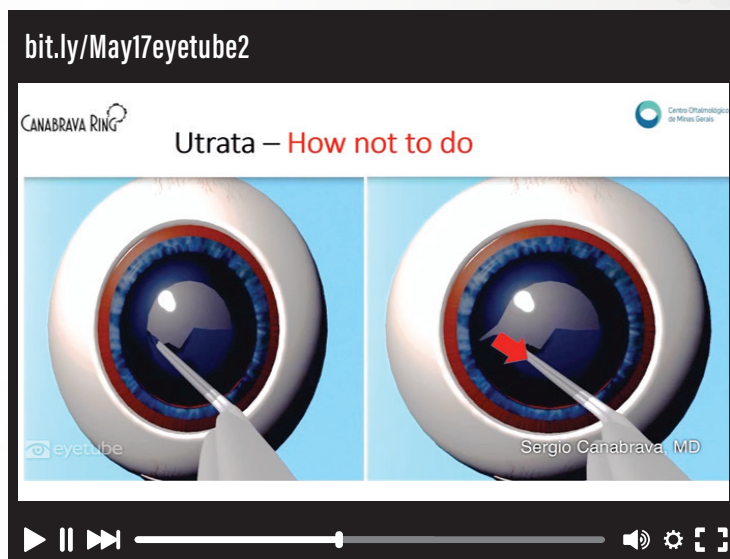
White Cataract With Silicone Oil

By Lisa Arbisser, MD



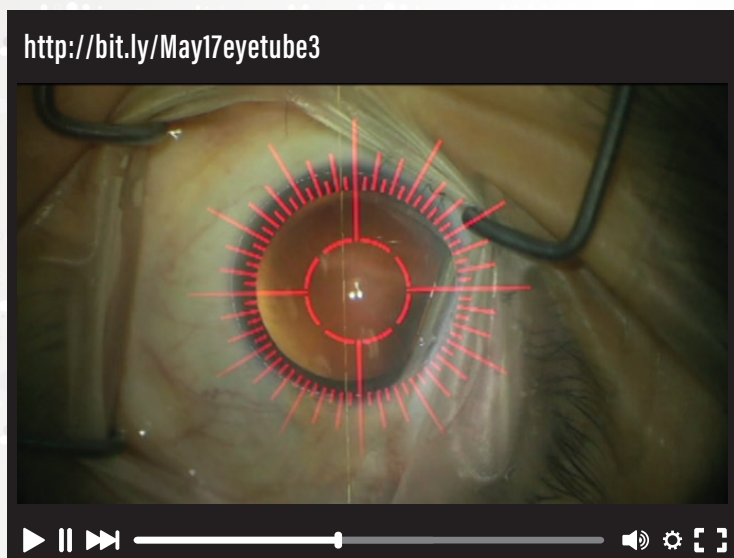
Rhexis Management

By Sergio Canabrana, MD



Positioning a Toric IOL With Callisto Guidance

By Bryan Lee, MD, JD



IOL Exchange With Scaffold Technique

By Maria Soledad Romero, MD

