

VISUAL EVOKED POTENTIAL

Can information from a single diagnostic test help clinicians prevent vision loss?

BY WILLIAM ERIC SPONSEL, MD



Recent advances in automated perimetry and optical coherence tomography have demonstrated strong clinicopathologic associations between scotomata and nerve fiber layer thinning. This gives eye care providers more confidence when diagnosing glaucoma and monitoring the efficacy of treatment.

Verifying the presence and extent of glaucoma is no longer a major problem. Identifying which patients receiving therapy remain at risk of disease progression, however, has continued to be a guessing game.

Many patients with seemingly adequate IOP control in the clinic continue to lose function. Some of them may not adhere to prescribed medical therapy, and others may have a more IOP-independent multifactorial disease etiology or even intermittent angle closure. Whatever the source of the problem for a given patient, even if visual field testing were repeated at 4-month intervals, it would be expected to take 2 years to verify chronic disease progression using the latest visual field progression software. That is a long time to wait to make appropriate adjustments in treatment interval and intensity. A dynamic functional test that provided prognostic information on the basis of a single visit might help avoid needless morbidity and reduce costs considerably.

VISUAL EVOKED POTENTIAL AND ELECTRORETINOGRAPHY

The literature on the potential diagnostic and prognostic utility of visual evoked potential (VEP) and electroretinography (ERG) is extensive.^{1,2} VEP is an objective measure of visual function that assesses the electrical activity of the cerebral cortex via electrodes placed on the scalp while the subject views standardized visual stimuli. The amplitude and latency of the VEP waveforms are affected by various pathologic conditions of the visual pathway, including glaucoma.

Recent technological developments have made VEP and ERG assessment faster and more patient friendly through the automated interpretation of test results and a reduction in the cost of the instrumentation. One example is short-duration transient VEP (SD-tVEP), which combines synchronized signal acquisition with a postprocessing technique to decrease subjectivity in waveform assessment (Figures 1 and 2).³

RESEARCH

Methodology

My colleagues and I recently undertook to determine the association of SD-tVEP amplitude and latency abnormality scores (Diopsys NOVA-LX; Diopsys) with perimetric staging and to explore potential single-visit SD-tVEP prognostic utility using 30-2 visual field progression data (Humphrey Field Analyzer [HFA]; Carl Zeiss Meditec). This cross-sectional study was performed in our glaucoma subspecialty clinic. It involved a broad array of adult patients already receiving medical, laser, and/or surgical therapy for their glaucoma, all with good IOP control on the day of a single SD-tVEP evaluation. Testing was performed by qualified ophthalmic technicians who regularly perform visual field and optical coherence tomography testing. None had any prior experience with electrophysiology.

The proportion of eyes designated as suspicious or abnormal by the Diopsys Nova-LX scoring algorithm was determined for patients with differing perimetric disease severity based on their latest HFA 30-2 visual field (mild, mean deviation (MD) > -6 dB; moderate, -6 to -12 dB; severe, MD < -12 dB). We compared latency failure with HFA Guided Progression Analysis acquired over the preceding 4 to 7 years to determine whether a single VEP test might help to identify eyes at increased risk of



Figure 1. Clinical setup of the Diopsys SD-tVEP testing system. ERG studies can be performed using the same apparatus with adhesive lower-lid skin electrodes.

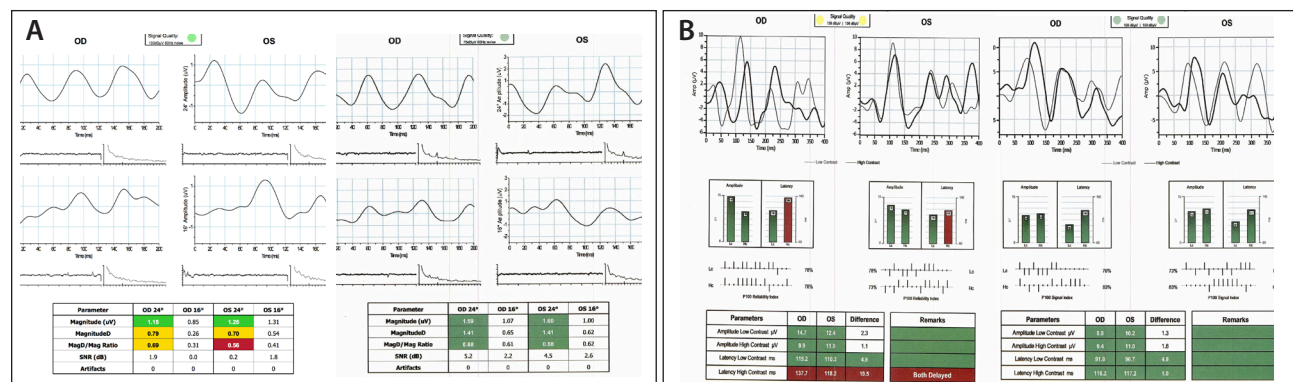


Figure 2. ERG (A) and VEP (B) response of a 26-year-old man who had normal visual fields and symmetric moderate cupping but also classic gonioscopic evidence of intermittent angle-closure glaucoma (frontal headache, stabbing ocular pain, and irideal pigment anterior to the trabecular meshwork). Visual acuity measured 20/20 OU. The referring physician prescribed topical timolol, brimonidine, and bimatoprost. Over the course of 2 months, Dr. Sponsel reaffirmed normal perimetric findings bilaterally and performed tonometry nine times. On only one occasion was the IOP above 21 mm Hg in either eye (30 mm Hg OS). SD-tVEP and pattern ERG studies were abnormal in both eyes (pre-iridotomy images [left]). This finding prompted Dr. Sponsel and the patient to proceed with an Nd:YAG laser peripheral iridotomy in both eyes. Three weeks later, repeat ERG and VEP studies in both eyes had reverted to normal (postiridotomy images [right]).

progressive visual field loss. A highly significant correlation was observed between high-contrast SD-tVEP latency and visual field loss category ($P < .001$; Figure 3).

Results

We analyzed a total of 133 eyes of 84 patients (mean age, 68 years). SD-tVEP latency increased linearly with the severity of visual field loss under 85% (high) contrast testing conditions ($P = .001$). One-third of the eyes showed rapid progression (≥ 0.7 dB/y). Based on the progression analysis of more than 1,200 visual fields (a mean of more than 12 visual fields per eye [range, 5-18 fields]), nearly three-quarters (73%) of eyes demonstrating rapid disease progression showed a VEP latency abnormality on the Diopsys Nova-LX, whereas fewer than half (47%) of the more visually stable remaining eyes showed any latency abnormality. Across the entire study population, the mean progression rate for eyes with a latency abnormality was -0.87 ± 0.3 dB/y versus a rate of -0.32 ± 0.4 dB/y for those with normal latency. These data (W.E.S., unpublished data, 2015) suggest that SD-tVEP may afford incremental value as an elective, single-visit, prognostic test for glaucomatous progression.

PRACTICAL IMPLICATIONS

What is the clinical value of this kind of incremental informational yield? The question is probably best considered in the context of disc hemorrhage, the most widely studied and best-established single-visit clinical prognostic indicator predictive of visual field loss. De Moraes et al recently confirmed disc hemorrhage as "the single most significant predictor of visual field progression."⁴ In a recent 8-year follow-up, Medeiros et al determined that the relative rates of visual field progression for eyes with and without disc hemorrhages were $-0.88\%/y$ versus

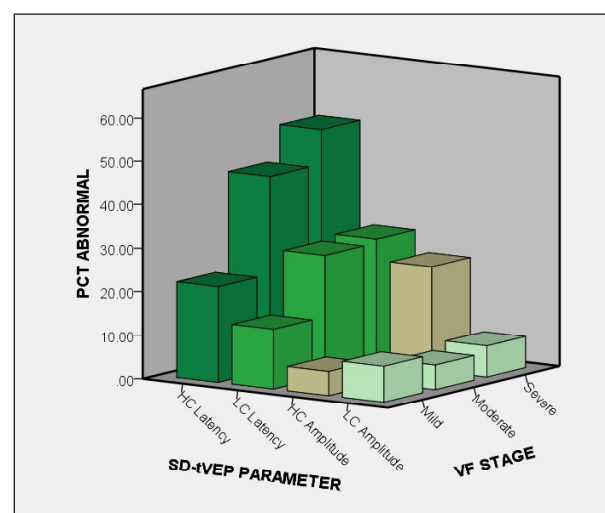


Figure 3. Proportion of eyes (percentage [PCT]) scored as abnormal by the Diopsys Nova-LX automated analysis for low-contrast (Lc) and high-contrast (Hc) SD-tVEP amplitudes and latencies (SD-tVEP Parameter) in actively treated glaucomatous eyes demonstrating mild, moderate, or severe Humphrey 30-2 visual field survival status (VF stage). Note that the amplitude would be expected to reflect the combined extent of axonal dysfunction and axonal loss, whereas latency would be expected to reflect the conduction velocity along surviving and functionally active axonal pathways. Glaucomatous eyes with less visual field pathology demonstrated significantly lower rates of SD-tVEP latency failure. Eyes with normal latency values also tended to demonstrate lower rates of ongoing visual field progression than those with abnormal latency values among the total study population.



AT A GLANCE

- Many patients with seemingly adequate IOP control in the clinic continue to lose function.
- A dynamic functional test that provided prognostic information on the basis of a single visit might help avoid needless morbidity and reduce costs considerably.
- Recent technological developments have made VEP and ERG assessment faster and more patient friendly through the automated interpretation of test results and a reduction in the cost of the instrumentation.

-0.38%/y, respectively,⁵ a progression ratio remarkably similar to what we found using SD-tVEP latency abnormality. There is one very important difference: disc hemorrhages in the study by Medeiros et al arose spontaneously in only 2% of glaucomatous eyes per year, whereas almost any glaucoma patient may undergo testing with the Nova-LX at any time.

This is merely an encouraging start. There is plenty of room for improvement in these ratios as more information

is incorporated into Diopsys' comparative database for diseased and normal eyes. ■

1. Grehn F, Stamper R, eds. *Essentials in Ophthalmology: Glaucoma*. Berlin: Springer; 2006:75-89.
2. Zetlan SR, Sponsel WE. The role of psychophysiology tests in the evaluation of the glaucomatous patient. In: Higginbotham EJ, Lee DA, eds. *Management of Difficult Glaucoma: a Clinician's Guide*. Boston: Blackwell Scientific Publications; 1993:106-126.
3. Pillai C, Ritch R, Derr P, et al. Sensitivity and specificity of short-duration transient visual evoked potentials (SD-tVEP) in discriminating normal from glaucomatous eyes. *Invest Ophthalmol Vis Sci*. 2013;23:2847-2852.
4. De Moraes CG, Prata TS, Liebmann CA, et al. Spatially consistent, localized visual field loss before and after disc hemorrhage. *Invest Ophthalmol Vis Sci*. 2009;50:4727-4733.
5. Medeiros FA, Alencar LM, Sample PA, et al. The relationship between intraocular pressure reduction and rates of progressive visual field loss in eyes with optic disc hemorrhage. *Ophthalmology*. 2010;117:2061-2066.

William Eric Sponsel, MD

- runs a busy referral practice in San Antonio that specializes in the treatment of patients with complex glaucoma, hypotony, and eye trauma
- professor of biomedical engineering, University of Texas, San Antonio
- professor of vision sciences, University of the Incarnate Word, San Antonio
- (210) 223-9292; sponsel@earthlink.net
- financial disclosure: paid consultant to Diopsys but stated that much of the independent research described herein was performed and presented prior to this arrangement with no commercial conflict of interest