Laser Versus Manual Cataract Surgery

Does the strength of the capsulotomy differ?

BY BRENDAN VOTE, FRANZCO, AND SHAUN EWE, MBBS

Capsulotomy technique during cataract surgery has evolved significantly over the past 25 years. Typical of extracapsular cataract extraction in the 1980s, a can-opener technique by nature created multiple small anterior capsular (radial) tears in 100% of cases. In principle, this distributed stretching forces evenly around the capsulotomy opening during expression of the crystalline lens. Unfortunately, the posterior extension of some of these radial tears was common. Gimbel and Neuhann's development of a continuous curvilinear capsulorhexis (CCC) revolutionized the strength and integrity of the capsular opening and significantly improved intraoperative function.[1] Although radial tears can still occur with a CCC, they typically arise if the CCC is incomplete or when surgical instruments inadvertently traumatize the capsulotomy's margin. It is unusual for an intact CCC to tear spontaneously during the typical stresses of phaco cataract surgery.

The latest evolution in capsulotomy creation is the introduction of the femtosecond laser for cataract surgery. The laser creates a more consistent and precisely sized and shaped capsulotomy opening than manual techniques. It is hoped that better effective lens position will improve refractive outcomes. Despite rapid developments in femtosecond laser technology, one area of concern has emerged: the strength and integrity of the capsulotomy created during laser cataract surgery.

OUR RESEARCH

Early adopters of femtosecond laser technology using the first available platforms regularly cited incomplete capsulotomies and a potential learning curve effect as influencing the rate of anterior capsular complications.[2] A "perfectly" shaped and sized capsulotomy, therefore, did not necessarily correlate with perfect function (strength and integrity) intraoperatively.

These clinical (in vivo) safety signals were evident for laser cataract surgery when we analyzed anterior capsular tear rates in a multicenter, prospective, comparative cohort study.[3] We found a statistically significantly ($P = .0002$) increased rate of anterior capsular tears in the laser group (15/804 patients [1.87%]) compared to the manual group (1/822 [0.12%]). There was no learning curve effect evident from our data, and all tears occurred in eyes with a complete capsulotomy. A varying prevalence of anterior capsular tears has been reported, and their occurrence likely depends on many factors, including surgical case mix. Because this safety signal (anterior capsular tears) occurs with all of the femtosecond laser platforms, its root cause is likely an effect of the technology itself.

We therefore further investigated anterior capsulotomy specimens from four different surgeons in different centers using three laser platforms (Catalys Precision Laser System [Abbott Medical Optics], LenSx Laser [Alcon], and Lensar Laser System [Lensar]). We collected both laser cataract surgery and phaco cataract surgery specimens, and we assessed ultrastructural features under scanning electron microscopy. Although the macroscopic appearance suggested perfectly circular capsulotomies, magnification revealed inconsistent and undulating lasered edges with occasional capsular tags extending obliquely from the capsular edge. The samples from all laser platforms (Figure A-C) had regular lines of aberrant, misplaced laser perforations and frequently had tags and skip lesions, presumably from microscopic fixational eye movements.[3] Closer inspection of the capsulotomy's edge revealed post-age-stamp perforations; the serrated edge was more in keeping with a microscopic can-opener capsulotomy and was visually different than the smooth edges we saw in the manual cataract surgery specimens (Figure D). These features suggest a plausible biomechanical basis for weak-

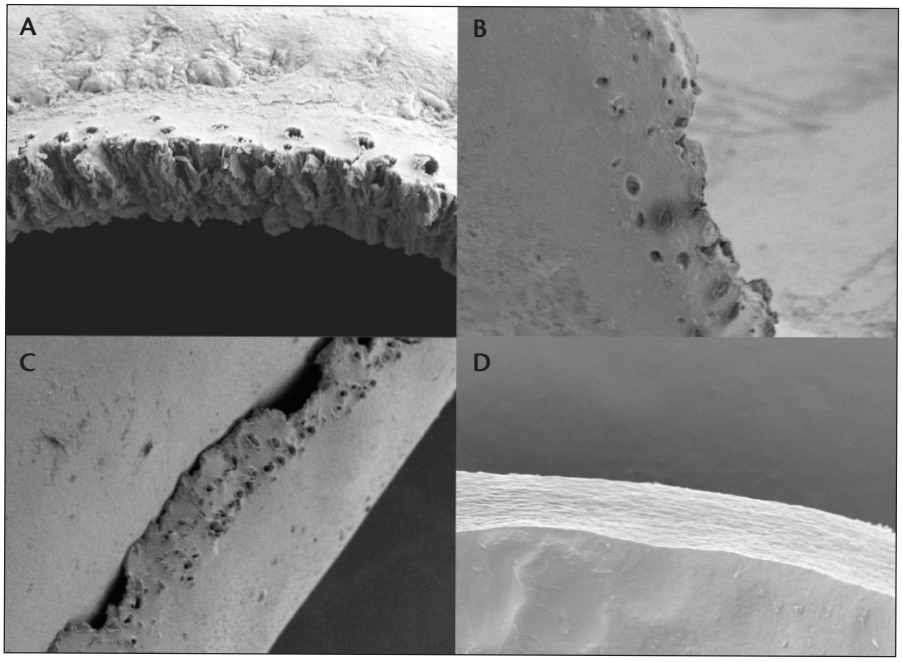

Figure. Irregular, perforated, femtosecond laser-cut, capsular edge structure with misplaced laser pits away from the capsular margin seen in capsulotomies created with all three laser systems: Catalys Precision Laser System (A), LenSx Laser (B), and Lensar Laser System (C). The edges of a manual capsulorhexis, however, are smooth and consistent (D).

ness in a laser capsulotomy, and our findings were independent of the laser platform used. Morphological differences in the laser capsulotomy edge structures can result from the use of different patient interfaces and energy settings, findings highlighting that these effects are induced by the laser.[4,5]

eyetube.net

eyetube.net/?v=omire

LIMITED DATA

Data on capsulotomy strength after laser cataract surgery in humans are limited. Increased strength was suggested by a porcine study, which demonstrated significantly greater anterior capsular strength in the laser capsulotomy compared to the manually performed capsulotomy.[6] An imperfect circular manual capsulorhexis was suggested as a factor. The results inferred from the porcine model may not be directly comparable to humans in vivo, however, due to different biomechanical properties (elasticity) and thickness of the anterior capsule.

The rupture load and extensibility results of the porcine study of laser cataract surgery are not consistent with the findings of prior studies of capsular strength that include research using human cadavers (see Abell et al for a full list of references[3]). These studies demonstrated that a capsulotomy performed using diathermy, a can-opener technique, or with postage-stamp perforations was less resistant to capsular tears than the smooth capsular edge created by a CCC. Disruption of the normal collagen microfibrillar arrangement and irregularities at the edges of the capsulotomy may act as focal points for stress that make the propagation and development of a capsular tear more likely (Figure A-C). In contrast, the CCC edge preserves collagen arrangement (Figure D), with the limiting distension reached only when the elastic limit of the capsule is exceeded.

CONCLUSION

The technology for laser cataract surgery continues to evolve, as do adaptive surgical responses. Further research is warranted nonetheless, including studies of capsular strength in human cadavers. The goal is to better understand the influence of laser cataract surgery on the capsulotomy's integrity and the factors involved in propagating anterior capsular tears in intact laser capsulotomies under the normal stretching fluidic or tensile forces of cataract removal. ■

Shaun Ewe, MBBS, is a clinical research fellow at the Tasmanian Eye Institute, Launceston, Tasmania, Australia. He acknowledged no financial interest in the products or companies mentioned herein.

Brendan Vote, FRANZCO, is medical director of the Tasmanian Eye Institute, Launceston, Tasmania, Australia. He acknowledged no financial interest in the products or companies mentioned herein. Associate Professor Vote may be reached at +613 6344 1377; eye.vote@me.com.

1. Gimbel HV, Neuhann T. Development, advantages, and methods of the continuous circular capsulorhexis technique. *J Cataract Refract Surg*. 1990;16(1):31-37.
2. Bali SJ, Hodge C, Lawless M, et al. Early experience with the femtosecond laser for cataract surgery. *Ophthalmology*. 2012;119:891-899.
3. Abell RG, Davies PEJ, Phelan D, et al. Anterior capsulotomy integrity after femtosecond laser-assisted cataract surgery. *Ophthalmology*. 2014;121:17-24.
4. Kohnen T, Klaproth OK, Ostovic M, et al. Morphological changes in the edge structures following femtosecond laser capsulotomy with varied patient interfaces and different energy settings. *Graefes Arch Clin Exp Ophthalmol*. 2014;252:293-298.
5. Mastropasqua L, Toto L, Calienno R, et al. Scanning electron microscopy evaluation in femtosecond laser-assisted cataract surgery. *J Cataract Refract Surg*. 2013;39(10):1581-1586.
6. Auffarth GU, Reddy KP, Ritter R, et al. Comparison of the maximum applicable stretch force after femtosecond laser-assisted and manual anterior capsulotomy. *J Cataract Refract Surg*. 2013;39:105-109.