Descemet Stripping Endothelial Keratoplasty

The new standard in treating corneal endothelial disease.

BY W. BARRY LEE, MD

Endothelial keratoplasty (EK) is the most commonly performed corneal transplant procedure in the United States. An analysis of the Eye Bank Association of America's 2013 Statistical Report shows an 18-fold increase in the number of EK procedures in this country, from 1,398 in 2005 to 24,987 in 2013.[1] Conversely, the number of penetrating keratoplasty (PKP) procedures decreased by 50% in the same time frame. These trends reflect the numerous advantages of EK over PKP, including a faster visual recovery, a lower risk of intraoperative complications from avoidance of an open sky, and less postkeratoplasty astigmatism.[2,3]

Descemet stripping endothelial keratoplasty (DSEK) is the most widely adopted EK technique domestically and throughout the world. Despite its popularity, interest is growing in a new EK technique known as Descemet membrane endothelial keratoplasty, with an increasing number of reports in the peer-reviewed literature and at scientific meetings. Only 6% of EK procedures performed in the United States in 2013 were Descemet membrane endothelial keratoplasty, however, whereas 94% were DSEK.[1]

INDICATIONS

The indications for DSEK include any disease that compromises the corneal endothelium. Although Fuchs endothelial corneal dystrophy remains the leading indication for DSEK in the United States, others include pseudophakic or aphakic bullous keratopathy, the failure of prior endothelial or penetrating keratoplasty, posterior polymorphous corneal dystrophy, congenital hereditary endothelial corneal dystrophy, and iridocorneal endothelial syndrome (Figure 1).

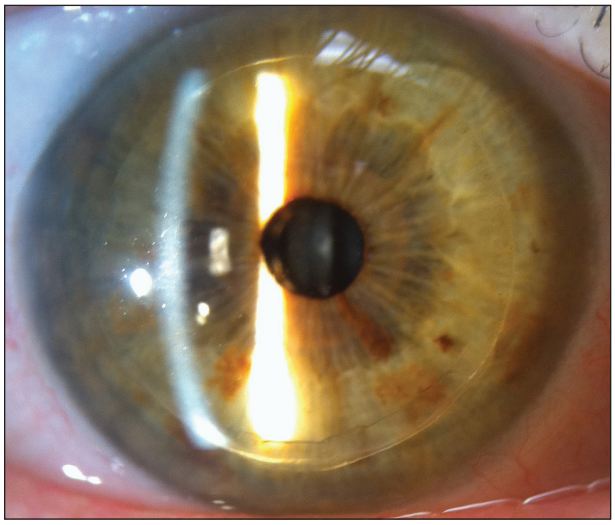

Figure 1. Appearance of an eye at the slit lamp 6 weeks after successful DSEK for Fuchs endothelial corneal dystrophy.

THE PROCEDURE

The DSEK procedure involves three main steps: (1) preparation of the donor cornea, (2) removal of the diseased endothelium, and (3) insertion and adherence of the new donor endothelium. The preparation of donor tissue requires the use of an artificial anterior chamber to create the desired donor posterior corneal tissue. The process has evolved from challenging and complex intraoperative manual dissections to the use

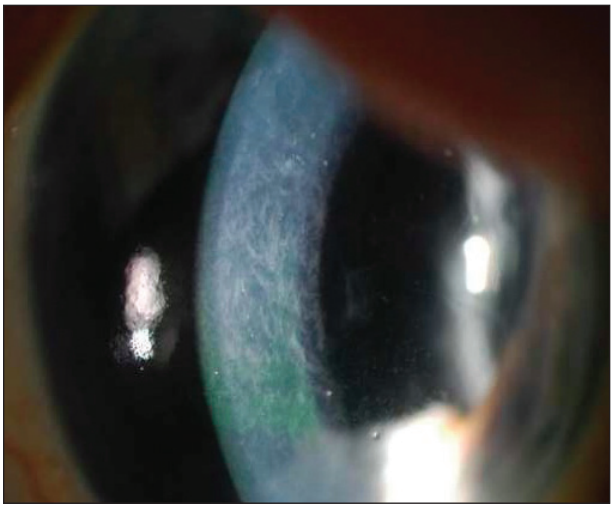

Figure 2. Reticular haze after DSEK.

Figure 3. An interface infiltrate from a fungal infection related to *Candida glabrata*. The donor rim culture was positive for the same species.

of mechanical microkeratomes and femtosecond lasers to cut tissue. Advanced technology has made this step much more reproducible and reduced the risk of complications. Owing to concerns about laser energy-induced damage to the donor endothelium, microkeratomes remain the more popular device for cutting the donor tissue to the desired thickness on an artificial chamber.

Another evolution is a shift from DSEK tissue prepared intraoperatively by the surgeon to tissue prepared by a technician in the eye bank. There are several advantages of eye bank tissue preparation. Cases are not cancelled due to donor perforation at the time of surgery. Expensive equipment need not be purchased for tissue preparation. OR efficiency increases. Optical coherence tomography readings and endothelial cell counts after DSEK cuts tell surgeons the precise health and thickness of the donor endothelium.

OUTCOMES

The outcomes of DSEK remain superior to those of any other keratoplasty technique for the surgical treatment of endothelial diseases of the cornea.[2,3] A meta-analysis of the EK literature found a mean Snellen BCVA of 20/45, induced astigmatism of 0.10 D, induced hyperopia of 1.10 D, graft survival of 94% at 2 years, and mean endothelial cell loss of 42% at 2 years.[2] Five-year data on DSEK showed a mean Snellen BCVA of 20/34, mean induced astigmatism of 0.50 D, mean hyperopia of 0.90 D, graft survival of 95%, and mean endothelial cell loss of 53%.[3] In comparison, the Cornea Donor Study found a graft survival rate of 86% and mean overall endothelial cell loss of 70% 5 years after PKP.[4]

COMPLICATIONS

Despite the compelling data on EK outcomes, a unique set of complications remains inherent to DSEK. Their expeditious recognition and treatment are paramount for improving the success of surgery.

The most common complications specific to EK involve the interface, of which a dislocated graft from interface fluid is the most frequent. Finding a successful and reproducible technique and gaining experience should dramatically reduce how often a surgeon experiences this problem. Fortunately, dislocations are not difficult to treat in the office or surgical suite.

Another potential interface complication is reticular haze.[5] It is thought to represent either irregularities in the collagen stromal fibers after cutting with a microkeratome or viscoelastic retained in the interface

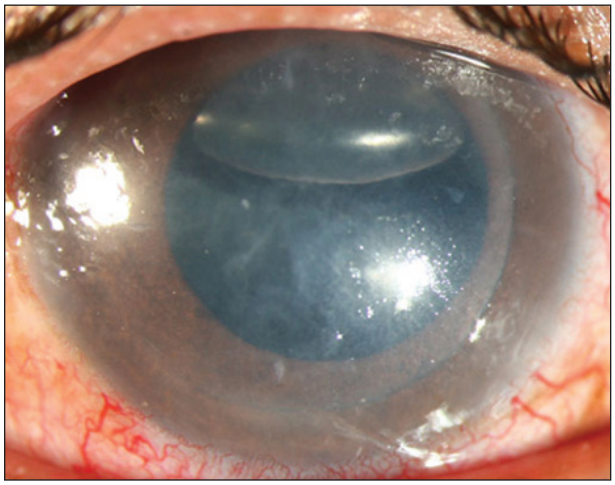

Figure 4. An air bubble behind the iris is causing pupillary block and a middilated pupil.

(Figure 2). Unfortunately, reticular haze does not respond to topical steroids or antibiotics. The complication typically resolves over time, however, and rarely requires surgical intervention.

Additional interface foreign bodies may include epithelial cells (epithelial ingrowth), debris, heme, and infection. Interface infections usually represent fungal pathogens and most likely stem from positive yeast on the donor corneal tissue (Figure 3).[6] Although cultures of the donor rim may form false positives for bacteria, a high correlation exists between a positive fungal donor corneal rim and the development of fungal keratitis. In addition to cultures of DSEK donor rims, confocal microscopy can be a useful tool when patients develop inflammation in the anterior chamber and/or posterior corneal stroma or when white opacities of the interface form a few weeks after surgery.

The final group of complications unique to EK relates to the air bubble. Pupillary block glaucoma is perhaps the most severe of these if not addressed immediately in the postoperative period by the release of intraocular air from the pupil or behind the iris (Figure 4). Other complications are direct endothelial cell damage from expansile gases or long exposure times to air as well as Urrets-Zavalia syndrome.

CONCLUSION

The visual and refractive outcomes of DSEK are nothing short of amazing compared with those of PKP. Although results continue to improve with new DSEK techniques, ophthalmologists must remember that no surgery is devoid of complications. Their prompt identification and treatment will improve outcomes as well as the ultimate satisfaction of patients and referring doctors. ■



W. Barry Lee, MD, is a partner at Eye Consultants of Atlanta and co-medical director of the Georgia Eye Bank, both located in Atlanta, Georgia. Dr. Lee may be reached at lee0003@aol.com.

1. Eye Bank Association of America. 2013 Statistical Report. www.restoresight.org/about-us/ebaa-materials-publications. Accessed June 16, 2014.
2. Lee WB, Jacobs DS, Musch DC, et al. Descemet's stripping endothelial keratoplasty: safety and outcomes. *Ophthalmology*. 2009;116:1818-1830.
3. Price MO, Fairchild KM, Price DA, Price FW. Descemet's stripping endothelial keratoplasty: five year graft survival and endothelial cell loss. *Ophthalmology*. 2011;118:725-729.
4. Lass JH, Gal RL, Dontchev M, et al. Donor age and corneal endothelial cell loss 5 years after successful corneal transplantation. *Ophthalmology*. 2008;115:627-632.
5. Vira S, Shih CY, Ragusa N, et al. Textural interface opacity after Descemet automated endothelial keratoplasty: a report of 30 cases and possible etiology. *Cornea*. 2013;32:354-359.
6. Lee WB, Foster JB, Kozarsky AM, et al. Interface fungal keratitis after endothelial keratoplasty: a clinicopathological report. *Ophth Surg Lasers Imag*. 2011;42:e44-48.