ONLINE SURVEY

How to Perform CXL

Current options beyond the standard protocol.

BY ALEKSANDAR STOJANOVIC, MD, AND XIANGJUN CHEN, MD, MS

Since first introduced by Seiler and Spoerl in 1997,[1] corneal collagen cross-linking (CXL) has proven safe and effective for improving the biomechanical stability of eyes with keratoconus (KC) and related keratectatic conditions.[2-5] Unlike the earlier treatments of KC that only attempted to ameliorate the disease's consequences, CXL addresses the corneal biomechanical weakening itself. The procedure has also been suggested for a number of other corneal conditions such as bullous keratopathy,[6,7] microbial keratitis,[8-12] and corneal ulceration[8] as well as for modifying donor tissue prior to keratoplasty[13] and as an adjunct to orthokeratology.

Often called the *Dresden protocol*, the standard CXL protocol described by Wollensak and colleagues provided the foundation for a broad evaluation of the CXL procedure and established the benchmarks for its safety and efficacy.[2] As surgeons' knowledge of CXL has increased and the indications for its use have widened, various modifications of the Dresden protocol have emerged, raising the possibility of individualizing treatments for various stages and forms of keratectatic disease. Current modifications include the use of CXL without epithelial removal, variations on ultraviolet A (UVA) fluence and duration, and the combination of CXL with procedures aimed at optical improvement and visual rehabilitation.

DRESDEN PROTOCOL

The Dresden protocol includes removal of the corneal epithelium in a diameter of 9 mm, followed by saturation of the corneal stroma using 0.1% isotonic riboflavin solution in 20% dextran and UVA irradiation with 5.4 J/cm^2 (3 mW/cm^2 for 30 minutes). Reported refinements of the epithelial removal involve the use of various debridement burrs, alcohol solutions, phototherapeutic keratectomy,[14] or Daya's epithelial disrupter (Duckworth & Kent Ltd.). Minor protocol adjustments have been introduced to improve the safety of the procedure. Examples include inducing miosis with pilocarpine to protect the retroiridal structures and the use of a Merocel ring (Medtronic, Inc.) to shield the limbal area. A new generation of UV lamps uses either a top hat instead of Gaussian beam profile (KXL; Avedro Inc.) or the spatially adjusted distribution of UV energy from the multiple UV diodes to compensate for the midperipheral loss of energy in the dome-shaped cornea (UV-X 2000; IROC Innocross AG).

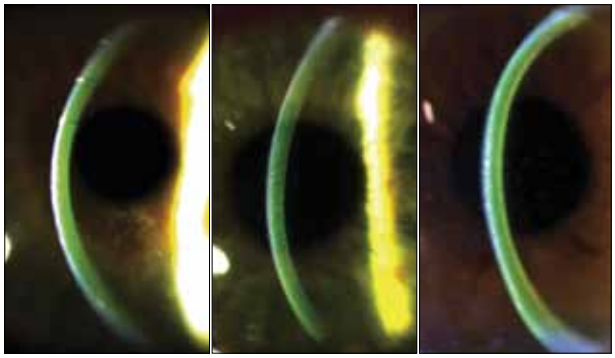

Figure. Stromal saturation with riboflavin achieved after epithelial puncture with Daya's epithelial disrupter (left), after chemically enhanced epithelial permeability (center), and after epithelial removal (right).

TRANSEPITHELIAL CXL

Postoperative discomfort, a possibility of delayed epithelial healing,[14] infection,[15] stromal haze,[16] and corneal melting[17] represent the disadvantages of epithelial debridement that have led surgeons to explore transepithelial CXL. The reported clinical outcomes are promising.[18,19] Experimental studies, however, have shown a significantly lower efficacy of transepithelial CXL compared to the standard epithelium-off approach[20-22] due to the low epithelial permeability of riboflavin. Chemical enhancers such as benzalkonium chloride,[23] trometamol, and ethylenediaminetetraacetic acid[19] as well as the use of hypotonic riboflavin solution[24] without dextran seem to enhance riboflavin's penetration. The use of iontophoresis[25] and scarification of the superficial epithelial layers also enhance riboflavin's penetration through the epithelium.

No matter which approach is used, stromal saturation with riboflavin is crucial and should always be visualized (Figure) before the UVA irradiation. Some researchers

> "A very low failure rate with the Dresden protocol ... implies that surgeons may be applying more treatment than necessary."

claim that, even with a sufficient stromal concentration of riboflavin, the effect of the transepithelial CXL may be decreased due to the attenuation of UVA radiation by the epithelium.[26] That would imply that UVA energy must be increased beyond the current level of 5.4 J/cm^2 when the epithelium is kept intact.

ACCELERATED CXL

New UV lamps are manufacturers' response to the growing demand among surgeons to shorten the duration of UVA irradiation. Some of the lamps offer fixed treatment times of 10 and 5 minutes with the use of a power of 10 and 18 mW/cm^2 for the UV-X 2000 and CCL 365 HE (Peschke Meditrade GmbH), respectively. The KXL system allows a wide range of adjustable times (1-30 minutes) with a UV power of 3 to 45 mW and increased maximum irradiance to 10 J/cm^2. (For more on UV lamps, please see the article by Drs. Cummings and Rajpal on page 40 of this issue.)

Kanellopoulos reported that the use of higher-fluence UVA for a shorter time (7 mW/cm^2 for 15 minutes) is safe and effective.[27] He found that this approach achieves similar clinical results to the Dresden protocol in terms of stabilizing ectasia.[14]

COMBINED TECHNIQUES

Although CXL stops the keratectatic process in most cases, the procedure itself often is not sufficient to provide visual rehabilitation. Ophthalmologists, therefore, have attempted to combine CXL with various refractive surgical techniques. The implantation of intracorneal ring segments with sequential or subsequent CXL has proven effective.[28,29] The limited use of topography-guided transepithelial PRK followed by CXL has also been shown to improve visual acuity and stabilize KC.[30,31] Same-day PRK followed by CXL appears to be superior to sequential PRK after CXL, and the former has been widely used as the Athens protocol.[30] Combining CXL with the implantation of a phakic toric IOL safely and effectively corrects myopic astigmatism in eyes with mild to moderate KC.[32] The triple procedure of CXL combined with topography-guided PRK to regularize the corneal shape and the implantation of a phakic IOL to optimize the refraction may rehabilitate the patient's vision with a higher predictability of the refractive outcome compared with CXL combined with topography-guided PRK alone.

EFFICACY

The exact amount of CXL needed to achieve a successful clinical outcome is currently unknown. A very low failure rate with the Dresden protocol, however, implies that surgeons may be applying more treatment than necessary. Modifications of physical parameters like the local concentration of riboflavin in stromal tissue, UVA fluence, and the duration of the UVA exposure are interrelated. A model for optimization has been presented,[33] thus allowing customization of the amount and depth of cross-linking. At this stage, however, any changes to the Dresden protocol should be applied cautiously and systematically. ■

Note: CXL is not FDA approved.

Aleksandar Stojanovic, MD, is in charge of refractive surgery and keratoconus, Department of Ophthalmology, University Hospital of North Norway, and is medical director of SynsLaser Kirurgi, Tromsø and Oslo, Norway. He acknowledged no financial interest in the products or companies mentioned herein. Dr. Stojanovic may be reached at +47 90693319; aleks@online.no.

Xiangjun Chen, MD, MS, is in charge of research and development at SynsLaser Kirurgi, Tromsø and Oslo, Norway. She acknowledged no financial interest in the products or companies mentioned herein. Dr. Chen may be reached at +47 45511001; chenxiangjun1101@gmail.com.

1. Spörl E, Huhle M, Kasper M, Seiler T. Increased rigidity of the cornea caused by intrastromal cross-linking [in German]. *Ophthalmologe*. 1997;94:902-906.
2. Wollensak G, Spoerl E, Seiler T. Riboflavin/ultraviolet-a-induced collagen crosslinking for the treatment of keratoconus. *Am J Ophthalmol*. 2003;135:620-627.
3. Mazzotta C, Traversi C, Baiocchi S, et al. Conservative treatment of keratoconus by riboflavin-UVA-induced cross-linking of corneal collagen: qualitative investigation. *Eur J Ophthalmol*. 2006;16:530-535.
4. Mazzotta C, Balestrazzi A, Traversi C, et al. Treatment of progressive keratoconus by riboflavin-UVA-induced cross-linking of corneal collagen: ultrastructural analysis by Heidelberg Retinal Tomograph II in vivo confocal microscopy in humans. *Cornea*. 2007;26:390-397.
5. Hafezi F, Kanellopoulos J, Wiltfang R, Seiler T. Corneal collagen crosslinking with riboflavin and ultraviolet A to treat induced keratectasia after laser in situ keratomileusis. *J Cataract Refract Surg*. 2007;33:2035-2040.
6. Ehlers N, Hjortdal J. Riboflavin-ultraviolet light induced cross-linking in endothelial decompensation. *Acta Ophthalmologica*. 2008;86:549-551.
7. Wollensak G, Aurich H, Wirbelauer C, Pham DT. Potential use of riboflavin/UVA cross-linking in bullous keratopathy. *Ophthalmic Res*. 2009;41:114-117.
8. Iseli HP, Thiel MA, Hafezi F, et al. Ultraviolet A/riboflavin corneal cross-linking for infectious keratitis associated with corneal melts. *Cornea*. 2008;27:590-594.
9. Moren H, Malmsjo M, Mortensen J, Ohrstrom A. Riboflavin and ultraviolet a collagen crosslinking of the cornea for the treatment of keratitis. *Cornea*. 2010;29:102-104.
10. Schrier A, Greebel G, Attia H, et al. In vitro antimicrobial efficacy of riboflavin and ultraviolet light on Staphylococcus aureus, methicillin-resistant Staphylococcus aureus, and Pseudomonas aeruginosa. *J Refract Surg*. 2009;25:S799-802.
11. Makdoumi K, Backman A, Mortensen J, Crafoord S. Evaluation of antibacterial efficacy of photo-activated riboflavin using ultraviolet light (UVA). *Graefes Arch Clin Exp Ophthalmol*. 2010;248:207-212.
12. Martins SA, Combs JC, Noguera G, et al. Antimicrobial efficacy of riboflavin/UVA combination (365 nm) in

vitro for bacterial and fungal isolates: a potential new treatment for infectious keratitis. *Invest Ophthalmol Vis Sci*. 2008;49:3402-3408.
13. Wang F. UVA/riboflavin-induced apoptosis in mouse cornea. *Ophthalmologica*. 2008;222:369-372.
14. Kanellopoulos AJ. Long term results of a prospective randomized bilateral eye comparison trial of higher fluence, shorter duration ultraviolet A radiation, and riboflavin collagen cross linking for progressive keratoconus. *Clin Ophthalmol*. 2012;6:97-101.
15. Koppen C, Vryghem JC, Gobin L, Tassignon MJ. Keratitis and corneal scarring after UVA/riboflavin cross-linking for keratoconus. *J Refract Surg*. 2009;25:S819-823.
16. Mazzotta C, Balestrazzi A, Baiocchi S, et al. Stromal haze after combined riboflavin-UVA corneal collagen cross-linking in keratoconus: in vivo confocal microscopic evaluation. *Clin Experiment Ophthalmol*. 2007;35:580-582.
17. Eberwein P, Auw-Hadrich C, Birnbaum F, et al. Corneal melting after cross-linking and deep lamellar keratoplasty in a keratoconus patient [in German]. *Klin Monbl Augenheilkd*. 2008;225:96-98.
18. Leccisotti A, Islam T. Transepithelial corneal collagen cross-linking in keratoconus. *J Refract Surg*. 2010;26:942-948.
19. Filippello M, Stagni E, O'Brart D. Transepithelial corneal collagen crosslinking: bilateral study. *J Cataract Refract Surg*. 2012;38:283-291.
20. Hayes S, O'Brart DP, Lamdin LS, et al. Effect of complete epithelial debridement before riboflavin-ultraviolet-A corneal collagen crosslinking therapy. *J Cataract Refract Surg*. 2008;34:657-661.
21. Bottos KM, Schor P, Dreyfuss JL, et. Effect of corneal epithelium on ultraviolet-A and riboflavin absorption. *Arq Bras Oftalmol*. 2011;74:348-351.
22. Bottos KM, Dreyfuss JL, Regatieri CV, et al. Immunofluorescence confocal microscopy of porcine corneas following collagen cross-linking treatment with riboflavin and ultraviolet A. *J Refract Surg*. 2008;24:S715-719.
23. Kissner A, Spoerl E, Jung R, et al. Pharmacological modification of the epithelial permeability by benzalkonium chloride in UVA/riboflavin corneal collagen cross-linking. *Curr Eye Res*. 2010;35:715-721.
24. Raiskup F, Spoerl E. Corneal cross-linking with hypo-osmolar riboflavin solution in thin keratoconic corneas. *Am J Ophthalmol*. 2011;152:28-32 e21.
25. Vinciguerra P. Comparison of transepithelial and standard CXL. Paper presented at: The 7th International Congress of Corneal Cross-Linking; 2011; Zurich, Switzerland.
26. Baiocchi S, Mazzotta C, Cerretani D, et al. Corneal crosslinking: riboflavin concentration in corneal stroma exposed with and without epithelium. *J Cataract Refract Surg*. 2009;35:893-899.
27. Kanellopoulos AJ. Collagen cross-linking in early keratoconus with riboflavin in a femtosecond laser-created pocket: initial clinical results. *J Refract Surg*. 2009;25:1034-1037.
28. Kamburoglu G, Ertan A. Intacs implantation with sequential collagen cross-linking treatment in postoperative LASIK ectasia. *J Refract Surg*. 2008;24:S726-729.
29. Ertan A, Karacal H, Kamburoglu G. Refractive and topographic results of transepithelial cross-linking treatment in eyes with Intacs. *Cornea*. 2009;28:719-723.
30. Kanellopoulos AJ. Comparison of sequential vs same-day simultaneous collagen cross-linking and topography-guided PRK for treatment of keratoconus. *J Refract Surg*. 2009;25:S812-818.
31. Stojanovic A, Zhang J, Chen X, et al. Topography-guided transepithelial surface ablation followed by corneal collagen cross-linking performed in a single combined procedure for the treatment of keratoconus and pellucid marginal degeneration. *J Refract Surg*. 2010;26:145-152.
32. Guell JL, Morral M, Malecaze F, et al. Collagen crosslinking and toric iris-claw phakic intraocular lens for myopic astigmatism in progressive mild to moderate keratoconus. *J Cataract Refract Surg*. 2012;38(3):473-484.
33. Schumacher S, Mrochen M, Wernli J, et al. Optimization model for UV-riboflavin corneal cross-linking. *Invest Ophthalmol Vis Sci*. 2012;53(2):762-769.