Posterior Capsular Rupture

When the size of a posterior capsular rent precludes an IOL's placement in the capsular bag, reverse optic capture of a toric IOL may be a safe option.

BY PATRICK GOOI, MD, AND IQBAL IKE K. AHMED, MD

This article details a case of posterior capsular rent managed with a vitrectomy and reverse optic capture of a toric IOL.

BACKGROUND

A 67-year-old woman with a prior history of laser peripheral iridotomies was referred for cataract surgery. Gonioscopy and anterior segment optical coherence tomography revealed grade 0 angles due to lens rise and plateau iris. The patient's BCVA was 20/30, and she had a mild grade 1+ nuclear sclerotic cataract. The axial length was 21.85 mm, the anterior chamber depth was 2.54 mm, and the lens thickness was 5.06 mm. She had 1.78 D of corneal astigmatism, and her preoperative refraction was +0.75 +1.75 D x 176º. We decided to proceed with cataract surgery, in part to reduce the patient's risk of angle-closure glaucoma. We chose to implant a toric IOL to limit her dependence on spectacles postoperatively. Preoperative toric IOL planning called for axial placement of 171º, which was marked on the cornea.

SURGICAL COURSE

During cataract surgery, it was difficult to remove the subincisional cortex. To surmount this challenge, we switched from coaxial to bimanual I/A. Tilting the eye away from the surgeon, toward the nose, by suboptimal instrument handling resulted in a poor view of the subincisional area, and a posterior capsular rent occurred. We injected a dispersive viscoelastic into the anterior chamber in the area of the rent, while keeping the irrigating handpiece in the eye on position zero. Doing so reduced shallowing of the anterior chamber, which could have extended the tear and encouraged vitreous to migrate anteriorly. The posterior capsular rent was too large to convert into a posterior capsulorhexis, and it was impossible to place the IOL in the capsular bag.

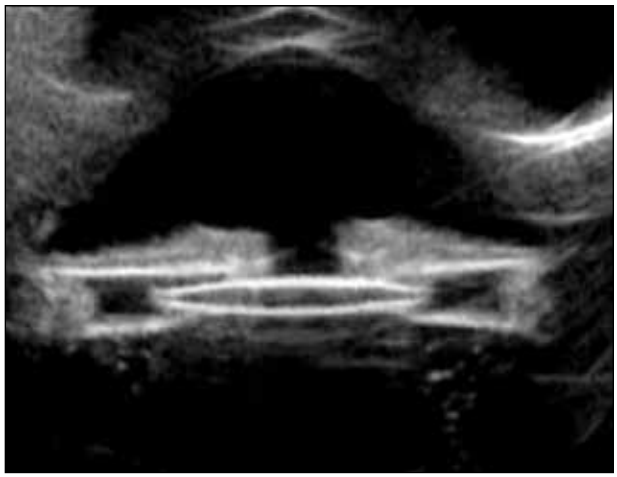

Figure. Ultrasound biomicroscopy of the reverse optic capture shows the optic anterior to the capsulorhexis and the haptics positioned in the capsular bag.

We made a second paracentesis for a bimanual vitrectomy. Diluted triamcinolone acetate was injected into the anterior chamber to stain the vitreous. After the vitrectomy and removal of residual cortex, an examination revealed an intact, appropriately sized anterior capsulorhexis for reverse optic capture of the IOL. Although a single-piece acrylic IOL should not be placed wholly within the sulcus, reverse optic capture may be a safe way to preserve the surgeon's ability to use these IOLs in the setting of a posterior capsular rupture. The anterior capsulorhexis must be smaller than the optic to permit reverse capture. In this situation, the optic sits anterior to

> "Correctly orienting a toric IOL's haptics is the biggest challenge of reverse optic capture."

the capsulorhexis, and the haptics lie in the capsular bag posterior to the capsulorhexis.

We proceeded with implantation of the intended single-piece toric IOL with reverse optic capture. After injecting the IOL into the anterior chamber, the assistant immediately retrieved the injector, and we maneuvered the IOL into the optimal position before the haptics unfolded fully.

THE "CARTWHEEL" MANEUVER

Correctly orientating a toric IOL's haptics is the biggest challenge of reverse optic capture. Manipulating the haptic closest to the surgeon is preferable so that the optic does not obstruct his or her view or the access for instruments. Iris forceps and microtyers (MicroSurgical Technology) are essential for manipulating the IOL in these cases, particularly for a maneuver we call "cartwheeling the IOL." First, we grasp the nasal haptic with an iris forceps. A Sinskey hook is used to support the optic posteriorly and serves as a pivot point. We cartwheel the IOL for 180º. This motion both captures the temporal haptic and rotates the IOL so that the captured haptic lies nasally along the intended axis of placement. As a result, the nasal haptic is captured, and the temporal haptic lies anterior to the iris. We use an iris forceps and microtyers to position the temporal haptic in the capsular bag, while taking care to keep the optic anterior to the capsule and not to rotate the IOL.

eyetube.net

eyetube.net/?v=vihev

OUTCOME

Endoscopic visualization confirmed the correct placement of the haptics, which were sitting in the capsular bag underneath the translucent capsulorhexis while the optic lay on top of the capsulorhexis. We placed 10–0 nylon sutures (Ethicon, Inc.) to close the wounds at the conclusion of the case. Ultrasound biomicroscopy of the reverse optic capture showed the optic anterior to the capsulorhexis and the haptics positioned in the capsular bag (Figure).

DISCUSSION

We believe this is a safe method for positioning the originally intended IOL. In our experience, there is a minimal risk of uveitis-glaucoma-hyphema syndrome, because the bulky haptics are in the capsular bag, well away from the iris, and the anterior capsule holds the optic's edge back and away from the iris. We generally do not adjust the IOL's power; we believe the effective lens position is not as anterior as a 100% sulcus-placed IOL, because the capsule holds the optic in a more posterior position. For a high-powered IOL (> 26.00 D), however, the surgeon may need to adjust the IOL's power (we are currently investigating this). In a study of 16 eyes that underwent reverse optic capture and were monitored for an average of 19 months, BCVA was 20/25 or better in 94% of the eyes, and the same proportion of eyes had a postoperative spherical equivalent within ±1.00 D of the intended refraction.[1]

This case illustrates that it is possible to reverse optic capture a toric IOL when the size of the posterior capsular rent precludes placement of an IOL in the capsular bag. Anterior segment microsurgical instruments and the cartwheeling maneuver are useful tools for achieving this objective. ■

Iqbal Ike K. Ahmed, MD, is an assistant professor at the University of Toronto and a clinical assistant professor at the University of Utah in Salt Lake City. He acknowledged no financial interest in the products or companies mentioned herein. Dr. Ahmed may be reached at (905) 820-3937; ike.ahmed@utoronto.ca.

Patrick Gooi, MD, is a fellow at the University of Toronto. He acknowledged no financial interest in the products or companies mentioned herein. Dr. Gooi may be reached at patrick.gooi@gmail.com.

1. Jones JJ, Oetting TA, Rogers GM. Reverse optic capture of the single-piece acrylic intraocular lens in eyes with posterior capsule rupture. *Ophthalmic Surg Lasers Imaging*. 2012;43(6):480–488.

SHARE YOUR FEEDBACK

Would you like to comment on an author's article? Do you have an article topic to suggest? We would like to hear from you. Please e-mail us at letters@bmctoday.com with any comments you have regarding this publication.