Traumatic Cataract

Preoperative evaluation and phacodynamics.

By Barry S. Seibel, MD

A complete preoperative evaluation of patients with a traumatic cataract is essential to developing a phacodynamic plan and optimizing surgical outcomes. The surgeon must anticipate how trauma will affect the intraocular manipulation of tissues and how it might affect the intra- and postoperative positioning of the IOL. Phacodynamics permits the customization of any cataract surgery through the intelligent use of the phaco machine's various parameters and surgical instruments to their best advantage.[1] In the case of a traumatic cataract, these adaptations enhance the safety of cases that are at increased risk of intra- and postoperative complications due to structural anomalies in the anterior segment.

PREOPERATIVE EVALUATION

The Slit-Lamp Examination

Obvious external signs of trauma, such as fibrous and/or vascular scars, may influence the surgical incision's architecture and location. For example, a temporal limbal scar may direct the surgeon to place the main cataract incision elsewhere, such as adjacent to the scar or superiorly, either in the sclera or sclerocornea. Making a new surgical incision through existing scar tissue risks unknown consequences with regard to the incision's postoperative integrity (even with sutures) as well as uncertain astigmatic effects. In addition, corneoscleral scar tissue could compromise the incision's intra- and postoperative seal, leading to anterior chamber instability.

In addition, the intraoperative visualization of necessary structures can be obscured by opacified corneal tissue. Intraoperative gonioscopy is awkward but can be of limited help for such steps as the capsulorhexis. The planned use of a capsular dye such as VisionBlue (DORC International BV, Zuidland, the Netherlands) may be of assistance. If scarring is extreme, however, the surgeon may consider a triple procedure with a corneal transplant in order to visualize the cataract procedure and to improve the patient's postoperative visual potential. If the surgeon cannot see adequately through the cornea, the patient likely will not be able to see out of it.

The preoperative slit-lamp evaluation continues with the iris, including the root and angle. Obvious and large iridodialyses can cause excessive glare through polycoria and compromise vision through an induced shift of the patient's physiologic pupil centroid. These issues may need to be addressed intraoperatively through iridoplasty, suturing the iris root with 9–0 Prolene (Ethicon, Inc., Somerville, NJ) and horizontal mattress sutures, and traumatic iridectomies with 10–0 Prolene and Siepser or McCannel methods. Hypotonic or atonic pupil sphincters may need either a sutured cerclage or an iris implant (not available in the United States; Morcher GmbH, Stuttgart, Germany). Michael Snyder, MD, of Cincinnati and Ike Ahmed, MD, of Toronto have produced extraordinary videos on this subject and on iris reconstruction. Irides with structural damage may exhibit floppiness as seen in intraoperative floppy iris syndrome and may require stabilization with iris hooks or a Malyugin Ring (MicroSurgical Technology, Redmond, WA).

Gonioscopic Examination

Gonioscopy may reveal an obvious or subtle angle recession, which may not itself need attention (other than monitoring for induced glaucoma). It may, however, indicate that significant blunt trauma to the eye has affected other structures such as the zonules or the crystalline lens.

In addition to angle recession, the surgeon must look for asymmetry in the gap between the pupil and the anterior lens capsule. As Robert Osher, MD, pointed out at the Hawaiian Eye meeting earlier this year, a significant lack of uniformity indicates a tilt of the lens caused by compromise of more than 180º of the zonules, which

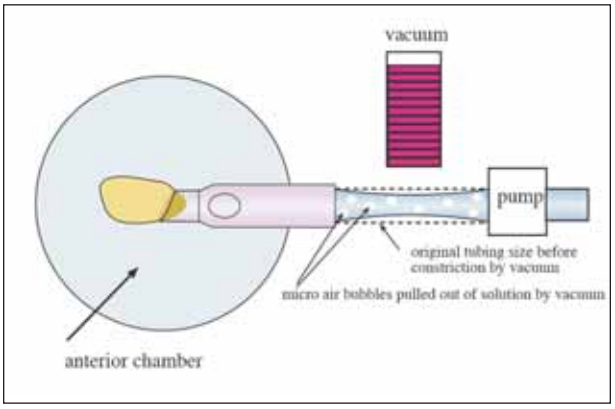

Figure 1. As vacuum builds up between the phaco machine's pump and the lens fragment occluding the distal aspiration port, compliance is pulled out of the system. The aspiration line tubing starts to collapse, and air can be pulled out of solution (bubbles from air venting can also be stretched open); both of these phenomena are a potential source of energy above that of the flow and vacuum parameters that were initially set on the machine under unoccluded steady-state conditions. (Reproduced with permission from Slack Incorporated. Seibel BS. *Phacodynamics: Mastering the Tools and Techniques of Phacoemulsification Surgery*. 4th ed. Thorofare, NJ: Slack Inc.; 2005.)

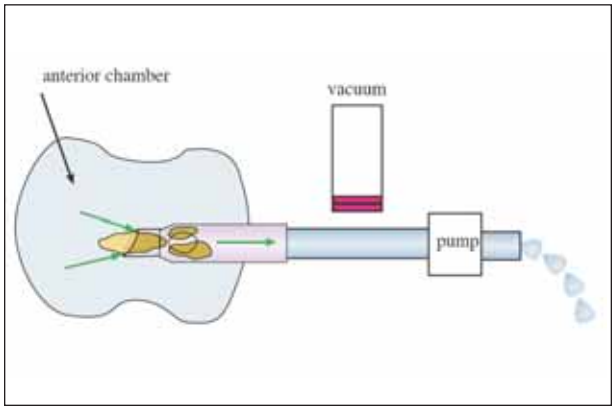

Figure 2. With the sudden breakdown of the occluding lens fragment, fluid rushes into the aspiration port faster than the steady-state flow that had been set on the machine under ideal steady-state conditions. This postocclusion surge is fueled by the re-expansion of the partially collapsed aspiration line tubing along with the collapse and resolution of transient air bubbles. (Reproduced with permission from Slack Incorporated. Seibel BS. *Phacodynamics: Mastering the Tools and Techniques of Phacoemulsification Surgery*. 4th ed. Thorofare, NJ: Slack Inc.; 2005.)

increases the likelihood of intraoperative vitreous prolapse. The slit-lamp examination of such compromised zonules typically reveals phacodonesis, either in normal microsaccadic movements in primary gaze or especially when induced by the patient's looking to the side and then back to primary gaze. Such significant zonular compromise will likely preclude secure fixation of the IOL in the bag, and the surgeon will want to plan alternatives such as sutured scleral or iris fixation of the lens implant.

Although a capsular tension ring (CTR) helps to reinforce the capsular bag structure, the device is effective only if more than 180° of the zonules are intact, unless the surgeon is using a Cionni Ring for Sclera Fixation (Morcher GmbH, Stuttgart, Germany; distributed in the United States by FCI Ophthalmics, Inc., Marshfield Hills, MA). Intraoperative capsular fixation may be achieved with iris or capsule hooks at the perimeter of the capsulorhexis. In these cases, the surgeon may elect to implant an IOL completely in the bag or to place the optic in the bag and the haptics in the sulcus, with or without iris or scleral fixation. An ACIOL may be an appropriate choice in many cases of inadequate capsular/zonular integrity.

Retinal Examination

The surgeon thoroughly examines the retina preoperatively to rule out tears or detachments that may have been induced by coup or contrecoup vitreous dynamics, especially in cases involving young patients and correspondingly tighter vitreoretinal adhesions. Consideration may be given to treating minor breaks prophylactically so as to reduce the chance of a retinal detachment during phaco surgery, which could complicate intraoperative anterior vitrectomy, if needed.

PHACODYNAMICS

Poor Visualization, Capsular and Zonular Laxity

Traumatic cataracts are not infrequently opaque and white with a compromised red reflex, which alerts the surgeon that performing the capsulorhexis will be challenging. Staining the capsule with VisionBlue provides invaluable guidance in these cases, but the surgeon must pay close attention to the initial capsulotomy incision/puncture. Specifically, he or she is looking for excessive folds or laxity in the anterior capsular surface indicating weak zonular support, at least anteriorly. Surgeons who use a cystotome for the entire capsulorhexis may wish to convert to a forceps for more consistent control of the engaged capsular flap in the presence of such laxity. Also, the initial capsulotomy entry may result in an immediate expulsion of white flocculent lens material that obscures visualization. The adequate initial placement of an ophthalmic viscosurgical device (OVD) and subsequent supplementation of the OVD can mitigate this problem, but some initial aspira-

tion of this lens material (via the I/A handpiece or cannula) may be required.

As mentioned earlier, a CTR may be indicated if less than half of the zonular clock hours are lax. In addition to improving intraoperative stability and postoperative support of the IOL, the CTR can keep open a previously involute section of peripheral capsule and help prevent intraoperative vitreous prolapse in that area.

Turbulence

Notwithstanding the constant phacodynamic goal of a stable anterior chamber during phaco surgery, the surgeon must be particularly cautious in the case of a traumatic cataract. Otherwise acceptable anterior chamber currents may be excessive in the presence of zonular compromise, which could foment further zonular damage and/or vitreous prolapse. The surgeon can decrease steady-state turbulence by setting a lower aspiration outflow rate on a flow pump or by using a lower commanded vacuum on a vacuum pump when the aspiration port is unoccluded. Momentary peaks of turbulence may be reduced by obtunding postocclusion surge (Figures 1 and 2).

One approach is to use a lower vacuum level when the aspiration port is occluded or to dynamically reduce a higher vacuum level just prior to an anticipated break in occlusion, such as when using dual linear pedal control on either the Stellaris Vision Enhancement System (Bausch + Lomb, Rochester, NY) or the Whitestar Signature System with Fusion Fluidics (Abbott Medical Optics Inc., Santa Ana, CA). Another method is to use a flow restrictor such as the Intrepid Fluid Management System (small-bore, low-compliance aspiration line; Alcon Laboratories, Inc., Fort Worth, TX) or the Vacuum Surge Suppressor designed by Alex Urich. A third option is to raise the bottle height. The last method is probably ill advised in eyes with possible zonular compromise, due to an increased risk of aqueous dissection into the vitreous as well as excessive deepening of the chamber. In order to further reduce the chance that turbulence will cause or exacerbate vitreous prolapse through compromised zonules, the surgeon can use the soft shell technique of Steve Arshinoff, MD, in which a "shell" of dispersive OVD provides a barrier at the level of the anterior capsule and zonules.[2]

In addition to the preceding fluidic adaptations, ultrasonic power modulations can reduce turbulence as well as the total amount of irrigating solution used. The key is to maximize the followability of nuclear fragments and decrease chatter or repulsion at the phaco tip. Nonaxial ultrasonic modalities like Ozil (Alcon Laboratories, Inc.) or Ellips Transversal (Abbott Medical Optics Inc.) are designed to enhance followability by reducing the axial component of ultrasound that can push nuclear particles away from the phaco tip. Much the same effect may be achieved with traditional longitudinal ultrasound by means of the hyperpulse mode available on most phaco platforms, as elegantly illustrated in the ASCRS award-winning videos by Teruyuki Miyoshi. Surgeons should avoid traditional, "nonhyperpulse" phacoemulsification in traumatic cataract cases.

Using occlusion-intensive (eg, chopping) more than sculpting (eg, quadranting) methods further decreases turbulence and fluid turnover. With regard to chopping, horizontal methods (eg, Nagahara) may have advantages over vertical methods (eg, Fukasaku, Pfiefer, Dillman) in that less vacuum is generally needed in the former. In horizontal methods, the nucleus is mechanically fixated between the chopping instrument and the phaco tip, whereas in vertical methods, the forces are at right angles, which requires higher vacuum for stabilization. As discussed previously, the higher vacuum level can be a particular liability in cases of traumatic cataract due to the higher propensity for surge and momentary peak turbulence in the anterior chamber. Chopping techniques also have a general advantage over quadranting/cracking methods in that force is directed more centrally than peripherally, resulting in less capsular/zonular stress—an important distinction in traumatized eyes that may already have a compromised capsule or zonules.

Should vitreous prolapse occur, pumping action should cease; the surgeon should raise the foot pedal to position 1 and then inject an OVD into the anterior chamber while transitioning to position 0 and then withdrawing the phaco tip. He or she can then use additional viscoelastic (preferably a dispersive OVD and/or the soft shell technique) to help tamponade the majority of vitreous, especially in the eye of a young patient with a relatively intact vitreous face.

After hydrating the main cataract incision to promote its seal, the surgeon makes an additional paracentesis or pars plana incision in order to facilitate bimanual anterior vitrectomy. He or she generally uses an appropriately lower bottle height, vacuum level, and aspiration outflow rate than during phacoemulsification. The cutting rate is set at maximum during removal of the vitreous but may need to be reduced later for residual lens material. Coaxial vitrectomy is fluidically inefficient and should be avoided. Lower settings result in slower, gentler currents within the anterior chamber that are less likely to displace vitreous anteriorly. Visualization of the vitreous may be augmented by staining with Triesence (Alcon Laboratories, Inc.) or

Kenalog (Bristol-Myers Squibb Co., Princeton, NJ), as described by Scott Burk, MD, PhD, of the Cincinnati Eye Institute.[3]

NEW TECHNOLOGY

The discussion thus far has dealt with the application of current equipment and instrumentation relative to phacodynamic manipulation designed to minimize mechanical and fluidic perturbations that might be excessive for ocular tissues weakened by prior trauma.

In the near future, however, cataract surgeons' choices will be considerably expanded by the advent of femtosecond laser technology, as being implemented by LensAR, Inc. (Winter Park, FL), LenSx Lasers, Inc. (Aliso Viejo, Ca), and Optimedica Corporation (Santa Clara, CA). For example, the capsulorhexis can be created almost entirely by this laser technology with essentially no induced zonular stress, in addition to the greater precision and, possibly, strength afforded by this modality. Similarly, this technology can pretreat the crystalline lens with softening and/or prechopping algorithms so as to effectively decrease the mechanical and ultrasounic forces required, again reducing the collateral force exerted on already compromised tissues secondary to trauma. This femtosecond laser technology can also produce a precise corneal incision that might afford better intraoperative chamber stability as well as postoperative wound integrity. It could thus mitigate the problem of traumatized corneal tissue that might not seal as well with current mechanical blade methodology.

CONCLUSION

Phacodynamics provides a context for ophthalmologists' customization of phaco machine settings and surgical techniques in order to achieve uniform outcomes. Gentleness and safety are a goal in all cataract cases, but traumatized eyes have less tolerance for intraocular perturbations. With a thorough preoperative evaluation for potential high-risk factors and the application of appropriate machine settings and technical modifications, surgeons can decrease the complication rate in these complex cases nearly to the low level associated with routine cataract procedures.

The LenSx laser has 510(k) clearance for the formation of a capsulorhexis. Femtosecond lasers are under investigation for conditioning the cataract lens and creating the cataract incision.

Barry S. Seibel, MD, is in private practice in Beverly Hills, California, and is a clinical assistant professor of ophthalmology at the UCLA David Geffen School of Medicine. He receives royalties from Slack Incorporated, and he is a member of the medical advisory board for and holds stock options in Optimedica Corporation. Dr. Seibel may be reached at (310) 444-1134; eyedoc2020@earthlink.net.

1. Seibel BS. *Phacodynamics: Mastering the Tools and Techniques of Phacoemulsification Surgery*. 4th ed. Thorofare, NJ: Slack Inc.; 2005.
2. Arshinoff SA. Dispersive-cohesive viscoelastic soft shell technique. *J Cataract Refract Surg*. 1999;25(2):167-173.
3. Burk SE, Da Mata AP, Snyder ME, et al. Visualizing vitreous using Kenalog suspension. *J Cataract Refract Surg*. 2003;29(4):645-651.

Surgical management.

By Robert J. Cionni, MD

Trauma is not an uncommon cause of cataract formation. Unfortunately, traumatic cataracts can be quite difficult to manage. Some of the challenges can include poor visibility through a traumatized cornea; iris disruptions, including iridodialysis or damage to the iris sphincter resulting in fixed mydriasis; zonular dialysis with lens subluxation; and/or capsular rupture. In cases of trauma severe enough to induce a cataract, there is an elevated risk for retinal damage and the development of glaucoma. In order to manage a traumatic cataract, the surgeon must first determine the extent and nature of the damage. A thorough examination will help to elucidate the challenges ahead, the likelihood of the patient's visual recovery, and the best timing for intervention. These findings and the uncertain prognosis must be clearly conveyed to the patient.

SURGERY WITH EVIDENCE OF CAPSULAR RUPTURE

The presence of lenticular debris in the anterior chamber provides conclusive evidence of anterior capsular rupture, and it is typically followed by the rapid development of a white intumescent cataract. This type of cataract is best managed with a high-viscosity ophthalmic viscosurgical device (OVD) to maintain a deep anterior chamber and prevent further rupture of the capsular bag. Staining the capsule with trypan blue will improve visualization for creation of the capsulorhexis. Hydrodissection is inadvisable, because it may enlarge the already present tear. Small self-sealing incisions help to prevent the chamber's collapse that will encourage expansion of the tear or vitreous prolapse, if the zonules or posterior capsule become compromised. After evacuating the nucleus and cortex, the surgeon will be better able to visualize the size and location of the capsular rupture, information that will dictate the best option for the IOL's placement.

MANAGEMENT OF ZONULAR RUPTURE

Trauma-induced zonular rupture is known to carry an increased risk of complications and, as a result, poorer outcomes. Newer surgical techniques and devices, however, have improved surgeons' ability to manage these cases. Small incisions enhance control of the intraocular environment, and vitreous-cutting devices on some anterior segment phaco platforms can now reach speeds of up to thousands of cuts per minute. The ophthalmologist's ability to suture a PCIOL into the ciliary sulcus or to the posterior aspect of the iris provides yet more options.[1] The growing popularity of iris hooks for stabilization of the intraoperative bag as well as the increasing use of capsular tension rings (CTRs), modified CTRs (Cionni Rings for Sclera Fixation; Morcher GmbH, Stuttgart, Germany; distributed in the United States by FCI Ophthalmics, Inc., Marshfield Hills, MA), and capsular tension segments (CTS) facilitates the implantation of a PCIOL in the capsular bag.[2-8]

The introduction of CTRs markedly improved surgeons' ability to manage zonular compromise. These devices can be inserted into the capsular bag at any point after completion of the capsulorhexis, as long as the anterior and posterior capsules are intact. The effect is a dramatic expansion and stabilization of the capsular bag. The placement of a CTR, however, may not adequately stabilize or center the capsular bag in eyes with profound zonular compromise or lens subluxation. The Cionni CTR allows scleral fixation without violating the integrity of the capsular bag (Figure 1). The Ahmed CTS (Morcher GmbH; distributed in the United States by FCI Ophthalmics, Inc.) is a shortened version of the Cionni CTR. A CTS can be used to stabilize a quadrant

of zonular compromise without expanding the capsular bag circumferentially. Thus, it may be possible to use the CTS even in the presence of a small capsular tear.

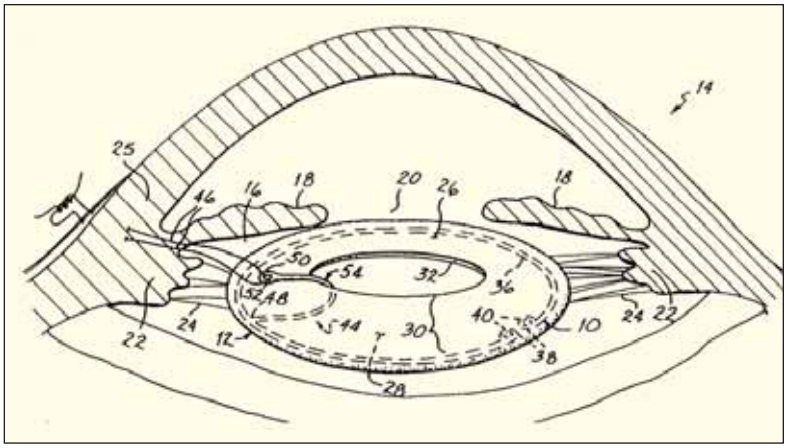

Figure 1. The Cionni Ring for Sclera Fixation, model I-L.

SURGERY WITH CTRs

The initial entry into the anterior chamber should be just large enough to permit the injection of a dispersive OVD to tamponade vitreous from anterior movement. The surgeon begins the continuous curvilinear capsulorhexis far from the area of greatest weakness by utilizing the countertraction provided by the remaining healthy zonules. A 5.5- to 6.0-mm capsulorhexis should allow the surgeon to manipulate the nucleus more easily, but it may be necessary to stop and place iris hooks for countertraction at intervals as the capsulorhexis proceeds. Although a standard or modified CTR can be placed immediately after the capsulorhexis, ophthalmologists who have considerable experience with these devices recommend placing them as late as possible in the procedure but as soon as they are needed.[9] Alternatives to the early placement of a standard or modified CTR are (1) to stabilize the capsular bag by engaging the capsulorhexis' edge with one to three disposable nylon iris retractors placed through limbal stab incisions or (2) to place a CTS to secure the bag with an iris hook or scleral suture. Often, by expanding the bag behind the lens nucleus with a dispersive OVD, the surgeon can obviate the need for any of these devices until the nucleus has been emulsified and removed. Thorough hydrodissection will maximally free the nucleus. If the epinucleus is soft enough, hydrodissection completely into the anterior chamber is advisable.

Phacoemulsification should be performed using low vacuum and aspiration settings to minimize the chamber's volatility.[10] Torsional phacoemulsification minimizes the "chatter" of lenticular material and thus decreases the risk of losing nuclear material through areas of missing zonules.[11] For a dense nucleus, a divide or chopping technique is preferable to minimize zonular stress during phacoemulsification, as long as the surgeon carefully applies equal forces in opposing directions to avoid displacing the nucleus. It is very helpful to viscodissect the nuclear halves or quadrants free from the cortex in areas of zonular weakness. An OVD injected between the nuclear quadrants and peripheral capsular bag will lift the nuclear fragments while expanding and stabilizing the bag.

Before inserting a standard or modified CTR, the surgeon should place some OVD just under the surface of the residual anterior capsular rim to create a space for the ring and to dissect residual cortex away from the peripheral capsule, thereby making cortical entrapment by the ring less likely. Henderson and Kim[12] devised a unique CTR device that may make trapped cortex easier to remove. The author's preferred technique for placing a Cionni Ring for Sclera Fixation was introduced by Michael Hater, MD, at the Cincinnati Eye Institute. The surgeon places a 9–0 Prolene (Ethicon Inc., Somerville, NJ) or 8–0 Gore-tex (W. L. Gore & Associates, Inc., Newark, DE) suture through the eyelet of the fixation hook before inserting the ring into the capsular bag. The Cionni CTR is inserted with a smooth forceps through the main incision and dialed into the capsular bag with a Y-hook. The fixation hook typically "captures" anterior to the capsulorhexis' edge. If it does not, the hook is easily manipulated above the capsular bag with two dull instruments. The surgeon then dials the Cionni CTR's fixation hook to the center of the zonular dialysis to center the bag. He or she uses a 23-gauge microvitreoretinal blade to fashion two scleral incisions, 2 to 3 mm posterior to the limbus and about 2 mm apart. The 25-gauge retinal forceps is placed through the sclerotomy sites, and the sutures are grasped and externalized. The suture is tightened to the point of the bag's centration and tied. The surgeon then rotates the knot through the sclerotomy sites. It is not necessary to suture the sclerotomies unless there is fluid leakage.

After the CTR's placement or suture fixation of the Cionni CTR, the surgeon can aspirate any remaining cortex and reinflate the capsular bag with a cohesive OVD before inserting the PCIOL. The author has found it easiest to insert a foldable, single-piece, acrylic PCIOL into the capsular bag in these cases.

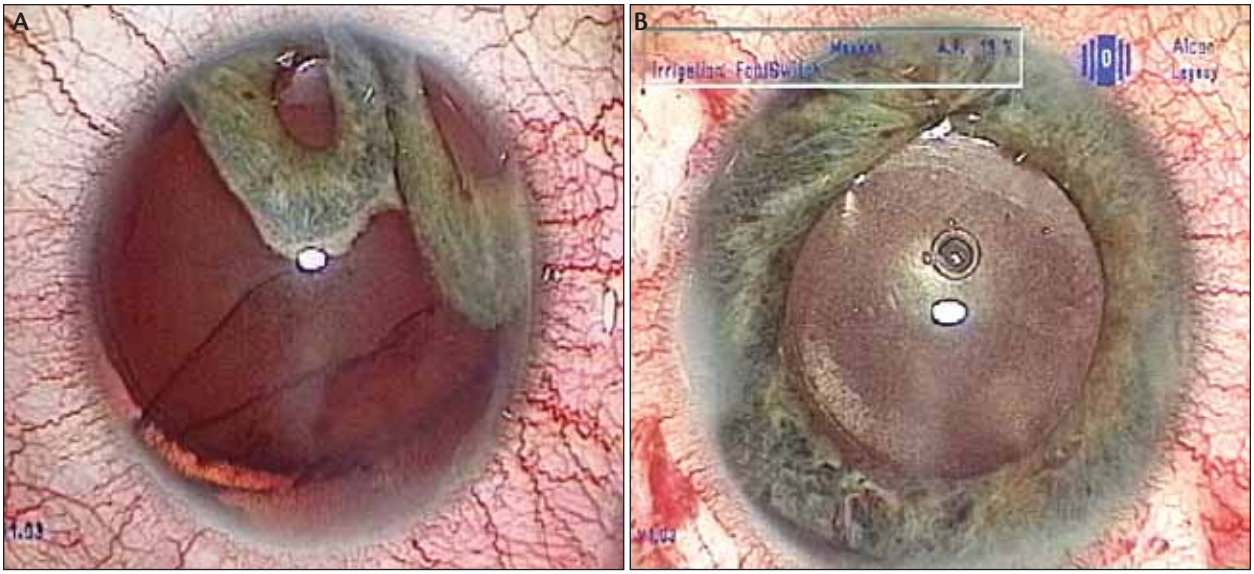

Figure 2. A nearly complete iridodialysis caused by the deployment of an airbag (A). The placement of multiple 10–0 Prolene mattress sutures allows the repair of the massive iridodialysis (B).

It is not desirable to attempt to remove all of the OVD, as doing so will encourage vitreous prolapse late in the procedure. Likewise, whenever exiting the chamber, the surgeon should always provide infusion through the sideport incision to prevent the chamber's collapse. If vitreous presents at any time during the procedure, it should be carefully and completely removed from the anterior chamber. The author prefers a pars plana approach and the use of triamcinolone staining to ensure that the anterior chamber is free of vitreous. Finally, the surgeon instills acetylcholine at the end of the case to ensure that the pupil is round, which further confirms that the anterior chamber is free of vitreous.

IRIS DAMAGE

Often, the traumatic cataract is accompanied by significant damage to the iris, including iridodialysis and traumatic mydriasis (Figure 2). Although some patients will tolerate fixed mydriasis, glare from the edge of the IOL may be quite significant. Typically, the author's preference is to cinch the pupil to a size slightly smaller than the optic via multiple Siepser-style suture passes near the pupil's margins or with iris cerclage. A small superior iridodialysis may not require repair, because the upper eyelid often hides the defect and protects the eye from stray light. Larger defects are quite easily repaired with a double-armed 10–0 or 9–0 Prolene suture passed and tied in a mattress fashion. The knot should be rotated and buried to prevent its erosion through the conjunctiva.

CONCLUSION

Traumatic cataracts can be quite challenging to manage, but newer surgical techniques and devices augment the chances of a good outcome. An understanding of the nature and extent of the damage and careful planning prior to surgery are imperative to the proper management of these challenging cases. ■

Robert J. Cionni, MD, is the medical director of The Eye Institute of Utah and an adjunct professor at the Moran Eye Center of the University of Utah in Salt Lake City. He is a consultant to Alcon Laboratories, Inc., and holds a financial interest in the Cionni Rings for Sclera Fixation. Dr. Cionni may be reached at (801) 266-2283.

1. Gimbel HV, Condon GP, Kohnen T, et al. Late in-the-bag intraocular lens dislocation: incidence, prevention, and management. *J Cataract Refract Surg*. 2005;31:2193-2204.
2. Cionni RJ, Osher RH. Endocapsular ring approach to the subluxed cataractous lens. *J Cataract Refract Surg*. 1995;21:245-249.
3. Cionni RJ, Osher RH. Management of profound zonular dialysis or weakness with a new endocapsular ring designed for scleral fixation. *J Cataract Refract Surg*. 1998;24:1299-1306.
4. Cionni RJ, Osher RH, Marques DM, et al. Modified capsular tension ring for patients with congenital loss of zonular support. *J Cataract Refract Surg*. 2003;29:1668-1673.
5. Hasanee K, Butler M, Ahmed, II. Capsular tension rings and related devices: current concepts. *Curr Opin Ophthalmol*. 2006;17:31-41.
6. Hara T, Yamada Y. "Equator ring" for maintenance of the completely circular contour of the capsular bag equator after cataract removal. *Ophthalmic Surg*. 1991;22:358-359.
7. Nagamoto T, Bissen-Miyajima H. A ring to support the capsular bag after continuous curvilinear capsulorhexis. *J Cataract Refract Surg*. 1994;20:417-420.
8. Legler U, Witschel B. The capsular ring: a new device for complicated cataract surgery. Film presented at: ASCRS Symposium on Cataract, IOL and Refractive Surgery; May 1993; Seattle, Washington.
9. Ahmed, II, Cionni RJ, Kranemann C, Crandall AS. Optimal timing of capsular tension ring implantation: Miyake-Apple video analysis. *J Cataract Refract Surg*. 2005;31:1809-1813.
10. Osher RH. Slow motion phacoemulsification approach. *J Cataract Refract Surg*. 1993;19:667.
11. Cionni R. Comparison of nuclear material chatter: longitudinal versus torsional phacoemulsification. Paper presented at: The ASCRS Symposium on Cataract, IOL and Refractive Surgery; April 30, 2007; San Diego, CA
12. Henderson BA, Kim JY. Modified capsular tension ring for cortical removal after implantation. *J Cataract Refract Surg*. 2007;33:1688-1690.