Point/Counterpoint: The Pentacam Ve

The Pentacam's rotating imaging provides a more accurate picture of the cornea.

BY MICHAEL W. BELIN, MD

It was not long ago that discussions concerned whether topography were mandatory for the preoperative evaluation of the refractive surgery candidate. Currently, topographic measurements are recognized as an indispensable part of every such evaluation.

We as ophthalmologists were taught not to pay much attention to the posterior surface, because it is less important as a refractive surface and, in the past, the information about it was unreliable.

For refractive surgery screening, however, the posterior corneal surface is just as important as the anterior surface and probably serves as a more subtle or early indicator of potential pathology.

ELEVATION- VERSUS PLACIDO-BASED TOPOGRAPHY

Although elevation-based topography was available as far back as 1989, placido-based anterior curvature analysis quickly became the norm. Placido-based technology was more intuitive for general refractive surgeons, because we are used to thinking in terms of diopters and curvature. This technology measured slope and presented the data in a more customary curvature map. The systems were relatively inexpensive and relied on the digitalization of a placido image.

Placido-based analysis, however, has many inherent limitations, including a reliance on the analysis of a reflected image with no data available about the cornea's posterior surface or thickness. Because the posterior corneal surface contributes minimally to the cornea's overall refractive effect, ophthalmologists erroneously assumed that data from this part of the cornea were not very useful. It is now clear that refractive effect and structural integrity are two different properties, and we recognize the importance of accurately assessing the posterior corneal surface. Additionally, curvature analysis has certain inherent limitations.

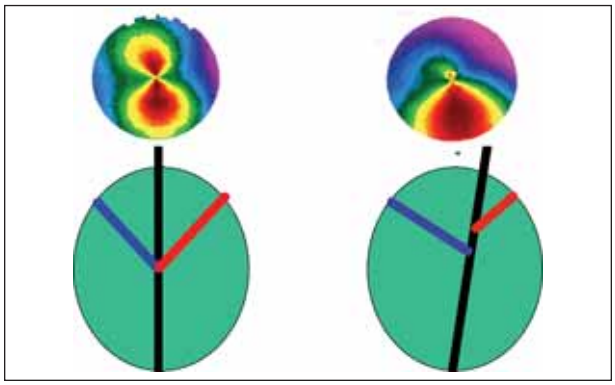

Figure 1. Two objects with the same shape can have different curvature maps if the reference axis (imaging axis) is different. Most patients do no look through the geometric center of their cornea, and the reference axis can change postoperatively.

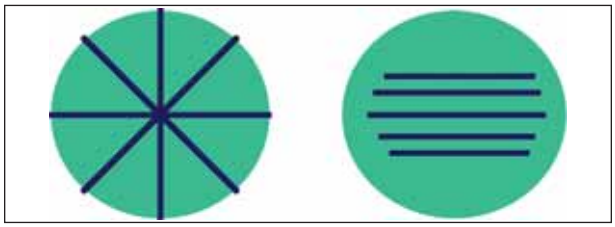

Figure 2. Pictured is a schematic representation of the rotating imaging used by the Pentacam (left) and the slit imaging used by the Orbscan (right). The optical slices used by the Pentacam share a common point, allowing for more accurate image registration.

Curvature is a reference-based measurement, meaning that the same corneal shape can have many different curvature maps (Figure 1). As a result, ophthalmologists relying on this information have misdiagnosed (or overdiagnosed) forme fruste keratoconus.

(Continued on page 82)

ersus the Orbscan

The Orbscan topographer offers practitioners a complete assessment of a patient's corneal surface.

BY JOHN A. VUKICH, MD

Corneal topography is an essential part of the preoperative evaluation of a refractive surgery patient, and it has become the cornerstone of our assessment of the cornea. The introduction of the Orbscan topographer (Bausch & Lomb, Rochester, NY) provided clinicians with the opportunity to visualize the cornea in three dimensions, thus allowing a more thorough assessment than anterior-surface placido's image topographers. Visualizing the posterior corneal contour as well as a limbus-to-limbus pachymetric map of the cornea provides a more comprehensive set of parameters by which we can characterize the surface of the eye.

EVALUATION OF CORNEAL ABNORMALITIES

Orbscan IIz

The Orbscan IIz (Bausch & Lomb) provides clinicians with a greater understanding of the cornea than anterior-surface placido-derived topography. This knowledge is important to the assessment of corneal dystrophies such as keratoconus. It is also necessary to the identification of any atypical features that may place a candidate at an increased risk of ectasia following refractive surgery. The Orbscan IIz acquires 9,000 data points in 1.5 seconds to make a detailed map of the entire corneal surface (11mm), and it allows for the analysis of elevation and curvature measurements on both the anterior and posterior surfaces of the cornea. Furthermore, this diagnostic system is capable of detecting and analyzing posterior corneal abnormalities where anomalies such as keratoconus can first appear.

The Orbscan IIz may help explain the reasons for a patient's decreased visual acuity postoperatively. Additionally, it may improve surgeons' accuracy in prescribing follow-up treatments for LASIK as well as other forms of eye surgery.[1]

Pentacam

The utility of the information generated by the Orbscan IIz has inspired the development of other devices that provide comparable data. The Pentacam (Oculus, Inc., Lynnwood, WA), which has been available in the US for more than 1 year, provides similar measurements of the cornea and anterior chamber as the Orbscan IIz. The Pentacam's rotating Scheimpflug camera takes multiple images of the anterior segment. The system then generates three-dimensional images and calculates measurements of the eye. The measuring process lasts about 2 seconds. Approximately 25,000 data points are sampled to generate the corneal analysis.

SYSTEMS' SHORTCOMINGS

It is inevitable that comparisons of the two devices will be made, because they both provide essentially the same examination of the anterior segment using optical analysis. Topographic analysis of the cornea's front and back surfaces using both the Orbscan IIz and the Pentacam is based on the true elevation measurement from limbus to limbus compared to a derived reference surface. The shortcomings of the Orbscan IIz topographer have been well documented.[2,3] Although preoperative pachymetry is repeatable and correlates well with ultrasound, the Orbscan IIz's measurements of the central corneal thickness after myopic LASIK are less than those measured by ultrasonic pachymetry.[3] This difference decreases with time and may not be significant after 1 year.[3] Edge-detection algorithms that are the heart of the slit-lamp–based Orbscan IIz system are vulnerable to interference from artifacts introduced by the corneal reshaping. The Orbscan IIz in particular exaggerates the posterior corneal surface's contour, and clinicians must be careful to avoid an overinterpretation of this topographic analysis for several months following refractive surgery.

I was initially attracted to the Pentacam by the promise of

(Continued on page 84)

(Continued from page 80)

Elevation-based systems were first reported to have benefits over placido-based systems in 1991.[1] The first unit, the PAR corneal topography system (PAR Technology, New Hartford, NY), used a technique based on rasterphotogrammetry and analyzed the distortion of a grid pattern when projected onto the corneal surface. The PAR corneal topography system had many advantages over placido-based systems in that it did not require a smooth corneal surface and it directly measured surface elevation, but it still could analyze only the anterior corneal surface.

Currently, elevation-based topography systems utilize some form of optical cross sectioning. They measure both the anterior and posterior surfaces, and they compute a complete corneal pachymetric map. In spite of this additional information, many physicians still rely on placido-based anterior curvature analysis. The advantages of a complete and accurate corneal analysis follow.

THE PENTACAM'S ADVANTAGES

The major benefit of the Pentacam (Oculus, Inc., Lynnwood, WA) is that it accurately measures both the anterior and posterior corneal surfaces pre- and postoperatively.[2] Earlier technology such as the Orbscan topographer (Bausch & Lomb, Rochester, NY) was incapable of imaging the postoperative cornea accurately, which limited the unit's use as a diagnostic instrument. The Orbscan fails to correctly identify the postoperative posterior corneal surface and routinely locates the surface too anteriorly. As a result, its pachymetry reading is too thin, and its topography suggests ectasia. The inability of the Orbscan to identify the posterior corneal surface on post-LASIK eyes promoted the false beliefs that changes to that surface were commonplace after LASIK and that most patients exhibited subclinical ectasia.[3-6]

The Pentacam uses a rotating Scheimpflug camera to take optical cross sections of the anterior segment. The Orbscan uses a series of horizontal slit images. Two things are necessary to accurately reconstruct the corneal surface. First, the topographer needs to precisely detect both the anterior and posterior corneal surfaces. Second, it must be able to register each optical slice against the others (Figure 2).

The Pentacam's rotating imaging technique has inherent advantages as each optical cross section shares a common point (center of rotation), which makes image registration easier and more reliable. Serial slices used by the Orbscan share no common data point, so image reconstruction is difficult and less reliable; it is like trying to put a puzzle

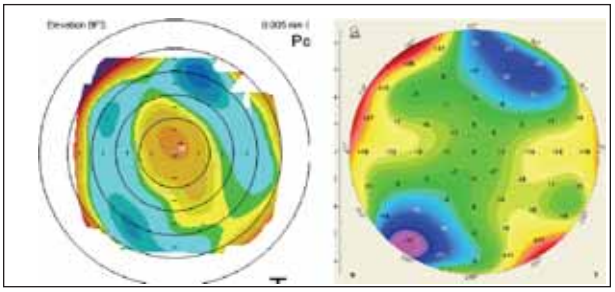

Figure 3. These Orbscan (left) and Pentacam (right) images are of the posterior corneal surface of an eye with a buttonhole flap but no ablation. The Orbscan erroneously indicates an ectatic surface due to the minimal overlying haze induced by the flap. The Pentacam displays a completely normal posterior surface, as expected, because no ablations were created centrally.

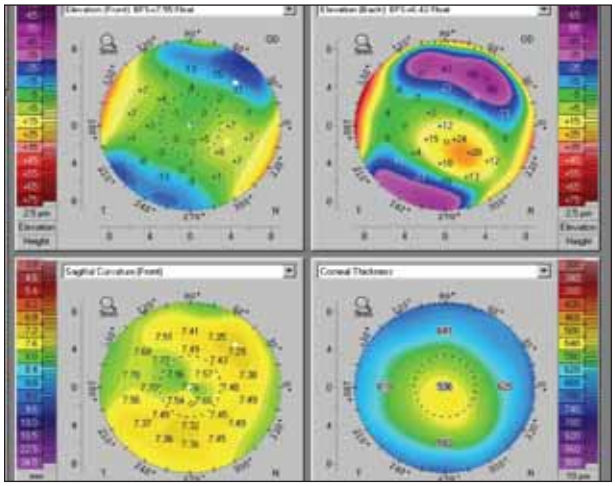

Figure 4. Although the anterior curvature and elevation are normal in this Pentacam image of a refractive surgery candidate, the posterior elevation is distinctly abnormal in the form of an island of positive elevation. This finding is associated with a slight displacement of the thinnest region of the cornea toward the posterior elevation.

together (Orbscan) and being told one may not start with adjoining pieces.

The addition of the placido image to augment the Orbscan's elevation system was necessary because of the difficulty of achieving proper image registration and/or data accuracy. Normally, if the elevation data were accurate, there would be no need for a supplementary placido image, because curvature is simply the second derivative of elevation. Unfortunately, the placido image with the

Orbscan offers no assistance in identifying or measuring the posterior cor-neal surface. It is the accuracy of the raw elevation data that determines a machine's clinical applicability. In other words, the placido image is a reflected image. There is no placido image on the posterior surface. It is like trying to look at your back while you stand in front of a mirror. It cannot happen.

The Pentacam correctly measures the anterior and posterior corneal surfaces and computes full pachymetric data for both the pre- and postoperative cornea. Its ability to perform this measurement does not appear to be affected by previous surgery, haze, or superficial scarring.[7-9]

The Orbscan incorrectly locates the posterior surface more anteriorly and subsequently underestimates the residual bed's thickness. The result is an erroneous diagnosis of post-LASIK ectasia in almost all cases[5] (Figure 3). Ultimately, it is the accuracy of the raw elevation data that will determine not only the diagnostic ability but potential clinical therapeutic applications. Although wavefront-guided ablations can minimize the aberrations induced in normal eyes during refractive surgery, their use in pathologic corneas is limited. Topography-guided ablations hold more promise for these eyes. Currently, the Allegretto Wave excimer laser (Wavelight AG, Erlangen, Germany) uses data from the Pentacam in its topography-guided ablation programs.

OBTAINING A TOPOGRAPHER

Physicians have been somewhat reluctant to abandon their older topographers for practical and financial reasons. In most areas in the US, topography is not reimbursable as a separate procedure. Moreover, the original elevation systems did not provide an accurate picture of the posterior corneal surface or full, precise pachymetric data. As a result, many ophthalmologists incorrectly concluded that this information was not significant. Changes on the posterior corneal surface are critical and are often the first indicators for future ectatic disease, even when the anterior curvature is completely normal (Figure 4). ■

Michael W. Belin, MD, is Professor and Director of Cornea & Refractive Surgery at Albany Medical College in New York. He serves as a consultant to Oculus, Inc. Dr. Belin may be reached at (518) 475-1515.

1. Litoff D, Belin MW, Winn SS, Smith RS. PAR Technology Corneal Topography System. *Invest Ophthalmol Vis Sci*. 1991;32(suppl):992.
2. Ciolino J, Belin MW. Changes to the posterior cornea after LASIK and PRK. *J Cataract Refract Surg*. 2006;32:1426-1431.
3. Charkrabarti HS, Craig JP, Brahma A, et al. Comparison of corneal thickness measurements using ultrasound and Orbscan slit-scanning topography in normal and post-LASIK eyes. *J Cataract Refract Surg*. 2001;27:1823-1828.
4. Giessler S, Duncker GIW. Orbscan pachymetry after LASIK is not reliable [letter]. *J Refract Surg*. 2001;17:385-387.
5. Cairns G, Ormonde SE, Gray T, et al. Assessing the accuracy of Orbscan II post-LASIK: apparent keratectasia is paradoxically associated with anterior chamber depth reduction in successful procedures. *Clin Experiment Ophthalmol*. 2005;33:147-152.
6. Cains G, McGhee CNJ. Orbscan computerized topography: attributes, applications, and limitations. *J Cataract Refract Surg*. 2005; 31:205-220.
7. Belin MW, Ciolino J. Measurement of posterior elevation changes after LASIK with Scheimpflug imaging. Paper presented at: The ESCRS Mid-Winter Meeting; February 10, 2006; Monte Carlo, Monaco.
8. Belin MW. Evaluating the posterior corneal surface. Paper presented at: The ISRS/AAO 2005 Refractive Surgery Subspecialty Day; October 14, 2005; Chicago, IL.
9. Ciolino J. Changes to the corneal surface after LASIK and PRK. Federated Cornea Societies 2005 Annual Meeting, Chicago, IL.

(Continued from page 81)

improved accuracy and better functional analysis of the postoperative refractive surgery patient than what is currently obtained from the Orbscan IIz. Unfortunately, the Pentacam has dissatisfied me in several key areas. Most disappointing is the built-in screening algorithm intended to create an index of suspicion of corneal irregularity. In my opinion, this feature routinely overcalls the presence of keratoconus, leaving an unwelcome note in the medical chart. In my experience, corneal thickness as reported by the Pentacam in preoperative patients is commonly less than what ultrasonic pachymetry or the Orbscan IIz measures, a discrepancy leading to conflicting information on minimal residual corneal thickness.

CONCLUSION

As with most high-tech electronic equipment, the Orbscan IIz as well as the Pentacam offer multiple features that are largely unused by the consumer. For instance, the Orbscan IIz topographer has three-dimensional maps, comparison subtraction analysis, and screening tools that I rarely use for routine patient care. I assume I represent the majority of practitioners, who look for simplicity, ease of interpretation, and reliability. In this regard, the Orbscan IIz system excels.

Having employed both systems for the last year, I have concluded that I find topographers most useful during the analysis of preoperative candidates for refractive surgery. For daily use in a busy clinic, the Orbscan IIz remains the workhorse of my refractive surgery evaluation. The unit is easy to use, even for entry-level technicians. The images it produces are clear and graphically superior to the Pentacam's, and they provide a quick-glance capability for screening patients. ■

John A. Vukich, MD, is Assistant Clinical Professor at the University of Wisconsin, Madison. He acknowledged no financial interest in the products mentioned herein. Dr. Vukich may be reached at (608) 282-2002; javukich@facstaff.wisc.edu.

1. Nawa Y, Masuda K, Ueda T, et al. Evaluation of apparent ectasia of the posterior surface of the cornea after keratorefractive surgery. *J Cataract Refract Surg*. 2005;31:571-573.
2. Cairns G, Ormonde SE, Gray T, et al. Assessing the accuracy of Orbscan II post-LASIK: apparent keratectasia is paradoxically associated with anterior chamber depth reduction in successful procedures. *Clin Exp Ophthalmology*. 2005;33:147-152.
3. Cairns, G, McGhee CN, Collins MJ, et al. Accuracy of Orbscan II slit-scanning elevation topography. *J Cataract Refract Surg*. 2002;28:2181-2187.