Refractive Penetrating Keratoplasty

A corneal surgeon puts his femtosecond laser to therapeutic use, thus achieving faster visual recovery and less induced astigmatism than with conventional techniques.

BY ROGER F. STEINERT, MD

The femtosecond laser was first proposed for penetrating keratoplasty (PKP) trephination about 5 years ago. Since then, the procedure has been tested extensively in the laboratory, and over time, the parameters have been refined enough to make femtosecond keratoplasty viable in a clinical setting. In my colleagues' and my clinic, it has now almost entirely replaced conventional PKP for patients who need a full-thickness transplant. We are studying femtosecond applications for other types of corneal transplantation as well (see *Other Forays Into Femto-Transplantation*).

Femtosecond lasers cut tissue cleanly and precisely without burning, ablating, or affecting adjacent tissue. That capability explains a femtosecond laser's success in the dissection of the lamellar flap in laser refractive surgery, but the technology has always been attractive for therapeutic corneal applications as well.

EXPERIMENTS IN SHAPE

The biggest advantage of the femtosecond laser over traditional trephination is that the laser can be programmed to cut a nearly infinite variety of possible shapes—those that we can precisely duplicate on both donor and host corneas.

With experience, the shapes of our incisions have evolved considerably. A top hat configuration, with a broad anterior portion like the brim of a hat and a narrower stovepipe posterior portion, was initially thought to be the most stable.[1,2] Despite some good early clinical results,[3] this configuration did not inherently keep the donor button in the correct position. With the realization that tight suturing would be necessary, we began looking at other alternatives.

Guided by anterior segment optical coherence tomography, I developed a double-angled, zig-zag incision (Figure 1) that seems to offer considerable advantages.[4] The angled edge creates a hermetically sealed wound and provides a smooth transition between the host and donor tissue (Figure 2). The greater surface area in the incision translates into improved wound healing, and the sutures do not need to be as tight as with a traditional or top hat incisions. The reduced tension of the suture promotes faster visual recovery with less induced astigmatism.

TECHNIQUE

For PKP, I make the corneal incisions with an IntraLase FS laser (Abbott Medical Optics Inc., Santa Ana, CA) that has

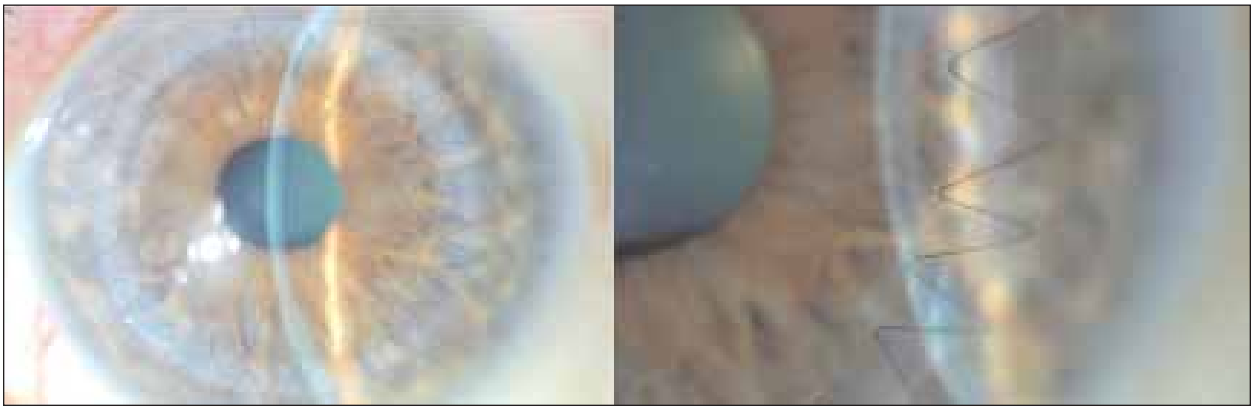

Figure 1. Postoperative appearance of femtosecond zig-zag penetrating keratoplasty with the IntraLase FS laser.

been modified to cut at greater depths than the system will allow for LASIK flaps. I am not aware of transplantation procedures that have been successfully performed with any other commercially available femtosecond laser.

Surgeons can prepare their own donor buttons using the IntraLase and an artificial anterior chamber or order them precut to exact specifications from an eye bank that has a femtosecond laser. Working with our eye bank, my colleagues and I have identified a matrix of standard sizes and shapes that we can order quickly, all with the zig-zag incision. The cut tissue is guaranteed to match the host, because both lasers use the same specifications. Manually, we could never achieve matched dissections of this complexity.

We use a 0.5-mm wide lamellar ring cut that is 300 µm deep and at 45° angles after the release of applanation. Both the host and donor buttons are the same size.

We also have the laser add superficial positioning marks on both the donor and host tissue to help align them and guide suturing. This technique facilitates a more consistent suture pattern, with more evenly distributed tension forces that may be especially helpful in a running-suture technique.

OTHER FORAYS INTO FEMTO-TRANSPLANTATION

Although the greatest body of experience is with full-thickness keratoplasty, femtosecond lasers are being studied for other keratoplasty indications.

ANTERIOR LAMELLAR KERATOPLASTY

A femtosecond laser is ideal for making a precise planar dissection for anterior lamellar keratoplasy. Yoo et al[1] reported on a case series in which the donor buttons were kept in place with bandage contact lenses, without any sutures, much like a free LASIK cap. The technique is promising, although visual acuity remains a challenge, as with all anterior lamellar procedures.

DEEP ANTERIOR LAMELLAR KERATOPLASTY

Recently, my colleague Marjan Farid, MD, developed an IntraLase-enabled (Abbott Medical Optics Inc., Santa Ana, CA) big-bubble technique for deep anterior lamellar keratoplasty using a zig-zag incision,[2] which is made into the deep stroma, 70 µm less than full thickness. The incision serves as a guide for placing the bubble, thus greatly reducing the risk of an inadvertently perforated Descemet's membrane or a needle placed too superficially for the big bubble to work. After the femto-incision (Figure 1A), the patient can be transported to the OR for bubble placement (Figure 1B) and manual dissection of the last 70-µm bridge of tissue (Figure 1C).

When it works, this technique allows for retention of Descemet's membrane in keratoconic eyes with a healthy endothelium. If the surgeon ruptures Descemet's membrane, he or she can easily convert to a full-thickness graft with the same donor and still have the advantages of the zig-zag incision.

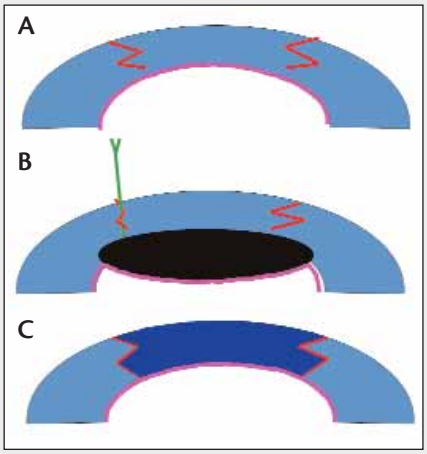

Figure 1. In zig-zag deep anterior lamellar keratoplasty, the femtosecond laser cuts to within 70 µm of full thickness (A). Then, the bubble is injected (B). The remainder of the dissection is easily performed manually in the operating suite (C).

DEEP LAMELLAR OR DESCEMET'S STRIPPING ENDOTHELIAL KERATOPLASTY

Terry et al[3] evaluated the feasibility of the femtosecond laser for deep lamellar endothelial keratoplasty (DLEK) and found that the DLEK dissections can be performed with the IntraLase FS laser. DLEK has since been overtaken, however, by a better procedure, Descemet's stripping endothelial keratoplasty (DSEK). Although there have been some reports of DSEK with a femtosecond laser,[4] they have not yet been tested in a clinical setting and may not be able to achieve results better than the current methods for DSEK that do not use a laser.

It is an exciting time in the evolution of keratoplasty applications for the femtosecond laser, with many advances yet to come.

1. Yoo SH, Kymionis GD, Koreishi A, et al. Femtosecond laser-assisted sutureless anterior lamellar keratoplasty. Ophthalmology. 2008;115(8):1303-1307.
2. Farid M, Kim M, Steinert RF. Results of penetrating keratoplasty performed with a femtosecond laser zig-zag incision: initial report. Ophthalmology. 2007;114(12):2208-2212.
3. Terry MA, Ousley PJ, Will B. A practical femtosecond laser procedure for DLEK endothelial transplantation: cadaver eye histology and topography. Cornea. 2005;24(4):453-459.
4. Cheng YY, Hendrikse F, Pels E, et al. Preliminary results of femtosecond laser-assisted Descemet's stripping endothelial keratoplasty. Arch Ophthalmol. 2008;126(10):1351-1356.



Figure 2. The angled edge of the incision provides a smooth transition between host and donor.

For now, we are still using 10–0 nylon sutures, which are intended to remain in place for several years. In the future, we may be able to remove sutures earlier or to identify advanced suturing materials or alternatives such as laser welding that may produce even better results.

RESULTS

We have compared our results with IntraLase-enabled zig-zag keratoplasty in 46 eyes of 40 patients with our outcomes using conventional PKP in 17 eyes of 14 patients. For the conventional PKP procedures, we used a Barron suction trephine. The donor button was blade-punched from the endothelial side and was oversized by 0.25 mm, except in cases of keratoconus, for which the graft was the same size as the host. There were no significant preoperative differences between the two treatment groups. Patients have been observed for 1 to 12 months thus far.

On average, femtosecond keratoplasty has resulted in at least 1.00 D less astigmatism than conventional PKP, which usually puts the cylinder within the range of tolerable spectacle correction. Most striking was the difference between the two groups in terms of the degree and speed of patients' visual recovery. By the third month after surgery, most of the femtosecond keratoplasty patients had a BCVA at least at the driver's license level, and almost half saw 20/25 or better. In contrast, fewer than one-third of the conventional group could see to drive, and none achieved 20/25 or better BSCVA. Faster visual recovery has important implications for patients' quality of life, because they are able to work and function normally much sooner after surgery.

We cannot say yet whether the final results after suture removal will be better in the femtosecond group, but they have been better than with conventional PKP at every stage of follow-up for the first 12 months.

CONCERNS AND COMPLICATIONS

We have not seen any new complications with femtosecond keratoplasty. In theory, a repeated loss of suction might force us to abort the procedure before completing the laser incision in the host tissue. It would then be very difficult to convert to a conventional PKP, because the donor and host tissue would not match. We have briefly lost suction, however, and had no difficulty completing the laser trephination.

Surgeons in Europe reported trouble with a few cases in which the cuts were made incorrectly (unpublished data). It is important to interrupt the cuts in a vertical direction. Because the cornea is a lamellar structure, an interrupted cut in the lamellar plane can spontaneously interconnect, which is exactly what happened in the European cases.

In our case series, there have been no instances of spontaneous dehiscence so far, and nothing suggests that we will have a higher graft failure rate than with conventional PKP. In some cases, the sutures have loosened as early as 6 weeks postoperatively, presumably due to an immunologic reaction to the nylon. The grafts have stayed in place nevertheless, which suggests that wound healing is strong and accelerated.

We have not yet performed any repeat grafts over a prior femtosecond incision. We have used the technique after conventional PKP, however, and have had no difficulty with the laser's cutting through the old, healed incision.

Femtosecond keratoplasty certainly takes more time and requires more expensive equipment than conventional PKP. Cost could be an impediment to the former procedure's widespread use, depending on the eventual reimbursement. We believe it is a much better procedure in terms of consistent, functional, postoperative vision, however, within 3 months of surgery. ■

Roger F. Steinert, MD, is a professor of ophthalmology, a professor of biomedical engineering, the director of the Gavin Herbert Eye Institute, and the chair of ophthalmology at the University of California in Irvine. He is a consultant to Abbott Medical Optics Inc. Dr. Steinert may be reached at (949) 824-8089; steinert@uci.edu.

1. Ignacio TS, Nguyen TB, Chuck RS, et al. Top hat wound configuration for penetrating keratoplasty using the femtosecond laser: a laboratory model. Cornea. 2006;25(3):336-340.
2. Bahar I, Kaiserman I, McAllum P, Rootman D. Femtosecond laser-assisted penetrating keratoplasty: stability evaluation of different wound configurations. Cornea. 2008;27(2):209-211.
3. Steinert RF, Ignacio TS, Sarayba MA. "Top hat"-shaped penetrating keratoplasty using the femtosecond laser. Am J Ophthalmol. 2007;143(4):689-691.
4. Farid M, Kim M, Steinert RF. Results of penetrating keratoplasty performed with a femtosecond laser zig-zag incision: initial report. Ophthalmology. 2007;114(12):2208-2212.