Haze and Irregular Astigmatism After PRK

BY ANTHONY KUO, MD; TERRY KIM, MD; RONALD R. KRUEGER, MD;
PARAG A. MAJMUDAR, MD; COL. SCOTT D. BARNES, MD; AND WILLIAM B. TRATTLER, MD

CASE PRESENTATION

A 37-year-old Indian male presents with myopic astigmatism. He requests refractive surgery. His examination is remarkable for corneal pachymetry readings of 488 µm OD and 495 µm OS. His manifest refraction is -6.50 +0.50 X 100 OD and -5.50 D OS. He has a BCVA of 20/15 OU (Figure 1). The rest of his examination is unremarkable, and the patient elects to undergo a transepithelial PRK, which is performed without incident. In total, the procedure removes 73 µm of tissue from his right eye and 62 µm of tissue from his left eye. The postoperative course includes medical treatment with a topical antibiotic for 2 weeks and FML 0.1% (Allergan, Inc., Irvine, CA) tapered over the course of 3 months. It is suggested to the patient that he take vitamin C 500 mg twice daily by mouth.

One month following surgery, the patient's UCVA is 20/20 OU, and his manifest refraction is -0.25 D OU. The patient is lost to follow-up after his 1-month appointment.

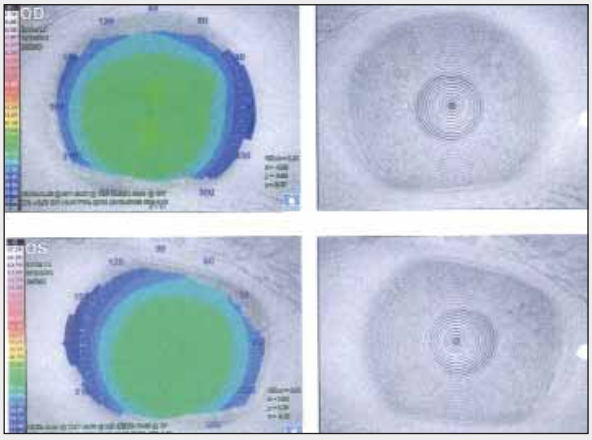

Figure 1. Preoperative topography shows a normal cornea in both eyes.

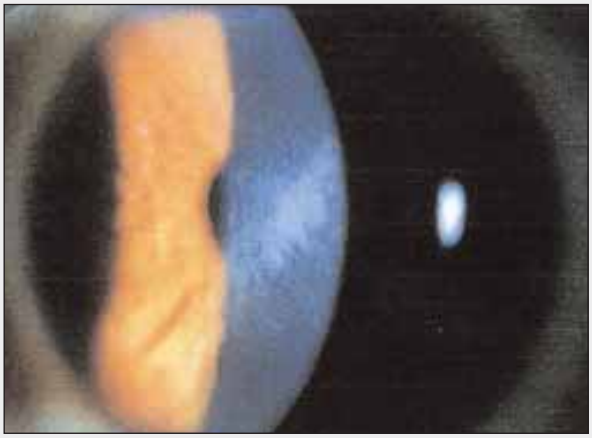

Figure 2. The eye exhibits grade +3 haze after PRK.

Figure 3. Haze or scarring is producing irregular mires of the topographic rings.

CASE PRESENTATION (CONTINUED)

He returns 7 months later with +3 haze in his right eye and +2 haze in his left eye (Figures 2 and 3). His UCVA is 20/50 OD and 20/25 OS. He reports that he ceased using the steroid after his 1-month visit and never really used the vitamin C. He is immediately placed on topical Pred Forte 1% (Allergan, Inc.) every 2 hours and topical Restasis 0.05% (Allergan, Inc.) twice daily, because lissamine green staining is consistent with dry eye disease.

During the next 6 months, the patient's vision improves to a UCVA of 20/50 OD and 20/15 OS. An examination shows trace haze in his left eye and visually significant haze of +1 to +2 in his right eye (Figure 4). His manifest refraction has been stable at -1.50 D OD and -0.25 D OS for the past 5 months. The patient requests surgical intervention to improve the vision of his right eye.

What are your current regimen and practice patterns for PRK and the postoperative treatment of haze, and how would you treat this patient?

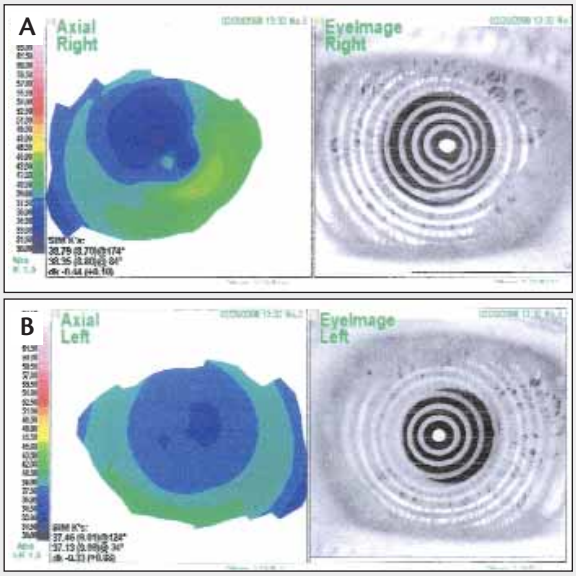

Figure 4. The persistent irregular scarring of the right eye despite treatment is represented topographically (A). The haze and scar tissue after treatment that were seen earlier in the patient's left eye during the postoperative period have resolved (B).

ANTHONY KUO, MD, AND TERRY KIM, MD

This patient has developed visually significant late postoperative haze after PRK. Given that aggressive topical anti-inflammatory therapy has failed to resolve the haze in his right eye, we would recommend surgical debridement (with a blade and/or excimer laser) of the scar tissue in the patient's right eye with an intraoperative application of 0.02% mitomycin C (MMC) to the exposed bed for 2 minutes to prevent recurrent haze. Although one could attempt to treat the -1.50 D of myopic regression concurrently if one used an excimer laser for the debridement, we would not recommend doing so, because the scar tissue might interfere with an accurate assessment of the true refractive error. Once the scar has been eliminated and the cornea has healed, further refractive surgery may be necessary to achieve the desired UCVA.

In patients undergoing a relatively high myopic correction with PRK (greater than -6.00 D, as in this case) for which the anticipated depth of ablation will be more than 70 µm, we advocate applying prophylactic MMC 0.02% intraoperatively for 15 to 30 seconds to prevent the development of corneal haze.[1] After the excimer laser ablation, we soak a sponge (light shield) with MMC 0.02%, place the light shield on the central cornea, and then copiously irrigate the surface with a bottle of chilled balanced salt solution. After every surface ablation procedure (regardless of the depth of the ablation), we place frozen popsicles of balanced salt solution on the corneal stroma for 1 minute to avoid activating the keratocytes.[2] The prevention of corneal haze after PRK continues postoperatively through the limitation of inflammation and the modulation of corneal wound healing. Specifically, we instruct patients to apply topical prednisolone acetate 1% at least four times a day during the early postoperative period and taper the application over the course of 3 to 4 months based on the eye's clinical appearance. This regimen likely would have prevented the development of visually significant corneal haze that is evident in this case.

RONALD R. KRUEGER, MD

Rather than a decenterered ablation, it is the postoperative development of haze that has led to the irregular topographic pattern evident as irregular photokeratoscopic rings and an asymmetric pattern of haze upon a slit-lamp examination of the patient's right eye. I would perform phototherapeutic keratectomy (PTK) after first scraping the cornea with a Beaver blade to remove the elevated area of haze. PTK with an excimer laser and frequently wiping a thin layer of methylcellulose across the treated surface should smoothly remove

the residual haze. The topical application of MMC 0.02% for 2 minutes after the treatment would give the best chance of preventing the haze from recurring.

> "I have not observed any toxicity related to MMC during my 11-year experience with the agent."
> —Parag A. Majmudar, MD

In our report on PRK in both eyes of a -8.00 D myope, my colleagues and I demonstrated that the prophylactic use of MMC is more effective than the use of this antifibrotic agent for the retreatment of haze.[3] I therefore think it would have been better if this patient had received MMC primarily after his original PRK procedure. Now, the myofibroblasts have been activated, and they are more likely to become reactivated—despite the use of topical MMC—after a retreatment with an excimer laser. At the Cleveland Clinic, my colleagues and I like to use a circular sponge soaked in topical MMC for all eyes treated with customized PRK that have more than -3.00 D of myopia or any eye requiring an ablation deeper than 70 µm. We apply the sponge for 30 seconds, remove it, wipe the bed with a Merocel sponge (Medtronic ENT, Jacksonville, FL), and then perform irrigation with topical balanced salt solution. The prophylactic use of MMC prevents the original activation of the myofibroblasts. We have found that the standard concentration of 0.02% is best, as low-dose MMC (0.002%) is sometimes ineffective at preventing haze. Although 30 seconds of exposure is adequate for prophylaxis, we recommend a full 2 minutes when retreating a cornea with haze in an effort to prevent the reactivation of the myofibroblasts. After PRK, we instruct patients to wear UV-protective sunglasses when outside in the sun for at least the first 6 months and to take oral vitamin C at 1,000 mg/day for the first 2 to 3 months after surgery.

PARAG A. MAJMUDAR, MD

When patients comply with postoperative instructions, the formation of haze after PRK is rare. That is fortunate, because the treatment of this condition generally proves more difficult than its primary prevention.

My preferred protocol for PRK in eyes with moderate-to-high myopia (> 5.00 D or more than 75 µm of ablation) is to administer prophylactic topical MMC 0.02% for 12 seconds at the time of the initial procedure. Since I began following this protocol in 1998, my incidence of visually significant haze has been zero. Initially, I applied MMC 0.02% for 2 minutes, but, in an effort to minimize any potential toxicity, I reduced the duration to 60 seconds. Later, after noticing that the efficacy had not been compromised, I decreased the duration of MMC exposure to 12 seconds. My experience with the 12-second application has mirrored my results with prophylactic MMC for 2 minutes (P. A. Majmudar, MD, unpublished data, 2008). I also recommend that patients take oral vitamin C, as suggested by Stojanovic et al,[4] especially if they spend a significant amount of time outdoors and have a higher-than-normal exposure to UV radiation.

Once haze has developed, there are two main options: (1) observation with a more frequent application of topical steroids and (2) the removal of the haze via a superficial keratectomy and MMC 0.02% for 2 minutes. The haze in this patient's left eye has resolved nicely with observation and steroids, but he requests surgical intervention for his right eye. My preferred protocol for the treatment of existing haze[5,6] involves removing it, either with excimer PTK or manual scraping, followed by the application of MMC 0.02% for 2 minutes. I would not consider additional excimer laser treatment at this time for the patient's current -1.50 D of myopia, because the majority of that refraction is pseudomyopia, induced by the scar, and will disappear following the haze's successful eradication. I would employ my standard post-PRK regimen (bandage contact lens, topical antibiotic and steroids). Re-epithelialization typically occurs within 3 to 5 days. I have not observed any toxicity related to MMC during my 11-year experience with the agent.

COL. SCOTT D. BARNES, MD

At Fort Bragg, North Carolina, more than 95% of our 30,000 laser vision correction procedures have been performed as surface ablation. Early on, my colleagues and I performed more LASIK, but PRK and LASEK have become our preferred procedures. Although some may consider PRK and LASEK to be essentially identical, we have found them to be quite different as far as the incidence of postoperative haze. When we analyzed our data, we found a rate of visually significant haze of less than 1:1,000 with PRK for corrections of under -4.00 D versus 4:100 for corrections of greater than -4.00 D. We debated using PRK with MMC versus alcohol-assisted LASEK and no MMC in high myopes. We elected to perform LASEK in these cases, and our rate of visually significant haze dropped from 4.0% to 0.7%.

We do not use prophylactic MMC with surface ablation unless the patient has a history of RK, penetrating

keratoplasty, or complicated LASIK. In those cases, we administer MMC 0.02% for 2 minutes. Interestingly, we have had to treat visually significant haze in at least six soldiers who have come to us after receiving PRK with prophylactic MMC at other US Army, US Navy, and civilian treatment centers.

> "Oftentimes, refractive errors fade or disappear completely along with reticular haze."
> —Col. Scott D. Barnes, MD

Currently, we use an Amoils brush/PRK for treatments of less than -4.00 D and alcohol-assisted LASEK for corrections greater than -4.00 D (and with hyperopia higher than +1.50 D and/or cylinder greater than 2.00 D). We replace the epithelium in all LASEK cases. Patients use moxifloxacin for 1 week, FML drops tapered over 4 months, preservative-free tetracaine every 2 hours (they receive only a 2-mL bottle and no refills), vitamin C tablets for 3 months, artificial tears as needed, and ibuprofen/Percocet (Endo Pharmaceuticals, Chadds Ford, PA) as needed. We do not routinely prescribe NSAIDs or cyclosporine. Patients wear the Acuvue Oasys bandage contact lens (Johnson & Johnson Vision Care, Inc., Jacksonville, FL) for 4 to 7 days until re-epithelialization is complete.

In this case, I would have preferred to perform LASEK initially. If the patient had presented for follow-up visits, it might have been possible to see the developing haze before he noticed a decrease in his vision and to substitute Pred Forte for the FML and initiate close monitoring. At this time, it is unlikely that the patient will respond to further medical treatment.

I would offer a corneal scraping of his right eye with MMC treatment (0.02% for 2 minutes). I would remove the epithelium with an Amoils brush and vigorously scrape the obvious haze with a No. 64 Beaver blade. Although a great deal of the fibrotic tissue could be removed, there might be residual irregularities that will remain despite several minutes' firm scraping. At this point, I would place a 6-mm corneal light shield in the liquid MMC and gently wring it out. I would place the shield on the cornea for 2 minutes and then perform irrigation with two bottles of chilled balanced salt solution. I would instill a drop of diclofenac and moxifloxacin on the cornea and place an Acuvue Oasys bandage contact lens. The patient's postoperative routine would be exactly the same as my usual for PRK/LASEK with at least 4 months of steroids and monthly follow-up exams.

I would not consider performing a refractive treatment until the haze was gone, because the cicatrizing effect of the haze could induce many diopters of myopia and/or astigmatism. Oftentimes, refractive errors fade or disappear completely along with reticular haze. Any true residual ametropia could be treated after refractive stability was established.

WILLIAM B. TRATTLER, MD

Surface ablation is a safe and simple procedure for correcting refractive error, but the development of postoperative corneal haze is a major risk. The incidence of this complication is much lower today than in the mid-1990s due to surgeons' better understanding of the chief risk factors for haze. They include deep ablations, exposure to UV light, ocular surface inflammation such as dry eye and meibomian gland dysfunction, and delays in epithelial healing.[7-9] Manufacturers have also recognized that they can design excimer lasers to reduce the risk of haze by creating a smoother ablation profile and minimizing the generation of heat.[10]

At my practice in South Florida, I take a number of steps to minimize the risk of haze. I find that applying MMC 0.02% for 12 to 30 seconds intraoperatively not only reduces the risk of haze, but it also minimizes the length of time my patients must use topical steroids postoperatively. I administer MMC 0.02% intraoperatively to eyes for which the depth of ablation is greater than 60 µm or when performing surface ablation as an enhancement procedure after other corneal surgery (eg, LASIK, corneal ring segments, RK, and penetrating keratoplasty). I will also use intraoperative MMC 0.02% for patients whose exposure to UV light is likely to be significant during the postoperative period, such as lifeguards and boating enthusiasts. Additional interventions I employ to reduce the risk of haze include treating underlying dry eye disease and meibomian gland dysfunction, recommending UV protection (sunglasses) to all patients, and ensuring a rapid epithelial healing process.

The main risk factors for haze in this case were the depth of the ablation and dry eyes. The incidence of haze is relatively low even without intraoperative MMC, but the patient appears to have stopped using topical steroids early. His exposure to UV light is unknown. An interesting question is whether the patient's noncompliance with oral vitamin C played a role in the development of haze. Although a study by Stojanovic et al provided some exciting data on the effectiveness of this supplement,[4] I have not found that vitamin C has decreased the incidence of haze.

The surgeon in this case seems to have managed the patient well overall after the discovery of haze. Treatment with Pred Forte and topical Restasis significantly decreased the degree of haze over 6 months. The patient's visual acuity is still reduced, however, and there is residual myopia in his right eye.

> "The main risk factors for haze in this case were the depth of the ablation and dry eyes."
> —William B. Trattler, MD

I would perform transepithelial PTK to eliminate the postoperative haze with intraoperative MMC 0.02% prophylaxis for a minimum of 30 seconds. I have found that shorter therapeutic applications of MMC 0.02% are insufficient. I would place an Acuvue Oasys bandage contact lens to facilitate epithelial healing and help reduce postoperative discomfort. Because this patient has dry eyes, I would place silicone punctal plugs at the conclusion of the procedure.

During the postoperative period, I would prescribe my usual 4- to 6-week tapering dose of topical steroids plus continue treating the patient's dry eye disease. Although topical steroids are important to preventing recurrent haze, the use of intraoperative MMC allows for shorter steroid treatment. I explain to patients that, although therapeutic laser treatment may eliminate haze, they will probably require an additional procedure to fine-tune their residual refractive error. ■

Section editor Karl G. Stonecipher, MD, is Director of Refractive Surgery at TLC in Greensboro, North Carolina. Stephen Coleman, MD, is Director of Coleman Vision in Albuquerque, New Mexico. They may be reached at (336) 288-8523; stonenc@aol.com.

Col. Scott D. Barnes, MD, is Chief, Warfighter Refractive Eye Surgery Clinic, Fort Bragg, North Carolina. He acknowledged no financial interest in the products or companies mentioned herein. Dr. Barnes may be reached at (910) 907-7921; scott.d.barnes@us.army.mil.

Terry Kim, MD, is Associate Professor of Ophthalmology, Cornea and Refractive Surgery, Duke University Eye Center, Durham, North Carolina. He acknowledged no financial interest in the products or companies mentioned herein. Dr. Kim may be reached at (919) 681-3568; terry.kim@duke.edu.

Ronald R. Krueger, MD, is Medical Director of the Department of Refractive Surgery, Cole Eye Institute, Cleveland Clinic Foundation, Cleveland. He has received travel support, consulting fees, and research funds from Alcon Laboratories, Inc. Dr. Krueger may be reached at (216) 444-8158; krueger@ccf.org.

Anthony Kuo, MD, is Assistant Professor of Ophthalmology, Cornea and Refractive Surgery, Duke University Eye Center, Durham, North Carolina. He acknowledged no financial interest in the products or companies mentioned herein. Dr. Kuo may be reached at (919) 681-3568; anthony.kuo@duke.edu.

Parag A. Majmudar, MD, is Associate Professor, Cornea Service, Rush University Medical Center, Chicago Cornea Consultants, Ltd. He is also a section editor for this column. He acknowledged no financial interest in the products or companies mentioned herein. Dr. Majmudar may be reached at (847) 882-5900; pamajmudar@chicagocornea.com.

William B. Trattler, MD, is Director of the Cornea Center for Excellence in Eye Care in Miami and is Volunteer Assistant Professor of Ophthalmology at Bascom Palmer Eye Institute in Miami. He has received research grants from, is a consultant to, and/or is on the speakers' board of Advanced Medical Optics, Inc.; Allergan, Inc.; Glaukos Corp.; Inspire Pharmaceuticals, Inc.; Ista Pharmaceuticals, Inc.; Lenstec, Inc.; Sirion Therapeutics; and Vistakon Pharmaceuticals LLC. Dr. Trattler may be reached at (305) 598-2020; wtrattler@earthlink.net.

1. Carones F, Vigo L, Scandola E, Vacchini L. Evaluation of the prophylactic use of mitomycin-C to inhibit haze formation after photorefractive keratectomy. *J Cataract Refract Surg.* 2002;28:2088-2095.
2. Kitazawa Y, Maekawa E, Sasaki S, et al. Cooling effect on excimer photorefractive keratectomy. *J Cataract Refract Surg.* 1999;25:1349-1355.
3. Netto MV, Chalita MR, Krueger RR. Corneal haze following PRK with mitomycin C as a retreatment versus prophylactic use in the contralateral eye. *J Refract Surg.* 2007;23:96-97.
4. Stojanovic A, Ringvold A, Nitter T. Ascorbate prophylaxis for corneal haze after photorefractive keratectomy. *J Refract Surg.* 2003;19:338-343.
5. Majmudar PA, Forstot SL, Nirankari VS, et al. Topical mitomycin-C for subepithelial fibrosis after refractive corneal surgery. *Ophthalmology.* 2000;107(1):89-94.
6. Majmudar PA. The role of mitomycin-C in corneal refractive surgery. *Techniques in Ophthalmology.* June 2004;2(2):43-49.
7. Stojanovic A, Nitter TA. Correlation between ultraviolet radiation level and the incidence of late-onset corneal haze after photorefractive keratectomy. *J Cataract Refract Surg.* 2001;27:404-410.
8. Yee R. Meibomian gland dysfunction and refractive surgery. Paper presented at: The Seventh International Congress of Surface Ablation and Sub Bowman's Keratomileusis; April 26, 2008; Weston, FL.
9. Trattler W, Barnes S. Current trends in advanced surface ablation. *Curr Opin Ophthalmol.* 19:330-334.
10. Vinciguerra P, Azzolini M, Airaghi P, et al. Effect of decreasing surface and interface irregularities after photorefractive keratectomy and laser in situ keratomileusis on optical and functional outcomes. *J Refract Surg.* 1998;14(2 suppl):S199-S203.